

# Lateral third clavicle fracture with concomitant glenoid and acromian fractures: A rare injury pattern.

KC KM, GC R, Acharya S

Mercy City Hospital

Butwal, Rupendehi, Nepal.

## Corresponding Author

Mercy City Hospital

Butwal, Rupendehi, Nepal.

E-mail: drkapil2007.kmhc@gmail.com

## Citation

KC KM, GC R, Acharya S. Lateral third clavicle fracture with concomitant glenoid and acromian fractures: a rare injury pattern. *Nepal Orthopaedic Association Journal (NOAJ)* 2021;7(2):21-23..

## ABSTRACT

Combination of lateral third clavicle fracture (Neer type II), Ideberg type III glenoid fracture and acromian fracture is very rare fracture pattern. High index of suspicion after careful clinical and radiological examination is mandatory; otherwise glenoid fractures can be missed and functional outcomes will significantly be altered. This type of fracture pattern requires timely diagnosis, proper planning and proper use of implants. We report a 39 years old female patient with Neer type II lateral third clavicle fracture with concomitant Ideberg type III glenoid fracture and undisplaced acromian fracture visualized only in CT scan which was diagnosed and managed successfully with single incision on lateral aspect of clavicle and fixed with trans-acromian Kirschner wire for clavicle fracture and cannulated screw for glenoid fracture after indirect reduction of fracture.

## KEY WORDS

*Acromian; glenoid; K wire; lateral third clavicle fractures*

## INTRODUCTION

Lateral third of clavicle fractures account for 15% of all clavicle fractures.<sup>1</sup> Unstable fractures are generally managed by surgical treatment that includes open or closed reduction and fixation with K wires, locking plating, hook plating and suture fixation.<sup>2,3</sup> Different types of glenohumeral injuries like superior labrum anterior-posterior (SLAP) lesion, injury to pulley complex and rotator cuff tears have been found to be associated with acute lateral third clavicle fractures of acromioclavicular joint dislocation.<sup>4,5,6</sup> In the other hand, scapular fractures extending into the glenoid articular surface are a relatively rare and challenging clinical problem.<sup>7,8</sup> However, combination of lateral third clavicle fracture, type III ideberg glenoid fracture and acromian fracture is fairly uncommon fracture pattern. Minimally displaced glenoid fracture and

acromian fracture may not be identified at first time unless careful clinical and radiological examination is performed. The aim of this study is to notify this uncommon fracture pattern as well to plan the logical surgical approach to get optimal functional outcomes.

## CASE REPORT

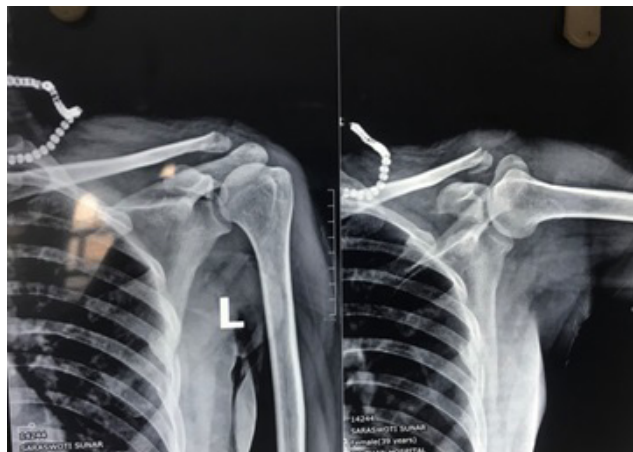A thirty nine years old female patient sustained injury on left shoulder region after road traffic accident. She was complaining severe pain, swelling and inability to move the left shoulder. On examination, there was huge swelling, tenderness on distal end of clavicle. Range of motion was grossly restricted because of pain and swelling. Distal neurovascular status was normal. She was advised for

X-ray left shoulder antero-posterior (AP) and lateral view. It was noticed lateral end of clavicle fracture (Neer type II) and fracture of the glenoid cavity. In order to assess the fracture pattern and plan the surgery, CT scan of left shoulder including 3D reconstruction was advised. CT scan showed the displaced lateral end of clavicle fracture (Neer type II), Ideberg type III glenoid fracture and un-displaced fracture of acromian. She was planned for fracture fixation of both fracture with single incision in the operation theatre. After positioning, painting and draping, incision was made on lateral aspect of clavicle. Superficial and deep fascia was incised followed by stripping of deltoid muscle from anterior aspect of lateral end of clavicle. Since there was un-displaced fracture of acromian as well, possibility of hook plated fixation was ruled out rather both fractures were fixed with two K wires through acromian to clavicle. Soft tissue dissection was further continued until coracoid process was easily felt. Now glenoid fracture was reduced indirectly by manipulating coracoid process. After the confirmation of reduction with fluoroscopy image, it was temporarily fixed with K wire. Guide wire was then passed from the base of coracoid process perpendicularly to lower end of glenoid neck under fluoroscopy guidance. Appropriate length screw was placed in the same direction to fix the glenoid. Wound was dressed 48 hours after surgery. Pendulum exercise of arm was started after first dressing. Passive shoulder mobilization exercise was started 2 weeks after surgery and active shoulder mobilization exercise was started after 6 weeks of surgery. K wires were planned to be removed at 2 months post-operative period. .

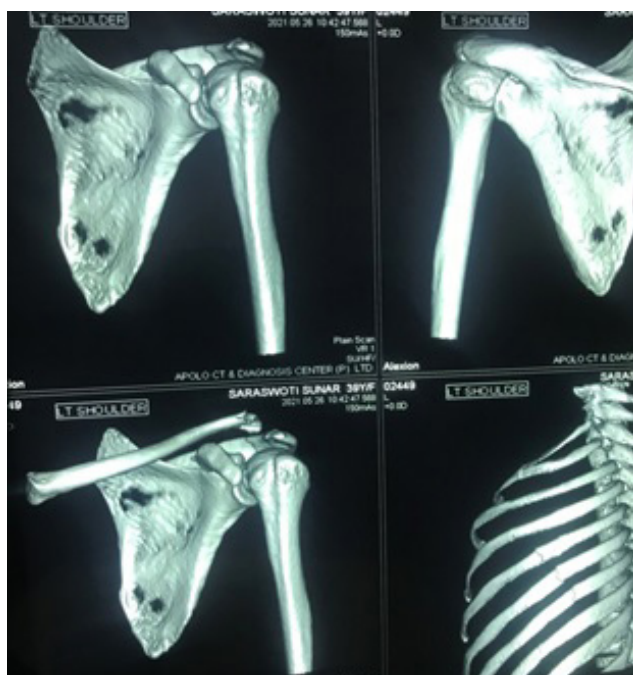
## DISCUSSION

Distal third clavicle fractures represent 10 to 30% of whole clavicle fractures and most of them can be managed successfully with conservative technique. However, displaced unstable lateral third clavicle fractures require surgical treatment with regard to patient's age and functional demands.<sup>9</sup> Beirer et al<sup>10</sup> mentioned simultaneous glenohumeral injuries in 13 out of 28 (46.4%) patients which initially was assumed as isolated lateral third clavicle fractures. Glenohumeral injuries included SLAP lesion, suspensory pulley complex and rotator cuff tear. Eight out of 28 patients (28.6%) of these concomitant injuries ultimately required operative intervention which, if not detected at first instance, might have hampered the functional outcomes.

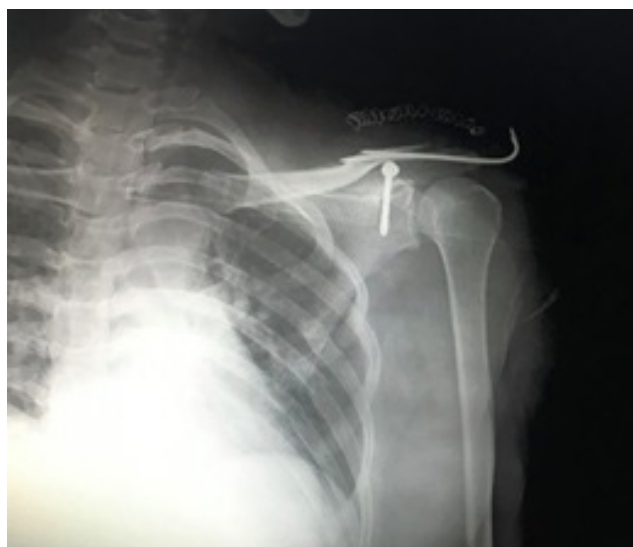Intra-articular glenoid fractures are rare injuries, even Ideberg type III fractures present a more rare and difficult scenario and combination of lateral third clavicle fracture (Neer type II), Ideberg type glenoid fracture and acromian fracture is very rare pattern. High index of suspicion after careful clinical and radiological examination is mandatory; otherwise functional outcomes will significantly be altered. This type of combined fracture pattern can be treated surgically with single incision on lateral third of clavicle



**Figure 1.** Preoperative radiograph showing lateral third clavicle fracture and glenoid fracture



**Figure 2.** 3D CT scan showing lateral third clavicle fracture, glenoid fracture and acromian fracture



**Figure 3.** Postoperative radiograph showing fixation clavicle by K wires and glenoid fracture fixation with cannulated screw.

region with open reduction and fixation of fractures with either trans-acromian K wires or lateral end multiple holes locking plate, however hook plating option is ruled out because of acromian fractures. Type III Ideberg glenoid fracture can be fixed by cannulated screw with indirect reduction. However, this type of fracture pattern does require timely diagnosis, proper planning and proper use of implants. That's why this case needed to be reported in literature.

There are certain neurovascular considerations that must be addressed specifically with Ideberg type III fractures: Most notably, the suprascapular nerve is at risk with superior screw placement. As the main branch passes through the suprascapular notch, it sends off motor fibers

to the supraspinatus as well as a sensory branch to the glenohumeral joint. It then traverses the spinoglenoid notch, hugging the posterior glenoid neck as it sends innervation to the infraspinatus.<sup>11,12</sup> Although care must always be taken to not penetrate the articular surface, a screw position that wanders too far medially toward the glenoid neck or posteriorly toward the spinoglenoid notch dramatically increases the risk of suprascapular nerve injury.

#### ACKNOWLEDGEMENTS

I would like to acknowledge the patient who participated in this study.

#### REFERENCES

1. Postacchini F, Gumina S, De Santis P, Albo F. Epidemiology of clavicle fractures. *J Shoulder Elbow Surg.* 2002;11(5):452–6.
2. Neer CS 2nd. Fractures of the distal third of the clavicle. *Clin Orthop Relat Res.* 1968;58:43–50.
3. Helfen T, Siebenbürger G, Haasters F, Böcker W, Ockert B. Concomitant glenohumeral injuries in Neer type II distal clavicle fractures. *BMC musculoskeletal disorders.* 2018 Dec;19(1):1-6.
4. Biz C, Berizzi A, Cappellari A, Crimi A, Tamburin S, Iacobellis C. The treatment of acute Rockwood type III acromio-clavicular joint dislocations by two different surgical techniques. *Acta Biomed.* 2015;86(3):251–9.
5. Tischer T, Salzmann GM, El-Azab H, Vogt S, Imhoff AB. Incidence of associated injuries with acute acromioclavicular joint dislocations types III through V. *Am J Sports Med.* 2009;37(1):136–9.
6. Snyder SJ, Karzel RP, Del Pizzo W, Ferkel RD, Friedman MJ. SLAP lesions of the shoulder. *Arthroscopy.* 1990;6(4):274–9.
7. Ideberg R, Grevsten S, Larsson S. Epidemiology of scapular fractures. Incidence and classification of 338 fractures. *Acta Orthop* 1995;66:395-397.
8. Tao MA, Garrigues GE. Arthroscopic-assisted fixation of Ideberg type III glenoid fractures. *Arthroscopy techniques.* 2015 Apr 1;4(2):e119-25.
9. Helfen T, Siebenbürger G, Haasters F, Böcker W, Ockert B. Concomitant glenohumeral injuries in Neer type II distal clavicle fractures. *BMC musculoskeletal disorders.* 2018 Dec;19(1):1-6.
10. Beirer M, Zyskowski M, Cronlein M, Pforringer D, Schmitt-Sody M, Sandmann G, Huber-Wagner S, Biberthaler P, Kirchhoff C. Concomitant intra-articular glenohumeral injuries in displaced fractures of the lateral clavicle. *Knee Surg Sports Traumatol Arthrosc.* 2015;5(10):3237–41.
11. Lafosse L, Tomasi A. Technique for endoscopic release of suprascapular nerve entrapment at the suprascapular notch. *Tech Shoulder Elbow Surg* 2006;7:1-6.
12. Bhatia S, Chalmers PN, Yanke AB, Romeo AA, Verma NN. Arthroscopic suprascapular nerve decompression: Transarticular and subacromial approach. *Arthrosc Tech* 2012;1:187-192.