

Diffusion Tensor Tractography in Patient with Cervical Spondylosis and Correlation with Clinical Findings

Mahesh Gautam¹, Robinson Shrestha¹, Nawaraj Ranabhat², Prakash Kafle³, Bijay Shrestha¹, Ashish Mohan Bhattarai¹

¹Department of Radiology, Nobel Medical College Teaching Hospital, Biratnagar, Nepal

²Department of Radiology, Patan Academy of Health Sciences, Lalitpur, Nepal

³Department of Neurosurgery, Nobel Institute of Neurosciences, Nobel Medical College Teaching Hospital, Biratnagar, Nepal

Received: June 21, 2023

Accepted: January 1, 2024

Published: April 26, 2024

Cite this paper:

Gautam M, Shrestha R, Ranabhat N, Kafle P, Shrestha B, Bhattarai AM. Diffusion Tensor Tractography in Patient with Cervical Spondylosis and Correlation with Clinical Findings. *Nepalese Journal of Radiology* 2024;14(1):3-9. <http://doi.org/10.3126/njr.v14i1.64623>

ABSTRACT

Introduction: Diffusion tensor imaging is a non-invasive advanced method that provides information on white matter microstructural integrity. Fractional anisotropy and apparent diffusion coefficient have been used to quantify the degree of axonal damage and demyelination. The study aims to assess the role of diffusion tensor parameters in detecting early myelopathic changes and correlate them with clinical findings.


Methods: This cross-sectional prospective study including 60 patients with clinical history of cervical myelopathy was carried out at the Department of Radiology from June 2021 to July 2022. Nurick score was used to assess the severity clinically and diffusion tensor images of the cervical spine were obtained using 3 Tesla MRI. These diffusion tensor values at the level of maximum stenosis were compared with those of the non-stenotic level. A correlation between the diffusion tensor parameters and clinical Nurick score was done.

Results: The fractional anisotropy values were significantly lower (0.51 ± 0.14 vs 0.76 ± 0.47) and apparent diffusion coefficient values were significantly higher (1.20 ± 0.20 vs 1.04 ± 0.12) at the level of maximum stenosis compared with non-stenotic levels. There was a moderate positive and strong negative correlation between the apparent diffusion coefficient and fractional anisotropy values with the Nurick score.

Conclusions: A significant reduction in the fractional anisotropy and an increase in apparent diffusion coefficient values at the level of stenosis was observed in individuals without a high T2 signal within the cord. Thus, these parameters might have a potential role in the early diagnosis of cervical spondylotic myelopathy.

Keywords: Anisotropy; Diffusion Tensor Imaging; Radiology; White Matter

Correspondence to: Dr. Mahesh Gautam
Department of Radiology
Nobel Medical College Teaching Hospital
Biratnagar, Nepal
Email: mahes.gautam07@gmail.com

 Licensed under CC BY 4.0 International License which permits use, distribution and reproduction in any medium, provided the original work is properly cited

INTRODUCTION

Cervical spondylosis is a common age-related degenerative disease affecting the intervertebral discs and surrounding vertebral bodies giving a wide range of symptoms from mild neck pain to severe neurological deficits. The gold standard for diagnosis is conventional magnetic resonance imaging (MRI) but it may not detect the microstructural changes in the early stage of the disease process. Diffusion tensor imaging (DTI) measures the random diffusion of water molecules in tissue and is used to assess the microstructural integrity of white matter. It can detect subtle alterations in the spinal cord not visible on conventional MRI.^{1,2,3}

DTI parameters mainly fractional anisotropy (FA) and apparent diffusion coefficient (ADC) are used to quantify the degree of axonal damage and demyelination. FA assesses water diffusion anisotropy, reflecting white matter tract integrity, while ADC indicates tissue damage based on the average magnitude of water molecule movement. A meta-analysis of DTI studies revealed a significant decrease in FA values within the white matter spinal cord in patients with cervical spondylosis compared to healthy controls. In another study, a significant increase in ADC values was seen in the spinal cord in patients with cervical spondylosis indicating the presence of neuronal loss and gliosis in this particular area.^{4,5,6,7}

Despite its potential advantages, DTI faces technical challenges like image distortion, susceptibility, and motion artifacts. Moreover, the lack of standardized protocols makes result comparison difficult across studies.⁸

Therefore, this study aims to assess the role of DTI parameters in detecting early myelopathic changes and correlate with the clinical findings.

METHODS

This cross-sectional study was conducted at the Department of Radiology, Nobel Medical College for one year, starting from June 2021 to July 2022. Before commencing the study, ethical approval was obtained from the institutional review committee (IRC) under reference number 482/2021. The

patients were selected using the convenient sampling technique and informed consent was taken from all the enrolled patients after a detailed explanation of the study. All patients over 18 years of age irrespective of sex with a clinical diagnosis of cervical spondylotic myelopathy and referred to the radiology department for MRI were included in this study. Patients with a previous history of spine surgery, spinal trauma, known malignancy of the spine, and congenital disease affecting the spine were excluded from the study. Similarly, patients having contraindications for MRI were also excluded.

All the patients who presented with the symptoms of neck pain radiating to the arm, tingling sensation or paresthesia, and motor weakness were evaluated clinically in the neurology and/or neurosurgery department and then subjected to MRI in the radiology department. The severity of the symptoms was evaluated with Nurick's score. This score consists of five definitive descriptions of the condition and the score ranges from 0 to 5 (where 0 indicates symptoms of root involvement without evidence of spinal cord disease, and 5 represents a bedridden or chair-bound status)

MRI was performed in a 3-Tesla MRI system (Skyra, Siemens) using a standard cervical coil. The sequences used were T1-weighted (T1WI) sagittal, T2-weighted (T2WI) axial and sagittal, and DTI images. For DTI the parameters used were: Diffusion Mode: Multidirectional Diffusion weighting (MDDW) Echoplanar imaging sequence; Diffusion direction: 20; TR/TE: 3700/92; Field of view: 220 mm; Slice thickness: 4mm, Slice gap: 0 mm; diffusion weighting coefficient (b) value 0, 1000 s/mm²; Number of acquisition; 3; Voxel size: 1.7×1.7×4.0 mm and bandwidth 1502 Hz/Px. No contrast was used in this study. Then acquired images were transferred to the workstation syngo provided by the manufacturer. The axial and sagittal T1-weighted (T1WI) and T2-weighted (T2WI) sequences of the cervical cord were evaluated to see compressive myelopathy changes. The presence of a high signal in the cord on T2WI images was also excluded from the study. DTI was processed

using syngo MR neuro 3D software provided by the manufacturer. b0 images were obtained at first to remove any voxel related to noise. Then ADC and FA maps were obtained automatically at b700.

The normal fibers oriented in the craniocaudal direction in the cervical cord were coded in blue color and the change in the blue color was assessed for FA. (Figure 1) The calculation of FA and ADC values in tensor images was performed using the region of interest (ROI) method by drawing a circular or ellipsoidal shape around the desired area. These values were obtained at all the levels of the cervical disc i.e., from C2-C3 to C7-T1 level. (Figure 2) In a study conducted by Facon et al, it was found that there was no significant difference in DTI parameters among the control healthy group and healthy areas of the cord in patients with cord compression. Based on that evidence the non-stenotic level mainly the upper cervical level i.e., C2-C3 was considered as the control group.⁹




Figure 1: Colour-coded fractional anisotropy image of cervical spine

ID	FA		ADC		TraceW		b0	
	Mean	SDev	Mean	SDev	Mean	SDev	Mean	SDev
	Size / Min / Max		Size / Min / Max		Size / Min / Max		Size / Min / Max	
1	761.8	110.2	1107.4	430.3	201.1	34.6	384.2	27.0
	10 / 593 / 912		10 / 699 / 2292		10 / 111 / 241		10 / 352 / 441	
2	774.5	87.3	1187.6	438.5	184.0	37.2	365.8	12.7
	10 / 656 / 960		10 / 710 / 2390		10 / 94 / 234		10 / 353 / 396	
3	752.4	91.1	1198.8	374.3	166.4	36.5	332.6	22.7
	14 / 535 / 927		14 / 794 / 2207		14 / 89 / 211		14 / 294 / 373	
4	675.3	111.4	1069.0	144.5	174.3	14.7	330.3	17.5
	12 / 433 / 825		12 / 819 / 1394		12 / 144 / 196		12 / 310 / 359	
5	761.2	126.2	1222.0	173.9	155.2	10.6	323.1	23.3
	9 / 580 / 1000		9 / 970 / 1601		9 / 140 / 173		9 / 293 / 369	
6	697.5	107.7	1256.4	146.1	156.7	11.0	333.2	22.8
	13 / 510 / 858		13 / 1052 / 1510		13 / 139 / 174		13 / 291 / 373	

Figure 2: Table showing FA and ADC values at cervical disc levels

Image interpretation was done by two radiologists conjointly without any discrepancies. To diagnose myelopathy in DTI images, the images were evaluated for the presence of an alteration in the blue color of the fibers and a combination of decreased FA and increased ADC value at the level of the affected disc as compared with the normal level. The cut-off value of 0.7 for FA was used to assess the myelopathy in DTI as described in the study by Ellingson et al.¹⁰

Data were analyzed using the Statistical Package for the Social Science (SPSS) version 16.0. To describe the descriptive statistics; mean and standard deviation was used for the continuous variable and frequency and percentage for the categorical variable. Spearman rank-order correlation coefficient (Spearman Rho) was calculated by plotting the scatter diagram and the correlation between the Nurick score and DTI parameters at the level of maximum stenosis was assessed. A paired t-test was used to compare the FA and ADC values at the level of the maximum stenosis to those of the non-stenotic level. A p-value less than 0.05 was considered significant.

RESULTS

A total of 60 patients were included in this study. The mean age was 49 years \pm 10.76 years. Among them, 61.7% were male and 38.3% were female. The most affected disc was the C5-C6 disc in 46.67% followed by the C4-C5 disc in 28.34%, C3-C4 in 16.72%, and C6-C7 in 8.34% of cases.

The majority of the patients had a Nurick score of

2 (41.67%), followed by a score of 1 in 26.67%, a score of 3 in 18.33%, a score of 4 in 10%, and a score of 5 in 3.34%. The comparison between FA and ADC values at stenotic and non-stenotic levels is shown in Table 1. There was a significant difference between the mean values of FA and ADC at the stenotic level compared with the non-stenotic level (p-value 0.001). The correlation between Nurick score with FA and ADC value

is shown in Figures 3 and 4 respectively. There was a weak positive correlation (Spearman’s rho value of 0.298 and a p-value of < 0.001) between the Nurick score and the mean ADC value at the stenotic level. There was a strong negative correlation (Spearman’s rho value of -0.800 and a p-value of <0.001) between the FA value at the stenotic level and the Nurick clinical score.

Table 1: Comparison of FA and ADC values at stenotic and non-stenotic levels

	Stenotic level	Non-stenotic level	Mean difference	p-value
Fractional anisotropy	0.51 ± 0.14	0.76 ± 0.47	0.25	0.001
ADC value	1.20 ± 0.20	1.04 ± 0.12	0.16	0.001

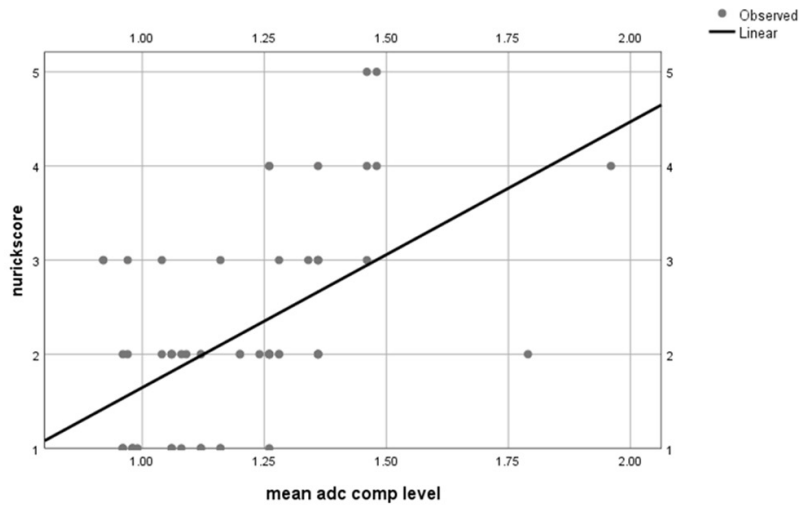


Figure 3: Comparison between ADC value at stenotic level with Nurick score

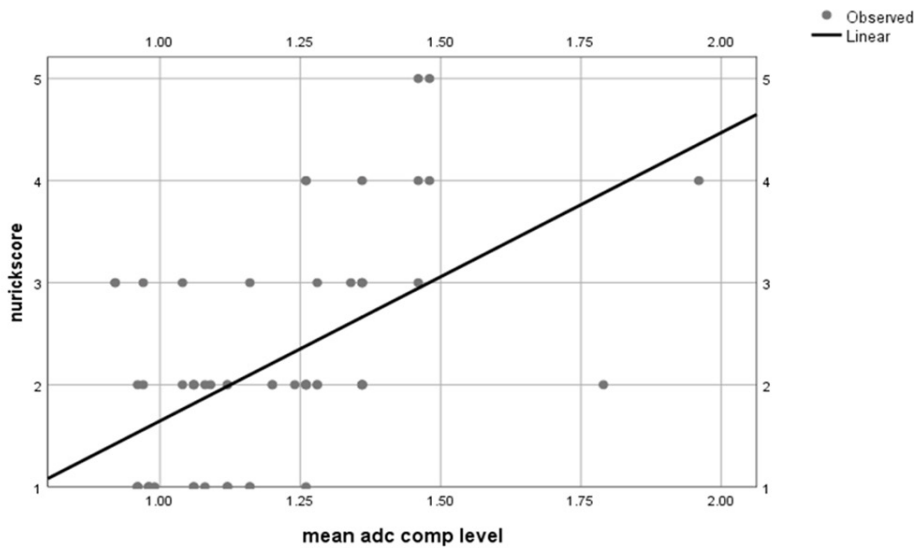


Figure 4: Correlation between FA value at stenotic level with Nurick score

DISCUSSION

Cervical spondylosis is a degenerative disease affecting the cervical spine that can lead to compression of the cord and/or nerve roots, resulting in various neurological symptoms. Conventional MRI is the main imaging modality used to diagnose and evaluate cervical spondylosis, but its sensitivity is limited in detecting early-stage changes and may not reflect the functional status of the spinal cord. DTI is an evolving MRI technique that has shown promising results in assessing the microstructural integrity of the cord. This study aimed to explore the utility of DTI in conjunction with FA and ADC to assess microstructural changes in the cervical spinal cord of patients diagnosed with cervical spondylosis, particularly those without evident high signal in T2-weighted images in conventional MRI and correlate with the clinical symptoms.^{11,12,13}

The outcome of the decompressive surgery for cervical spondylotic myelopathy (CSM) depends upon the time of the surgery. Previous studies showed better clinical results in those patients who had gone through surgical intervention in the earlier stage. Therefore the radiological diagnosis of the CSM is crucial. Studies have shown that a high signal in T2WI occurs in the later stage of the CSM.^{14,15,16}

Our results showed significantly lower FA values at the level of maximum stenosis of the cord compared to non-stenotic levels. (Figure 6) The mean FA values at this study's non-stenotic and stenotic levels were 0.76 ± 0.47 and 0.51 ± 0.14 respectively. This is similar to the study by Facon et al. where the FA value at the non-stenotic level was 0.74 and at the stenotic level was 0.6 ± 0.08 . Similarly another study by Uda et al. also shows similar results. The mean ADC values in stenotic and non-stenotic segments of the spinal cord were 1.20 and 1.04 mm^2/s respectively. The ADC values at the level of stenosis were higher than non-stenotic levels. The results of this study are similar to the meta-analysis encompassing fourteen trials, 479 CSM patients, and 278 controls where FA was significantly decreased and ADC was significantly raised in most of the compressed levels, showing

a significant difference between FA and ADC in CSM subjects compared to healthy subjects. Our study also supports Budzik et al. study, which found diminished FA value at the level of maximum compression of the cord and was more sensitive in detecting stenotic levels compared to conventional T2W imaging.^{6,9,17,18}

The correlation between the clinical score and FA and ADC values at the level of compression is varied. Similar to the study by Jones et al. this study also showed a strong negative correlation between the Nurick score and FA value at the stenotic level. Only a limited study shows a positive correlation. The study by Budzik et al. showed a positive correlation between clinical impairment and DTI parameters. In this study, a moderate positive correlation was observed between the Nurick score and ADC value at the stenotic level which was consistent with the study by Demir et al. This difference could be explained as some patients have a varying degree of canal stenosis at multiple levels, as these FA and ADC values are measured at the most compressive level which may not necessarily correspond to the segment causing their symptoms. Secondly, the difference in results may be because of the use of different clinical scores for the assessment of myelopathy. The study by Budzik et al. used the Japanese orthopedic association score whereas Nurick's score was used for the clinical assessment of cervical myelopathy in this study. This suggests the importance of the use of precise and detailed clinical scores in assessment of the cervical myelopathy.^{16,18,19}

The main advantage of this study is that the diffusion parameter values were obtained at all the cervical levels. The upper cervical region is relatively stable and FA values at the C2-C3 level are used as a reference to reduce the variability of FA values due to different ages and sex. However, there are some limitations to the use of DTI with FA in the evaluation of cervical spondylosis. One limitation is the relatively small sample size, which may limit the generalizability of the findings. Another limitation is the variability in the methodology of DTI analysis, such as

the choice of ROI, diffusion model, and post-processing methods. Standardization of these methods helps to improve the reproducibility and reliability of DTI with FA in the evaluation of cervical spondylosis.

Although this study in concordance with previous studies suggests that DTI with FA is a promising tool for assessing the microstructural integrity of the cord in cervical spondylosis. However, further studies with larger sample sizes and longitudinal follow-ups are required to observe the development of high T2 signal in the spinal cord in the course of the disease as the disease progresses in cases where FA values are low to confirm the potential clinical applications of DTI with FA in patients with cervical spondylosis and tailor treatment strategies accordingly.

CONCLUSION

DTI has the potential to improve the understanding of cervical myelopathy and guide the development of new and early therapeutic interventions. These parameters help in the early detection of the myelopathic changes before they show obvious T2 high signal used currently for diagnosis of myelopathy. However, further studies are needed to establish its reliability and validity in this context.

CONFLICT OF INTEREST

None

SOURCES OF FUNDING

None

REFERENCES

1. Lv Y, Tian W, Chen D, Liu Y, Wang L, Duan F. The prevalence and associated factors of symptomatic cervical Spondylosis in Chinese adults: a community-based cross-sectional study. *BMC Musculoskelet Disord* 2018;19:1-2. <https://doi.org/10.1186/s12891-018-2234-0>
2. Zhang C, Das SK, Yang DJ, Yang HF. Application of magnetic resonance imaging in cervical spondylotic myelopathy. *World J Radiol* 2014;6(10):826-32. <https://doi.org/10.4329/wjr.v6.i10.826>
3. Shabani S, Kaushal M, Budde MD, Wang MC, Kurpad SN. Diffusion tensor imaging in cervical spondylotic myelopathy: a review. *J Neurosurg Spine* 2020;33(1):65-72. <https://doi.org/10.3171/2019.12.spine191158>
4. Murphy RK, Sun P, Han RH et al. Fractional anisotropy to quantify cervical spondylotic myelopathy severity. *J Neurosurg Sci* 2018;62(4):406-12. <https://doi.org/10.23736/S0390-5616.16.03678-X>
5. Sato T, Horikoshi T, Watanabe A et al. Evaluation of cervical myelopathy using apparent diffusion coefficient measured by diffusion-weighted imaging. *AJNR Am J Neuroradiol* 2012;33(2):388-92. <https://doi.org/10.3174/ajnr.A2756>
6. Guan X, Fan G, Wu X et al. Diffusion tensor imaging studies of cervical spondylotic myelopathy: a systemic review and meta-analysis. *PloS one* 2015;10(2):e0117707. <https://doi.org/10.1371%2Fjournal.pone.0117707>
7. Rindler RS, Chokshi FH, Malcolm JG et al. Spinal diffusion tensor imaging in evaluation of preoperative and postoperative severity of cervical spondylotic myelopathy: systematic review of literature. *World Neurosurg* 2017;99:150-8. <https://doi.org/10.1016/j.wneu.2016.11.141>
8. Lee E, Lee JW, Bae YJ, Kim HJ, Kang Y, Ahn JM. Reliability of pre-operative diffusion tensor imaging parameter measurements of the cervical spine in patients with cervical spondylotic myelopathy. *Sci Rep* 2020;10(1):17410. <https://doi.org/10.1038%2Fs41598-020-74624-6>
9. Facon D, Ozanne A, Fillard P, Lepeintre JF, Tournoux-Facon C, Ducreux D. MR diffusion tensor imaging and fiber tracking in spinal cord compression. *AJNR Am J Neuroradiol* 2005;26(6):1587-94. Available from:

- <https://www.ncbi.nlm.nih.gov/pmc/articles/PMC8149058/> [Accessed 15th December 2023]
10. Ellingson BM, Salamon N, Grinstead JW, Holly LT. Diffusion tensor imaging predicts functional impairment in mild-to-moderate cervical spondylotic myelopathy. *Spine J* 2014;14(11):2589-97. <https://doi.org/10.1016/j.spinee.2014.02.027>
 11. Tu C, Wang JH, Liao HB et al. The value of diffusion tensor imaging and fiber tractography in cervical spondylotic myelopathy. *Zhongguo Gu Shang* 2016;29(3):200-4. Available from: <https://europepmc.org/article/med/27149787> [Accessed 12th December 2023]
 12. Vedantam A, Jirjis MB, Schmit BD, Wang MC, Ulmer JL, Kurpad SN. Diffusion tensor imaging of the spinal cord: insights from animal and human studies. *Neurosurgery* 2014;74(1):1-8. <https://doi.org/10.1227/NEU.0000000000000171>
 13. Akshitha JR, Gopinath G, Divya M, Paarthipan N. The Role of Diffusion Tensor Tractography in Assessment of Spondylotic Myelopathy. *Cureus* 2022;14(6):e25778. <https://doi.org/10.7759/cureus.25778>
 14. Matz PG, Anderson PA, Holly LT et al. The natural history of cervical spondylotic myelopathy. *J Neurosurg Spine* 2009;11(2):104-11. <https://doi.org/10.3171/2009.1.SPINE08716>
 15. Yagi M, Ninomiya K, Kihara M, Horiuchi Y. Long-term surgical outcome and risk factors in patients with cervical myelopathy and a change in signal intensity of intramedullary spinal cord on Magnetic Resonance imaging. *J Neurosurg Spine* 2010;12(1):59-65. <https://doi.org/10.3171/2009.5.SPINE08940>
 16. Demir A, Ries M, Moonen CTW et al. Diffusion-weighted MR Imaging with Apparent Diffusion Coefficient and Apparent Diffusion Tensor Maps in Cervical Spondylotic Myelopathy. *Radiology* 2003;229(1):37-43. <https://doi.org/10.1148/radiol.2291020658>
 17. Uda T, Takami T, Tsuyuguchi N et al. Assessment of cervical spondylotic myelopathy using diffusion tensor magnetic resonance imaging parameter at 3.0tesla. *Spine (Phila Pa 1976)* 2013;38(5):407-14. <https://doi.org/10.1097/brs.0b013e31826f25a3>
 18. Budzik J-F, Balbi V, Le Thuc V, Duhamel A, Assaker R, Cotten A. Diffusion tensor imaging and fiber tracking in cervical spondylotic myelopathy. *Eur Radiol* 2011;21(2):426-33. <https://doi.org/10.1007/s00330-010-1927-z>
 19. Jones JG, Cen SY, Lebel RM, Hsieh PC, Law M. Diffusion tensor imaging correlates with the clinical assessment of disease severity in cervical spondylotic myelopathy and predicts outcome following surgery. *AJNR Am J Neuroradiol* 2013;34(2):471-8. <https://doi.org/10.3174/ajnr.a3199>