

# A tale of wandering T-tube: Complete Duodenal Migration and Successful Retrieval

Dahal P<sup>1</sup>, Dawadi K<sup>1</sup>, Parajuli S<sup>2</sup>

<sup>1</sup>Department of Radiology and Imaging, Grande International Hospital, Kathmandu, Nepal

<sup>2</sup>Department of Pathology, National Academy of Health Sciences Bir Hospital, Kathmandu, Nepal

Received: June 25, 2023

Accepted: June 28, 2023

Published: June 30, 2023

## Cite this paper:

Dahal P, Dawadi K, Parajuli S. A tale of wandering T-tube: Complete Duodenal Migration and Successful Retrieval. *Nepalese Journal of Radiology* 2023;13(1):21-3. <https://doi.org/10.3126/njr.v13i1.57829>

## ABSTRACT

A 33 years male presented with obstructive jaundice and was diagnosed as chronic cholecystitis with choledochocystolithiasis. The gastroenterology team performed ERCP with sphincterotomy to retrieve stone in common bile duct but failed. Open cholecystectomy with common bile duct exploration was done after few days. T-tube was placed in common bile duct. In the 8th post-operative day, tube manipulation was done due to reduced drain output and pain abdomen. We performed T-tube cholangiogram on 12th postoperative day which showed duodenal migration of T tube. The displaced T tube was retrieved using a simple technique.

**Keywords:** Cholecystectomy; Jaundice; Sphincterotomy; T-tube

## INTRODUCTION

Biliary T-tube is placed in the common bile duct (CBD) following CBD exploration for 10 to 14 days to facilitate tract maturation, prevent intraperitoneal bile leakage and to help heal in the early postoperative period. A T-tube cholangiogram done prior to T-tube removal confirms the absence of leakage through the CBD and residual persistent distal CBD obstruction due to calculus or stricture. Major complications while T-tube in situ are biliary leakage, sepsis, fluid and electrolyte disturbance and T-tube dislodgement. Post drain removal, the patient may have biliary peritonitis or biliary fistula or may present with CBD stricture later on. Migration of the T-tube is a known complication following ERCP with sphincterotomy, however, only a few are documented. We present here a rare instance of complete migration of the T-tube into the

D2 segment of the duodenum detected on routine follow-up cholangiogram, a simple novel technique to confirm its location and technique of removal of migrated T-tube.<sup>1,2,3,4</sup>

## CASE REPORT

The index case, a 33 years male from a remote district presented to gastroenterology OPD with obstructive jaundice. Ultrasonography and MRCP revealed chronic cholecystitis and choledochocystolithiasis. The gastroenterology team performed ERCP with sphincterotomy and an attempt was done to retrieve CBD calculus, but failed. They kept a plastic stent in CBD to facilitate bile drainage. After a few days, gastroscopy team performed an open cholecystectomy with CBD exploration. CBD calculus and plastic stents were

**Correspondence to:** Dr. Prajwal Dahal  
Department of Radiology and Imaging  
Grande International Hospital  
Kathmandu, Nepal  
Email: [meprajwal7@gmail.com](mailto:meprajwal7@gmail.com)

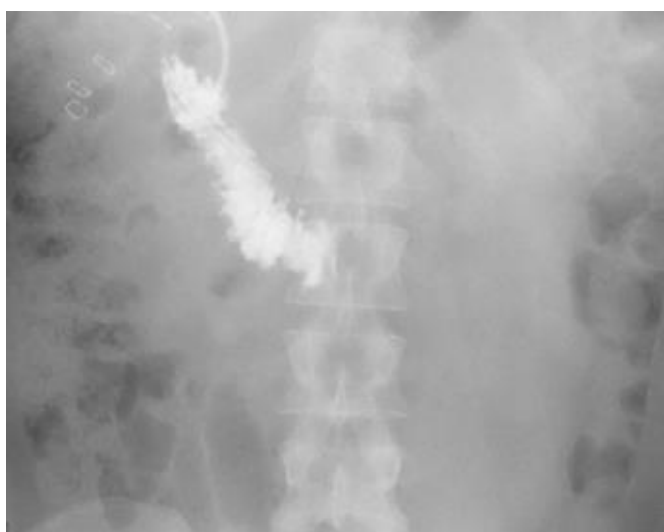

Licensed under CC BY 4.0 International License which permits use, distribution and reproduction in any medium, provided the original work is properly cited

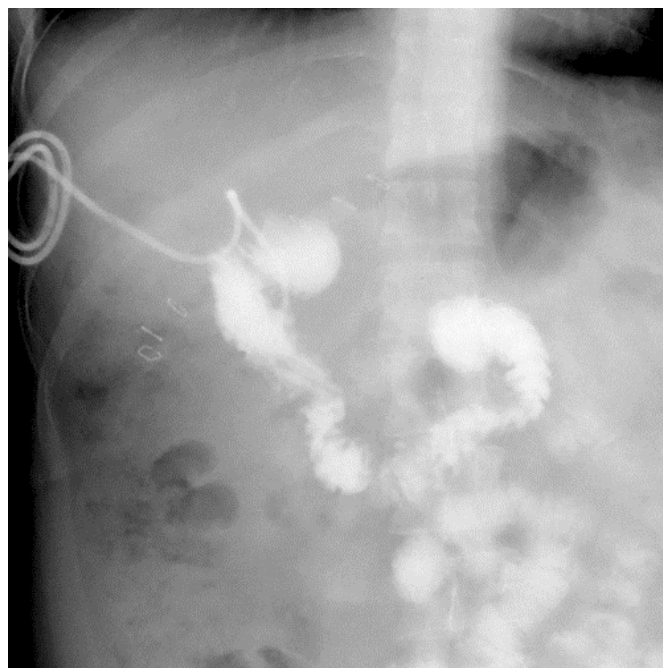
removed surgically and a 14F T-tube was placed in CBD to facilitate track maturation. The surgery was uneventful. T-tube drain was about 100-150 ml/day during the initial postoperative period. On the 8th postoperative day, the patient had severe pain abdomen and drain output dropped to < 15 ml/day. He went to a local hospital. Manipulation and flushing of the T-tube were done there. The skin anchoring suture of the T-tube was torn during this manipulation. The patient noticed relief of pain and the drain output increased to 300-500 ml/day.

In our hospital, on the 12th postoperative day, a T-tube cholangiogram was done by injecting 40ml of 50% diluted water-soluble iodinated contrast through the T-tube catheter after clamping its external end. Prompt opacification of both the limbs of the internal end of the T-tube was noticed, and free spillage of contrast into the second part of the duodenum was seen passing freely to the jejunum. T-Tube was seen within the pool of the contrast in the duodenal lumen. No opacification of the intra or extrahepatic biliary system was seen. No extravasation of the contrast was evident (Figures 1 & 2).

Later, the patient was asked to drink 500 ml of red-coloured fruit juice, 400 ml of which was promptly drained via a T-tube, further confirming its location in the gut. The patient tolerated the clamping of the T-tube well which was removed by gentle traction.



**Figure 1:** Anteroposterior view during initial phase of T-tube cholangiogram showing free and prompt passage of the contrast into the D2 segment of duodenum with 'T' point (long arrow) of T-tube lying in its lumen



**Figure 2:** Figure showing the passage of contrast to the jejunum. Intra or extrahepatic biliary system is not opacified in either of the phases. T-tube is seen in situ (small arrows)

## DISCUSSION

Dislodgement of plastic CBD stents after ERCP with sphincterotomy is a known complication and is seen quite frequently. However, complete dislodgement of the T-tube into the duodenum is not quite often seen and rarely documented. Joshi et al. reported a case of the duodenal migration of a T-tube in a patient who had a history of failed CBD stone retrieval by ERCP and papillotomy. Like our index case, the patient was managed by cholecystectomy, CBD exploration, and T-tube placement. T-tube migration was detected incidentally on follow-up T-tube cholangiogram and removed endoscopically. They proposed papillotomy as a cause for the tube dislodgement. Sphincterotomy done during ERCP to retrieve the CBD calculus and manipulation of the T-tube in the index case might have caused its passage into the duodenum across the patulous sphincter. The tube was in situ during the immediate postoperative period, this would have given enough time for the track to mature hence patient didn't have bile leak, bilioma formation or biliary peritonitis.<sup>4,5,6</sup>

Joshi et al. have advocated endoscopic removal of the tube which is a safer approach. Duodenal migration of the T-tube may cause pancreatitis or

cholangitis. In the present case, the patient was asymptomatic, both ends of the tube were intra-duodenal and T-tube was near the already dilated sphincter hence gentle traction was attempted and T-tube was removed with no complaints or complications.<sup>4</sup>

Krishnan et al. reported intraperitoneal migration of the external end of the biliary T-tube that was successfully retrieved by ERCP after sphincterotomy.<sup>7</sup>

## CONCLUSION

A T-tube cholangiogram obtained before removing the T-tube can detect the drain migration and aid in planning its removal. Non-opacification of the intra or extrahepatic biliary system should prompt the investigator to look for the possible dislodgement of the T-tube and it's both limbs should be searched to confirm. Spillage of contrast outside the biliary system may suggest intraperitoneal migration of the tube or perforation of the biliary system or duodenum.

## CONFLICT OF INTEREST

None

## SOURCES OF FUNDING

None

## REFERENCES

1. Akram M, shokat I, Azad TP. T-tube drainage of common bile duct after open CBD exploration for choledocholithiasis. *International Journal of Research and Review* 2020;7(7):120-6. Available from: [https://www.ijrrjournal.com/IJRR\\_Vol.7\\_Issue.7\\_July2020/IJRR0013.pdf](https://www.ijrrjournal.com/IJRR_Vol.7_Issue.7_July2020/IJRR0013.pdf) [Accessed 27th June 2023]
2. Fadel BA, Hamad MA, Elkoussy AM, Mohamed MA, Mohammed MM. Common bile duct repair after exploration with versus without T-tube: A prospective randomized comparative study. *The Egyptian Journal of Surgery* 2022;41(3):1024-9. Available from: [https://journals.lww.com/ejos/Fulltext/2022/07000/Common\\_bile\\_duct\\_repair\\_after\\_exploration\\_with.20.aspx?context=LatestArticles](https://journals.lww.com/ejos/Fulltext/2022/07000/Common_bile_duct_repair_after_exploration_with.20.aspx?context=LatestArticles) [Accessed 28th June 2023]
3. Wills VL, Gibson K, Karihaloo C, Jorgensen JO. Complications of biliary T-tubes after choledochotomy. *ANZ J Surg* 2002;72(3):177-80. <https://doi.org/10.1046/j.14452197.2002.0230.x>
4. Joshi MA, Gadhire M, Singh M, Shrotriya R. A rare case of migration of a T-tube into the duodenum. *Endoscopy* 2014;46(S 01):E142. <https://doi.org/10.1055/s-0034-1364943>
5. Katsinelos P, Kountouras J, Paroutoglou G et al. Migration of plastic biliary stents and endoscopic retrieval: an experience of three referral centers. *Surg Laparosc Endosc Percutan Tech* 2009;19(3):217-21. <https://doi.org/10.1097/sle.0b013e3181a031f5>
6. Krishnan, A. and Ramakrishnan, R., 2011. Endoscopic management of a migrated biliary T-tube. *Endoscopy* 2011;43(S 02):E325-E325. <https://doi.org/10.1055/s-0030-1256739>