

Incidence of Ectopic Pregnancy and its Diagnostic Accuracy by Clinical, Ultrasound and Intraoperative Findings

Shrestha S¹, Dwa Y², Jaiswal P², Maharjan D³, Karki P³, Shrestha SD⁴

¹Associate Professor, ²Assistant Professor, ³Lecturer, Department of Radiology and Imaging, ⁴Associate Professor, Department of Gynecology and Obstetrics, Patan Academy of Health Sciences, Lalitpur, Nepal

Received: January 22, 2022

Accepted: March 1, 2022

Published: June 30, 2022

Cite this paper:

Shrestha S, Dwa Y, Jaiswal P, Karki P, Maharjan D, Shrestha SD. The Incidence of ectopic pregnancy and its diagnostic accuracy by clinical, ultrasound and intraoperative findings. *Nepalese Journal of Radiology*.2022;12(1):18-24. <https://doi.org/10.3126/njr.v12i1.45245>

ABSTRACT

Introduction:

In an ectopic pregnancy, most patients present with 5 to 9 weeks of amenorrhea, mild pelvic pain and vaginal spotting which triggers the evaluation of ectopic pregnancy. The presence of an extrauterine gestational sac containing a yolk sac or embryo is the most specific sonographic finding whereas an echogenic tubal ring in the adnexa is the most common finding.¹ This study aimed to find the accuracy of ultrasound findings versus clinical presentation, intraoperative findings and histological findings.

Methods:

This is a retrospective study. All patients with histopathological diagnoses of ectopic pregnancy were included in the study and data regarding clinical diagnosis, ultrasound diagnosis and intraoperative diagnosis were retrieved and compared with their histopathological diagnosis.

Result:

There were 216 cases of ectopic pregnancy with an overall incidence of ectopic pregnancy was 0.88%. The sensitivity with ultrasound diagnosis was 99.52% and specificity 11.11% with positive and negative predictive values were 96.2 % and 50 % respectively and overall diagnostic accuracy of 95.83%. The sensitivity was 97.6% and specificity was 11.1% for clinical diagnosis of ectopic pregnancy. The sensitivity was 100% for intraoperative diagnosis of ectopic pregnancy with a positive predictive value is 95.83%.

Conclusion:

Clinical diagnosis, intraoperative findings and ultrasound findings were highly sensitive to detecting ectopic pregnancy in the study population. The overall diagnostic accuracy was highest for the ultrasound finding.

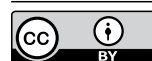Keywords: *Pregnancy, Ectopic; Ultrasonography; Nepal*

Correspondence to: Dr. Shreejana Shrestha

Department of Radiology and Imaging

Patan Academy of Health Sciences, Lalitpur, Nepal.

Email: shreejanashrestha@pahs.edu.np



Licensed under CC BY 4.0 International License which permits use, distribution and reproduction in any medium, provided the original work is properly cited

INTRODUCTION

The global incidence of ectopic pregnancy is 1-2 in 100 pregnancies whereas in UK 11.1/1000 pregnancies and Norway (14.9/1000).² However a hospital-based study done in Nepal found an incidence of 7.3 per 1000 pregnancies. Most patients present with 5 to 9 weeks of amenorrhea, mild pelvic pain and vaginal spotting which triggers the evaluation of ectopic pregnancy. Sonographic features of ectopic pregnancy vary according to the location of ectopic pregnancy. The presence of an extrauterine gestational sac containing a yolk sac or embryo is the most specific sonographic finding whereas an echogenic tubal ring in the adnexa is the most common sonographic finding which is a non-specific finding. Intrauterine findings in ectopic pregnancy include a normal endometrium, pseudogestational sac, a trilaminar endometrium and a thin-walled decidual cast.¹ The diagnosis is usually made clinically based upon ultrasound findings and beta HCG along with intraoperative findings or histopathological findings of an operative specimen. Intraoperative findings in ectopic pregnancy showed intact gestational sac, ruptured ectopic and less negative laparotomy. Correlation between intraoperative findings and ultrasound findings showed a significant association between intact ectopic pregnancy and ruptured ectopic pregnancy had non-specific findings.⁴ Diagnostic tests for detecting ectopic pregnancy were found a sensitivity of 88%, specificity of 37% positive predictive value of 82.1% and negative predictive values 50% however for ruptured ectopic pregnancy showed sensitivity 61% and specificity 100%, positive predictive value 100% and negative predictive value 44%.^{5,3} This study aimed to find the accuracy of ultrasound findings versus clinical presentation and intraoperative findings.

METHODS

This is a retrospective observational cross-sectional study done in the Radiology and Imaging department and Department of Gynaecology of Patan Hospital, Patan Academy of Health Science, Lagankhel for 5 years. First, all the hospital numbers of patients

with a discharge diagnosis of ectopic pregnancy within the period of January 2016 to December 2021 based on ultrasound with surgical management & histopathology reports were studied. All files were retrieved from the medical record section by using the International Classification of Disease (ICD) code- 633. All patients with a histopathological diagnosis of ectopic pregnancy included in the study underwent surgical management. Those whose histopathological reports were not available and who underwent non-surgical treatment were excluded from the study. From the patient's file, data regarding clinical diagnosis, ultrasound diagnosis and its findings and intraoperative diagnosis were retrieved and compared with the histopathological diagnosis. If the patient had both transabdominal and transvaginal ultrasound done, only transvaginal ultrasound will be considered as the sensitivity of transvaginal ultrasound is more than transabdominal ultrasound.^{4,5} The general objective of this study, was to find the incidence of ectopic pregnancy and its accuracy with clinical, ultrasound and, intraoperative findings of open laparotomy and histopathological findings of the intraoperative tissue specimen.

Ultrasound features of ectopic pregnancy were specific findings which include gestational sac with the embryo (with or without cardiac activity) outside the uterine cavity⁴ and non-specific finding including adnexal mass with cystic changes of the product of conception (POC), irregularity or increased or complex echogenicity that is separate from the ovary, Pseudogestational sac in the uterine cavity or decidual cast in the uterine cavity, free fluid in the abdominal cavity and tubal ring sign and ring sign on colour Doppler of ectopic mass.^{1,4} Intraoperative features of ectopic pregnancy include Intact gestational sac, ruptured ectopic mass and hematoma and free fluid in the peritoneal cavity. Clinical diagnoses of yes or no were noted. Histological features of ectopic pregnancy were the presence of chorionic villi. Names and privacy of Participants were not disclosed and kept confidential. Data processing and analysis were

computed and its accuracy with clinical diagnosis, intraoperative findings of open laparotomy, ultrasound findings and histopathology diagnosis using sensitivity, specificity and predictive values (positive and negative values) were done. Data were entered in a Microsoft Excel spreadsheet and analyzed using SPSS 20 software. Specific and non-specific findings of ultrasound were described as numbers and percentages.

RESULTS

The distribution of age of patients was bell-shaped with a mean of 28.86 years and a standard deviation of 5.59 years (Figure 1).

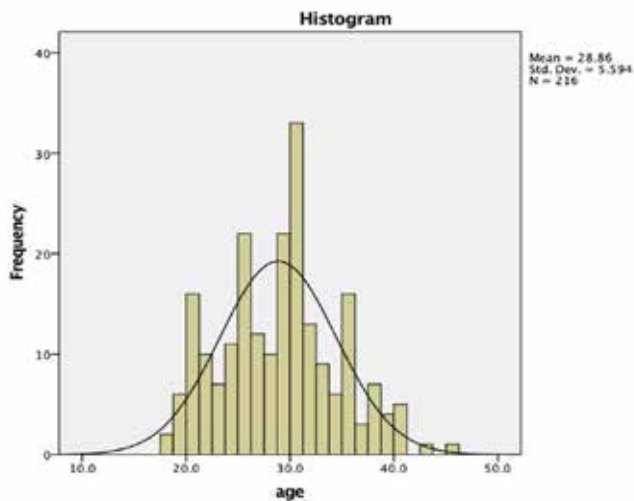


Figure 1: Distribution of study population by age

The minimum age was 18 years and the maximum was 45 years giving a range of 27 years. The median was 29 years, which means half of the patients were below 29 years whereas half were 29 years and above. The mode was 30 years, which means a maximum number of patients were of 30 years of age. Among 216 cases 210 were clinically suspected as ectopic pregnancy and 6 cases were not suspected as ectopic pregnancy and 214 were diagnosed as ectopic pregnancy by ultrasound scan and 2 cases were not diagnosed by ultrasound.

Table 1 shows the incidence of ectopic pregnancy in Patan Hospital. The total number of patients with optic pregnancies in the study period was 216 where 195 cases were done with the transabdominal scan

and 21 cases were transvaginal. Most (90.27%) of ectopic cases were diagnosed with a transabdominal scan. The total number of cases in the first-trimester scan was 24224 giving an incidence of 0.8% for transabdominal scan whereas the total number of the transvaginal scan was 336 so the incidence of ectopic pregnancy for the transvaginal scan was 6.20%. The overall incidence of ectopic pregnancy based on the total number of ultrasounds done in the study period was 0.88%. There were 21385 delivery cases in five years period giving an incidence of ectopic pregnancy of 10.1 per 1000 deliveries.

Table 1: Incidence of ectopic pregnancy by ultrasound types and total

Ultrasound type	Ectopic pregnancies	USG numbers	Incidence
Transabdominal (TA)	195	24224	0.00804
Transvaginal (TV)	21	336	0.062
Total	216	24560	0.00879

Among 216 cases, various features were seen in the ectopic pregnancy cases. Adnexa mass was seen in most of the cases 89 (41.2%) followed by mass with hemoperitoneum 55 (25.5%) cases, hemoperitoneum only in 43 (19.9%) cases, live ectopic in 23 (10.6%) cases and gestational sac on 4 (1.9%) cases and only two cases were with no features of ectopic pregnancy (Table 2).

Table 2. Ultrasound features of ectopic pregnancy

Features	Frequency	Percentage
Adnexa mass	89	41.2
Mass + Haemoperitonium	55	25.5
Live ectopic	23	10.6
Gestational sac	4	1.9
Haemoperitonium	43	19.9
Missing	2	0.9
Total	216	100.0

There were 23 (10.64%) specific and 191 (88.4%) non-specific findings. All the cases were treated surgically and histopathological analysis confirmed

207 cases as Product of conceptus (POC) and 9 were flagged as others like ruptured corpus luteal cyst (2n), ovarian hemorrhagic cyst(2n), chocolate cyst (1n)and fallopian tube inflammation (4n). There were 118(54.6%) right side and 98 (45.4%) left side with predominantly being ampullary (86.6%), Isthmus (4.6%), Fimbria (4.2%), Ovary (1.9%) , Cornua (1.4%), stump (0.9%) and stump(0.5%).

Among 216 cases, a total of 210 cases were clinical diagnoses of ectopic pregnancy and 6 cases were not diagnosed as ectopic pregnancy as shown in Table 3. The sensitivity was 97.6% and specificity was 11.1% for clinical diagnosis of ectopic pregnancy with a positive predictive value was 96.91% and a negative predictive value was 16.67%.

Table 3. Clinical diagnosis by Histopathology finding

Total count % within HPE	Histopathological Diagnosis		Total
	Yes	No	
Clinical diagnosis			
Yes	202 97.6%	8 88.9%	210 97.2%
No	5 2.4%	1 11.1%	6 2.8%
Total	207 (100%)	9 (100%)	216 (100%)
Overall Accuracy	93.98%		
Sensitivity	97.58%		
Specificity	11.1%		
Positive predictive values	96.91%		
Negative Predictive values	16.67%		

Table 4. Surgical findings by histopathological finding

Total count % within HPE	Histopathological Diagnosis		Total
	Yes	No	
Intraoperative diagnosis			
Yes	207 100.0%	9 100%	216 100%
No	0	0	0
Total	207 (100%)	9 (100%)	216 (100%)
Overall Accuracy	95.83%		
Sensitivity	100%		
Specificity	0.0%		
Positive predictive values	95.83%		
Negative Predictive values	0		

Among 216 cases, all cases were found to be extrauterine mass intraoperatively with sensitivity is 100% for surgical as all the cases were managed

surgically as shown in Table 4. No negative laparotomy was found among these 216 cases.

Table 5. Ultrasound findings by histopathological finding

Total count % within HPE	Histopathological Diagnosis		Total
	Yes	No	
Ultrasound diagnosis			
Yes	206 99.5%	8 99.5%	214
No	1 0.5%	1 0.5%	2
Total	207	9	216
Overall Accuracy	95.83%		
Sensitivity	99.52%		
Specificity	11.11%		
Positive predictive values	96.26%		
Negative Predictive values	50%		

Among 216 total cases, 214 cases were diagnosed as ectopic pregnancy and only 2 cases were diagnosed as non-ectopic pregnancy as shown in Table 5. The sensitivity with ultrasound diagnosis was 99.52% and specificity was 11.11% with a positive predictive value was 96.26% and a negative predictive value was 50 % as most cases were diagnosed as ectopic pregnancy by ultrasound.

DISCUSSION

This study was done at the Patan Academy of Health Science (PAHS) at Patan Hospital to find the incidence of ectopic pregnancy and its accuracy with clinical, ultrasound findings, intraoperative findings of open laparotomy and histopathological findings of intraoperative tissues specimen in which histological diagnosis was taken as the gold standard. The total number of patients was 216 and among them, 195 cases were done with a transabdominal scan and 21 cases were transvaginal. Among 216 total cases, 214 cases were diagnosed as ectopic pregnancy and 2 cases were diagnosed as non-ectopic pregnancy. The sensitivity with ultrasound diagnosis was 99.52% and specificity 11.11% with positive and negative predictive values were 96.2 % and 50 % respectively and diagnostic accuracy with 95.83%. In this study, we found a sensitivity of 97.6% and specificity of

11.1 for clinical diagnosis of ectopic pregnancy so we have to correlate both clinical and ultrasound diagnosis. Similar findings were found by Thapa et al. revealed that the sensitivity of transabdominal scan for ectopic pregnancy was 100% with a Positive predictive value is 94%.⁷ Obajima et al. study done in Nigeria found a diagnostic test for detecting ectopic pregnancy found a sensitivity of 88%, specificity of 37%, positive predictive value 82.1% and negative predictive values 50% which is similar to our findings.⁵ Similar studies done in Bangladesh found Sensitivity, specificity, positive predictive value, negative predictive value and accuracy of transabdominal ultrasonography as a diagnostic modality in the evaluation of suspected ectopic pregnancy were 73.1%, 75%, 95%, 30% and 73.3% respectively whereas transvaginal ultrasonography was found to have 92.3% sensitivity, 75% specificity, 96% positive predictive value, 60% negative predictive value and 90% accuracy.⁸ Shetty et al. found ultrasonography provided a definitive diagnosis resulting in 100 % sensitivity and 100 % specificity, the predictive value of positive test being 100 %⁹ which is similar to our study with a sensitivity of 99.52%. Another study suggested that the sensitivity and specificity of ultrasound for the detection of confirmed ectopic pregnancy were 88.5% and 96.5% on the initial

TVUS and 93.1% and 95.7% with an additional rescans.¹⁰ In this study we enrolled 21 patients for a transvaginal scan which is inconclusive by transabdominal scan and later diagnosed as ectopic pregnancy.

The median was 29 years, which means half of the patients were below 29 years whereas half were 29 years and above. Similar findings were found by Ismail et al. in which 48.2% of women had aged 20-30 years and 40.9% had aged 31-40yrs.⁴ Obajimi et al. stated that the mean age of 29.9± 5.1 years is correspondence to the peak age of sexual activity and reproductive career in most women.⁵ Similar age was also found by a study done in Nepal.⁷ The overall incidence of ectopic pregnancy in the study period was 0.88% that is 8.8 per 1000 pregnancies and 10 per 1000 deliveries as similar findings in a hospital-based study done in Nepal had found the incidence of 7.3 per 1000 pregnancies and 10.2 per 1000 deliveries.³

In this study adnexa mass was seen in most of the cases 89 (41.2%) followed by mass with hemoperitoneum 55(25.5%), hemoperitoneum only 43 (19.9%), live ectopic cases 23(10.6%) and gestational sac 4(1.9%) which is similar findings Thapa NB, et al in which adnexal mass with pelvic fluid 15 (83.3%)⁷where as similar other studies stated that hemoperitoneum being the commonest findings during an ultrasound with 95.5% of patients.^{5,11,12} In this study specific findings with live ectopic pregnancy is 10.64% and non-specific findings like adnexal mass, hemoperitoneum and gestational sac being 88.4% which is similar to the study done by Khairy et al in which specific findings of 9.1%. On the other hand, the most common findings by ultrasound were non-specific findings 79.1% and specific findings 19.1% reported.⁴

In this study, all were treated surgically and had no negative laparotomy as all had positive findings of adnexal mass along with hemoperitoneum and similar findings were done in the southwest of England in which true negative histology for surgically managed ectopic pregnancy is less than 1%.¹³ Khairy et al. reported negative laparotomy is

2.7%.⁴

CONCLUSION

Clinical diagnosis, intraoperative findings and ultrasound findings were highly sensitive to detecting ectopic pregnancy in the study population. However, overall diagnostic accuracy was highest for the ultrasound finding so clinical diagnosis must be complemented by the ultrasound finding for detecting ectopic pregnancy. In this study, we can conclude that ultrasound (both transvaginal and transabdominal) had high diagnostic accuracy for the diagnosis of ectopic pregnancy with a sensitivity of 99.52% and specificity of 11.11% with positive and negative predictive values were 96.2 % and 50 % respectively and diagnostic accuracy with 95.83%. The most common findings by ultrasound were non-specific findings (88.4%) and specific findings was (10.64%). The overall incidence of ectopic pregnancy in the study period was 0.88% that is 8.8 per 1000 pregnancies and 10 per 1000 deliveries. All cases were managed surgically and none of these cases was a negative laparotomy. In this study, clinical diagnosis accuracy is 93.8%, sensitivity 97.58% and specificity 11.1%.

CONFLICT OF INTEREST

None

SOURCES OF FUNDING

None

REFERENCES

1. Lin EP, Bhatt S, Dogra VS. Diagnostic clues to ectopic pregnancy. *Radiographics*. 2008;28(6):1661–71. <http://dx.doi.org/10.1148/rg.286085506>
2. Varma R, Gupta J. Tubal ectopic pregnancy. *BMJ Clin Evid*. 2012;2012.
3. Pradhan P, Thapamagar SB, Maskey S. A profile of ectopic pregnancy at nepal medical college teaching hospital. *Nepal Med Coll J*. 2006;8(4):238–42.
4. Hassan AE. Correlation between ultrasound findings of ectopic pregnancy and operative

- findings in Sudanese women. *Interventions in Gynaecology and Women's Healthcare*. 2018;1(1). <http://dx.doi.org/10.32474/igwhc.2018.01.000103>
5. Obajimi GO, Smart AE, Adekanmi AJ, Adeniji-Sofoluwe A, Jinadu FO. Correlation between transabdominal ultrasound features of ectopic gestation and surgical findings at the university college hospital, Ibadan: A preliminary review. *Trop J Obstet Gynaecol*. 2019;36(2):265.
 6. Ravindra S, Prasad S, Suguna B. Histomorphology of fallopian tubes in ectopic pregnancy. *Arch Med Health Sci*. 2016;4(2):201. <http://dx.doi.org/10.4103/2321-4848.196190>
 7. Thapa NB, Dwa YP. Role of transabdominal ultrasound in detection of ectopic pregnancy. *J Coll Med Sci-Nepal*. 2016;12(1):1–4. <http://dx.doi.org/10.3126/jcmsn.v12i1.14397>
 8. Nahar MN, Quddus MA, Sattar A, et al. Comparison of transvaginal and transabdominal ultrasonography in the diagnosis of ectopic pregnancy. *Bangladesh Med Res Counc Bull*. 2013;39(3):104–8. <http://dx.doi.org/10.3329/bmrcb.v39i3.20309>
 9. Shetty VH, Gowda S, Muralidhar L. Role of ultrasonography in diagnosis of ectopic pregnancy with clinical analysis and management in tertiary care hospital. *J Obstet Gynaecol India*. 2014;64(5):354–7. <http://dx.doi.org/10.1007/s13224-014-0529-0>
 10. Young L, Barnard C, Lewis E, Jones M, Furlan J, Karatasiou A, et al. The diagnostic performance of ultrasound in the detection of ectopic pregnancy. *N Z Med J*. 2017;130(1452):17–22.
 11. Akaba GO, Agida TE, Onafowokan O. Ectopic pregnancy in Nigeria's federal capital territory: a six year review. *Niger J Med*. 2012;21(2):241–5.
 12. Cornelius AC, Onyegbule A, Onyema, Uchenna ET, Duke OA. A five year review of ectopic pregnancy at Federal Medical Centre, Owerri, South East, Nigeria. *Niger J Med*. 2014;23(3):207–12.
 13. Shehab QJ, Dolloway L, Damra AM, Al Zoubi MS, Albeitawi SN. Negative histology in surgically managed tubal ectopic pregnancy. *Int J Gynaecol Obstet*. 2022;157(3):719–22. <http://dx.doi.org/10.1002/ijgo.13913>