

# Mesenteric Hydatid Cyst

Singh BK

Department of Radiology, NRI Institute of Medical Sciences, Visakhapatnam, India

Received: July 28, 2018

Accepted: September 10, 2018

Published: December 30, 2018

**Cite this paper:**

Singh BK. Mesenteric hydatid Cyst. *Nepalese Journal of Radiology* 2018;8(12):43-46. <https://doi.org/10.3126/njr.v8i2.22988>

## ABSTRACT

The aim of this article is to make radiologists and clinicians familiar with the spectrum of cystic lesions in the abdomen. Mesenteric and omental cystic lesions are uncommon. One should be familiar with them as well as with other conditions that manifest as cysts. Initial step in diagnosing a cystic abdominal mass is to localize the organ of origin. Differential diagnosis includes enteric duplication cyst, enteric cyst, mesothelial cyst, non pancreatic pseudocyst, cystic mesothelioma, cystic teratoma, and urachal cyst. There is significant overlap in imaging features of abdominal cysts, which often require histological correlation to establish a final diagnosis. The main role of imaging is to document the nature of the abdominal mass and its origin.

**Keywords:** *Mesentery; Omentum; Radiologists*

## INTRODUCTION

Hydatid disease is caused by the echinococcus tapeworm, and can result in cyst formation anywhere in the body. There are two main species of the echinococcus a) echinococcus granulosus and b) echinococcus multilocularis.<sup>1,2</sup> It is endemic in some areas of the world. Liver and lungs are most commonly involved organs. Mesenteric hydatid cyst is an uncommon location. In this article, we present a diagnosed case of mesenteric hydatid cyst with radiologic finding, peroperative specimen and correlated with histopathologic findings.

**Correspondence to:** Dr. Bikash Kumar Singh

Department of Radiology

NRI Institute of Medical Sciences

Visakhapatnam, India

Email: [vikashdoc220785@gmail.com](mailto:vikashdoc220785@gmail.com)

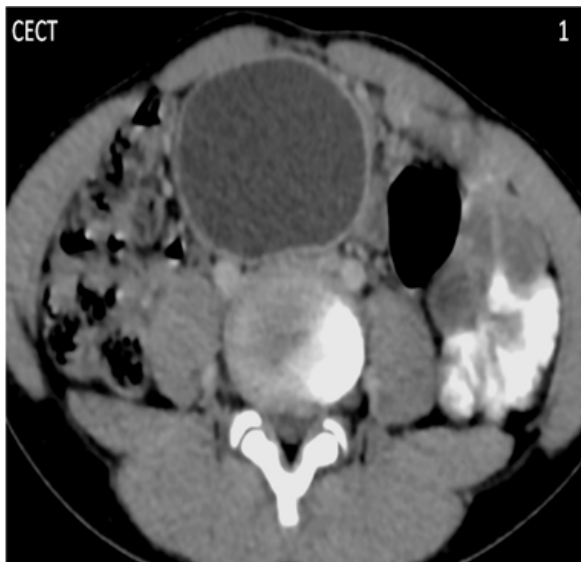

Licensed under CC BY 4.0 International License which permits use, distribution and reproduction in any medium, provided the original work is properly cited

## CASE REPORT

A 13 year old male child presented with mass per abdomen in umbilical region since 6 months which is gradually increased in size. It is not associated with pain, vomiting or fever. His bowel and bladder habits were normal. No similar complaints in the past. No significant family history. On clinical examination it is a firm mass measuring about 5 cm diameter, which was freely mobile and not adherent to overlying skin.

CT abdomen was carried out with oral and intravenous contrast, which revealed a well circumscribed cystic lesion (10 HU), relatively more towards the right of mid line (Figure 1), measuring 6.6 x 4.4 x 5 cm. No internal septa or daughter cysts seen within the cyst. It is located between L4, L5 vertebral bodies and rectus abdominis muscle (Figure 2B). It is displacing the small bowel loops posterolaterally (Figure 2A).

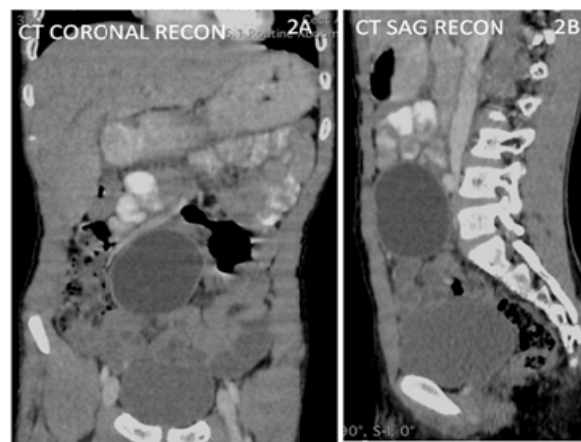


**Figure 1:** Well circumscribed peripherally enhancing cystic lesion in the abdomen with no evidence of septa, daughter cyst or calcification

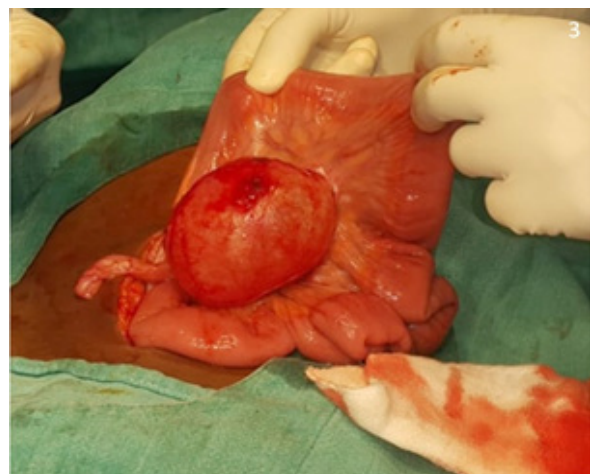
In this case total cystectomy was done. It is important for the surgeons to treat all cysts

with utmost care and attempt total removal of cyst without rupture, keeping in mind that any cyst may turn out to be hydatid cyst. This protocol was carried out in this case. This protocol is important to avoid anaphylactic reaction and recurrence of the hydatid disease.

The peroperative specimen (Figure 3) was sent for histopathologic diagnosis which demonstrated germinal layer, central scolex, daughter cysts (Figure 4) confirming the diagnosis.



**Figure 2:** A. Hypodense cystic lesion seen more to the right of mid line B. The cyst lies between the lumbar vertebrae and the rectus abdominis muscle

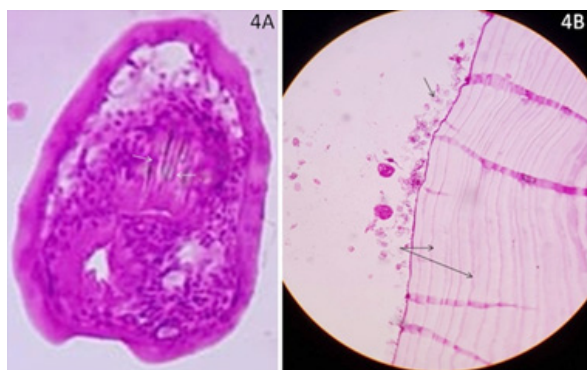


**Figure 3:** Peroperative specimen showing intact cyst wall with adjacent bowel loops and mesentery, the cyst is popping out

## DISCUSSION

Humans become infected by ingesting contaminated food with echinococcus eggs, and are intermediate hosts.<sup>1</sup> The mechanism of infestation is not clear, however dissemination via lymphatic or systemic circulation has been thought as possible route.

The hydatid cysts have three layers- a) outer pericyst is formed by the host cells as a fibrous protective zone, b) the middle laminated membrane, which is acellular and allows the passage of nutrients, and c) the endocyst, where the scolices (Figure 4A) and the germinal layer are produced.<sup>2,3</sup> The above mentioned layers usually are thick in the liver, less appreciated in muscle, hardly appreciable in bone, and sometimes visible in brain.<sup>2,3,4</sup> Daughter cysts are small spheres that contain the protoscolices and are formed from rests of the germinal layer (Figure 4B). Initially these daughter vesicles are attached by a pedicle to the germinal layer of the mother cyst.



**Figure 4:** A. Microscopic examination shows central scolex (white arrows) B. Multilayer laminated germinal layer (twin black arrows) with multiple daughter cysts (arrow)

Based on morphology the cysts are classified into four different types.<sup>3</sup> Type I cysts are simple cyst with no internal matrix. Type II cysts are with daughter cysts and internal matrix. Type III cysts are calcified cyst. Type IV cysts are complicated cyst.<sup>3</sup> The

complications include mass effect, peritoneal seeding, rupture of cyst, infection of the cyst, transdiaphragmatic involvement of lung, mediastinum and cardia. There is no specific symptoms of mesenteric hydatid disease and usually remains asymptomatic for years. Clinical manifestation is due to mass effect on adjacent structures or slowly growing mass per abdomen.

Ultrasound is diagnostic if there are wall calcifications, internal septations, daughter cysts and hydatid sand appearance. CT is the modality of choice before planning for surgery and for demonstrating complications related to cyst rupture. In difficult cases combination of radiologic and pathologic tests are diagnostic of hydatid disease. The treatment of choice is complete surgical excision as was done in this case. The use of hypertonic saline or hydrogen peroxide solutions before opening the cavity kills the daughter cysts which prevents further spread or anaphylactic reaction. Mebendazole or albendazole are used as adjuvant therapy to surgery to prevent recurrence.

## CONCLUSION

Mesenteric primary hydatid cyst is an uncommon site. In endemic areas, hydatid disease should be considered in the differential diagnosis of cystic lesions within the abdominal cavity. Surgery is the treatment of choice. It can show a variety of imaging features which differ according to the affected organ and the stage of the disease. Liver and lungs are the most commonly affected organs, however can form cyst anywhere in the body.

## CONFLICT OF INTEREST

None

## SOURCES OF FUNDING

None

## REFERENCES

1. Eckert J, Deplazes P. Biological, epidemiological, and clinical aspects of echinococcosis, a zoonosis of increasing concern. *Clin Microbiol Rev* 2004;17(1):107-135. <http://dx.doi.org/10.1128/CMR.17.1.107-135.2004>
2. Pedrosa I, Saiz A, Arrazola J, Ferreirós J, Pedrosa CS. Hydatid Disease: Radiologic and Pathologic Features and Complications 1. *Radiographics* 2000;20(3):795-817. <https://doi.org/10.1148/radiographics.20.3.g00ma06795>
3. Polat P, Kantarci M, Alper F, Suma S, Koruyucu MB, Okur A. Hydatid disease from head to toe. *Radiographics* 2003;23(2):475-494. <https://doi.org/10.1148/rg.232025704>
4. Tuzun M, Hekimoglu B. Various locations of cystic and alveolar hydatid disease: CT appearances. *J Comput Assist Tomogr* 2001;25(1):81-87. <https://doi.org/10.1097/00004728-200101000-00014>