

Chest Ultrasound- Update 2018

Blank W, Mathis G

Medical Clinic I, Klinikum am Steinberg Reutlingen Teaching Hospital, University
Tübingen, Germany

Received: May 08, 2018

Accepted: May 15, 2018

Published: June 30, 2018

Cite this paper:

Blank W, Mathis G. Chest Ultrasound-Update 2018. *Nepalese Journal of Radiology* 2018;8(11):48-58. <http://dx.doi.org/10.3126/njr.v8i1.20465>

ABSTRACT

The scope of applications of chest ultrasound has been significantly widened in the last few years. Effusions as little as 5 ml can be identified without problems in a standing or sitting position laterodorsal in the angle between the chest wall and the diaphragm.

Portable ultrasound systems are being used to an increasing extent in preclinical sonography, at the site of trauma, in the ambulance of the emergency physician or in helicopters. In the emergency room, at the intensive care unit and in clinical routine, chest ultrasound has proved its worth as a strategic instrument to be used directly after the clinical investigation. Several diagnoses such as pneumothorax, (no sliding sign, no B-lines, no lung pulse, lung point) pneumonia (liver like consolidation with bronchoaerogram) rib fractures (step in cortical bone and hematoma) pulmonary embolism (typical subpleural lesions) can be established immediately. In combination with echocardiography and leg vein compression ultrasound (triple organ ultrasound), the accuracy is more than 90%. The evidence of interstitial syndrome has shown a significant correlation with extravascular lung water in cases of pulmonary edema and noncardiogenic pulmonary edema.

Chest ultrasound helps in the diagnosis and staging of lung cancer. Contrast ultrasound (CEUS) is a new tool for the differentiation of sub pleural lung lesions. Ultrasound guided interventions (biopsy, drainage) are very successful. The rate of complications is low when the procedure is performed by trained therapists.

Ultrasound is a fixed element of several international guidelines.

Key words: *Chest; Sonography; Ultrasound*

Correspondence to: Dr. Wolfgang Blank
Internist & Gastroenterologist
Medical Clinic I, Klinikum am Steinberg
Reutlingen
Teaching Hospital, University Tübingen
DEGUM - Instructor
D-72127 Jettenburg, Brunnenstr. 13
Email: wolfgang@hegeblank.de

INTRODUCTION

Ultrasonography of the lung has become an established imaging procedure for chest diseases. The acceptance of the method is reflected in a number of international guidelines.¹ Furthermore, ultrasound



Licensed under CC BY 4.0 International License which permits use, distribution and reproduction in any medium, provided the original work is properly cited

investigation of the lung has been established as a fundamental diagnostic procedure in emergency situations.

The ultrasound image does not provide a complete overview of the chest. However, it does show a certain portion of the chest and thus provides diagnostic information about a variety of problems.

Devices used for ultrasound investigation of the abdomen and the thyroid may also be used for investigation of the chest. A high-resolution linear transducer of 5-10 MHz is suitable for imaging the chest wall and the parietal pleura. Additionally, the recently introduced probes of 7.5–18 MHz are very useful for evaluating lymph nodes, the pleura,

and the surface of the lung.

A convex or sector probe of 3-4 MHz ensures sufficient depth of penetration for investigation of the lung and the mediastinum.

The investigation should be performed, as far as possible, with the patient seated, during inspiration and expiration, and if necessary in combination with respiratory maneuvers such as coughing or “sniffing”. Raising the arms and crossing them behind the head expands the intercostal spaces and facilitates the access (Fig. 1). The transducer is moved from ventral to dorsal along the longitudinal lines in the chest. The supine patient is examined in the same manner. The method of choice to detect a pneumothorax. The abdominal access is better in this setting.

Examination Technique

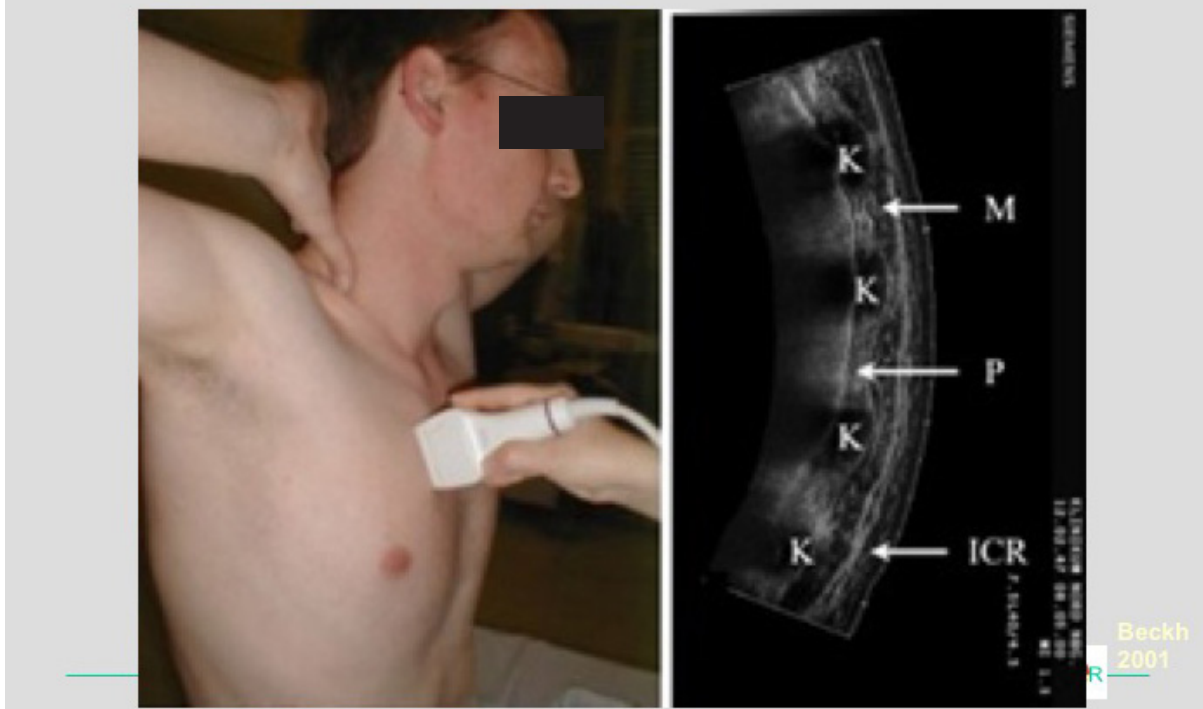

Figure 1: The investigation is performed as far as possible with the patient seated, during inspiration and expiration. Raising the arms and crossing them behind the head. The transducer is moved from ventral to dorsal. The panoramic image shows the cartilage (K) at the point of insertion of the rib. M (muscle), P (Line of the pleura), ICR (intercostal space)

The Chest Wall

Due to its rather superficial location, the chest wall is almost ideally suited for ultrasound investigation with high-resolution probes. The primary indications for performing an ultrasonography of the chest wall include the clarification of swelling or suspicious findings in the chest wall on palpation (is it solid or liquid? Is there an indication to puncture?), and targeted investigation of painful sites in the chest wall.

The visualization of lymph nodes and a tentative statement about the malignant or benign nature of a lesion constitute an important reason to perform an ultrasound investigation of the chest wall. However, the benign (more oval, well-defined, hilus sign, and central vascularization) or malignant nature of a lymph node (more round, irregular margins and vascularization) can only be established tentatively by its ultrasound morphology. Confirmation of the diagnosis requires a histological investigation of tissue obtained by performing a puncture.

After the lung, lymph nodes are the second most common site of manifestation of tuberculosis. Lymph node tuberculosis occurs in about 90% of patients without accompanying pulmonary tuberculosis.

On the ultrasonography image, lymph nodes are seen in various forms in the presence of tuberculosis and in some cases, it can be difficult to differentiate them from malignant lymph nodes.

An ultrasound investigation of the supraclavicular region is especially important in staging bronchial carcinoma because enlarged and usually non-palpable supraclavicular lymph nodes are found in as many as 51 % of patients with mediastinal N3 lymph nodes.²

Fractures of the rib (a fracture gap or a cortical step) can be seen well on

ultrasound (Fig 2). Fracture diagnosis by ultrasonography is not only much more sensitive than conventional X-rays, but also demonstrates accompanying soft tissue lesions and easily a pleural effusion or a pneumothorax.³ Demonstration or exclusion of concomitant injuries like a pneumothorax, a hemothorax, a lung contusion, or injuries to the organs of the upper abdomen are clinically more important than the detection of rib fractures. In clinically stable patients, the rib fracture itself and the concomitant injuries can be clarified by performing an ultrasound investigation.

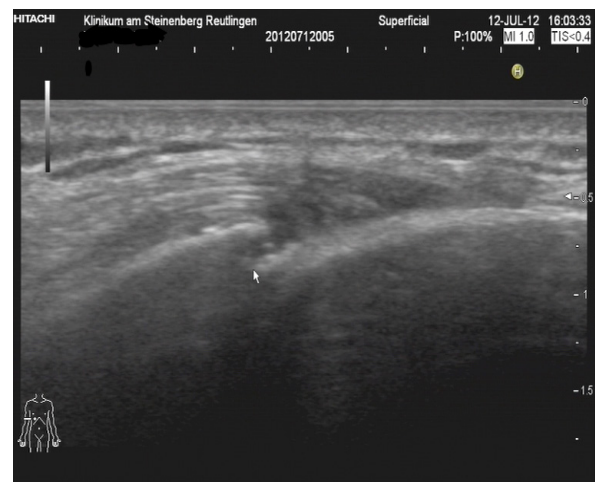


Figure 2a: The picture shows a rib fracture with a cortical step (arrow).

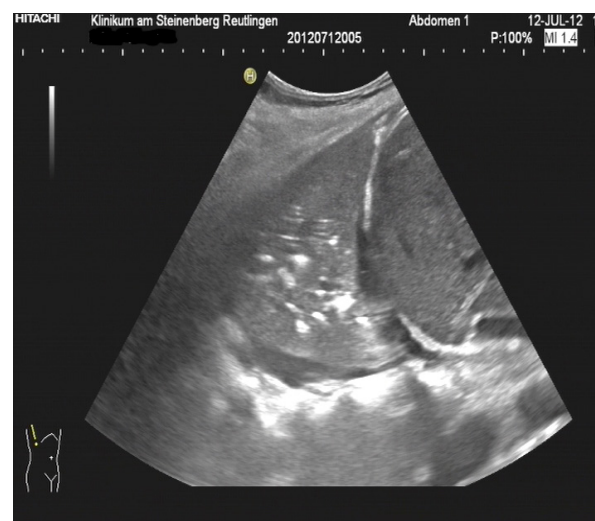

Figure 2b: As a complication a lung contusion with a liver like consolidation, a brochoaerogramm and a small pleural effusion.

Pleura

In the normal thorax the transthoracic sonographic view reaches to the pleura at the most. But only about 70% of the pleural surface can be visualized by a transthoracic approach. Fortunately most of the pathologic changes of the pleura are in this region. Pathologic changes exclusively located at the mediastinal pleura are rare.

The normal pleura is approximately 0,2 mm thick. This is within the range of the axial resolution of 0,2 mm of a 10MHz-transducer. Nevertheless, the visualization of the pleura also succeeds with a transducer with lower frequency due to the differences in the impedance between the pleura and the neighbouring layers of fat and fluid. The visceral pleura covers the aerated lung. At this interface arises a total reflection of the ultrasound, visible on the screen as a very bright line including the visceral pleura.⁴ By respiratory maneuvers the lungs move up and down. The visceral pleura slides through the intercostal field of view and thereby becomes sonographically visible. Pleural sliding is diagnostically important to prove normal conditions. Missing pleural sliding may have different causes (pneumothorax, emphysema, pleural fibrosis, apex of lung).

Pleural Effusion

Since more than 30 years ultrasound is the method of choice to clarify pleural effusion.⁴ Effusions as little as 5 ml can be identified without problems in a standing or sitting position laterodorsal in the angle between the chest wall and the diaphragm.

Color Doppler demonstrates the breath-dependent and pulse-dependent internal movement in the effusion and differentiates effusions from hypoechoic or anechoic solid lesions. Compared to CT and MRI ultrasound is the best method to detect

septations in a complicated parapneumonic effusion. Captured or septated effusions and a thickened pleura are typical signs of an increased prognostic risk.

Ultrasound is best suitable to detect effusion volume, loculation and pleural thickening. A negative bacterial culture or Gram staining and a pH > 7.20 in the aspirate mark a low risk. Aspirates with positive culture or Gram staining, purulent aspirates or a pH < 7.20 are typical for an empyema. Unilocular empyema nowadays are drained transthoracically.

Pleuritis

Breath dependant chest pain and pleural rales are typical for pleuritic. In most of these patients abnormalities of the pleura can be detected by ultrasound

Sonographical findings in pleuritis

- rough appearance and interruption of the normally smooth pleura (89,4%)
- small subpleural consolidations with a diameter between 0.2 and 2.0 cm (63,8%)
- localized parietal or basal pleural effusions (63,8%)
- CEUS: early marked contrast enhancement of the pleura
- In most cases the parietal pleura is hypoechoic to moderately echogenic thickened. The Lung Gliding Is Restricted Due To The Pain

Pleural Tumors

Primary benign and malignant pleural tumors are rare in contrast to metastases. The development of pleural metastases is often combined with pleural effusions. This acoustic window facilitates the displaying of the metastases. In most cases parietal tumors are previously detected by other imaging procedures like conventional chest-X-ray, computed tomography or magnetic resonance imaging. For further clarification a "point-of-care"- ultrasound examination is performed.

Most of the metastases are located on the pleura along the chest wall, the diaphragm and in the pleural recessus, that is in regions that are well accessible for ultrasound. Metastases are nodular, round, hemispherical or broad-based polyp-like protruding into the effusion. Metastases are, of course, of varying size and are detectable from a size of 1-2mm. Large metastases can invade deeply the underlying lung or chest wall.

In first detected and suspected, but not proved primary tumor an ultrasound guided needle biopsy may clarify the tumor diagnosis.

Pneumothorax

A pneumothorax can occur spontaneously, but also after trauma. Symptoms may be mild dyspnea to severe rapidly increasing shortness of breath in tension pneumothorax. A spontaneous pneumothorax represents often predominantly with chest pain.

The gliding sign, the synchronous up and down of the lung along the chest wall with breathing, is only visible when the lung is directly attached to the chest wall. B-lines arise in the subpleural interstitium and can only be demonstrated, when the lung is adjacent to the chest wall (Fig.3). The lung pulse, a pulsation of the lung synchronous with the heart frequency, can normally be demonstrated during real time examination with Color Doppler. The transition zone is called the lung point. The demonstration of a lung point proves a partial pneumothorax. Lung gliding, B-lines, lung pulse and lung point definitely rule in or rule out a pneumothorax⁵ (Fig 4).

Lung Consolidation

About 99% of the ultrasonic wave is reflected by the healthy lung. Intrapulmonary lung consolidations can be registered by ultrasound only when they extend to the visceral pleura or can be visualized through a sound-conducting medium such as fluid or consolidated lung tissue

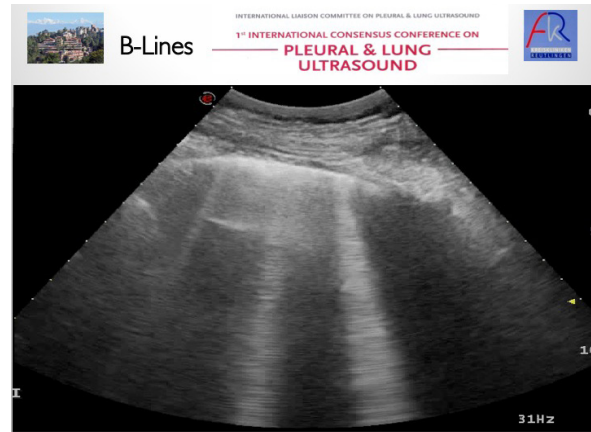


Figure 3: B- lines (2-3 are normal) are well-defined laser-like hyperechoic artifacts from the pleura, spreading down to the bottom the screen without fading, and moving synchronously with breath-dependant. The intensity, the sonomorphology and the numbers are probe-dependent. The modern US.technologies lead to artefact reduction and should be turned off for clarity. That's why we don't count them. The more B-lines the more water in the lung.

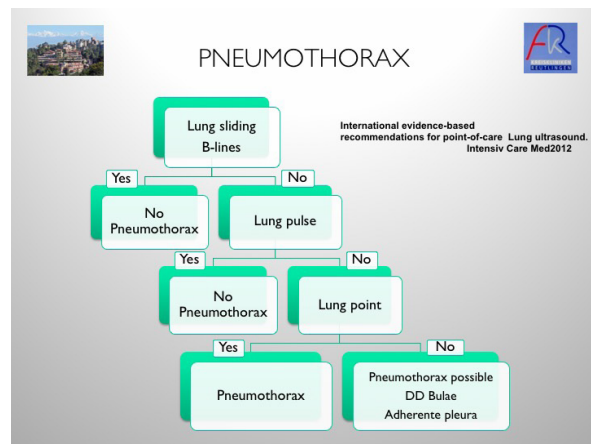


Figure 4: Pneumothorax - Diagnostic Algorithm in ultrasound.

Inflammatory conditions in Lung

Pneumonic lung infiltrations are characterized by typical changes in terms of sonomorphology:

Sonomorphology of pneumonia:

- Liver or tissue like in the early stage
- Lentil-shaped air trappings
- Bronchoaerogram in 90 %

- Fluid bronchogram (poststenotic!) in 8%
- Normal pulmonary vessels (Color Doppler)
- Blurred or serrated margins
- Reverberation echoes at the margin
- Hypoechoic to anechoic in the presence of abscess
- parapneumonic effusions

Pneumonias may be first discovered at the bedside. The extent of infiltration can be underestimated owing to artifacts on sonography. Reventilation is well correlated with clinical progression.

In Lobular and segmental pneumonia large amounts of air are displaced from the lung as a result of extensive fibrinous exudation. In this phase, pneumonia is imaged well on the sonogram (Fig 5).

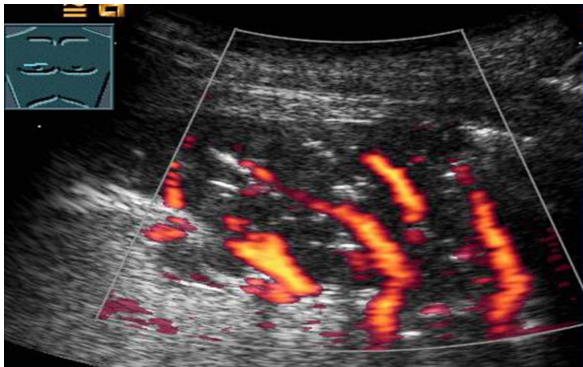


Figure 5: *Pneumonia. The picture shows all typical signs (a liver like consolidation with a bronchoaerogram and normal pulmonary vessels (CD))*

Diagnostic accuracy of LUS in Pneumonia

Primary diagnosis of pneumonia is usually performed on the basis of clinical signs and radiologic imaging, at first chest radiograph and/or CT. Several studies in adults and in children suggest that LUS could be useful for diagnosing pneumonia. The first study made in an emergency department in Nepal, Kathmandu, showed the same results.⁶

In 8 metaanalyses of LUS in CAP overall sensitivity (85-97%) and specificity (80-96%) is very high and accuracy more than 90%.⁷ Therefore, lung ultrasound is able to rule in pneumonia but not to rule it out.⁸

Tuberculosis

LUS is very limited, because it does not provide a complete overview of the chest. However, in some fields LUS can give additional information to radiographic techniques with better resolution: narrow pleural effusions, small subpleural nodules, small fluid collections in a consolidated lung, and finally better visualization of lymph nodes.

Sonomorphology of lung tuberculosis:

- Small or moderate pleural effusions (Diagnostic puncture!)
- Interrupted visceral pleural reflexion
- Pleural thickening and subpleural nodules
- Consolidations similar to pneumonia
- Caverns in consolidated lung with hyperechogenic air reflexions
- Supraclavicular and cervical lymph nodes (diagnostic puncture!)

Pneumonia: Conclusion

Based on the literature LUS has a high accuracy with more than 90% in diagnosis of community acquired pneumonia. LUS cannot rule out pneumonia. The examiner should strictly exercise the signs and sonomorphologic criteria. LUS represents an advantage over CXR in certain conditions as bedridden patients, emergency room, pregnancy, children and so on. It lacks ionizing exposure. LUS can be performed at bed side also in follow up, especially in cases with parapneumonic effusion. Other inflammatory lung diseases are less studied. In these conditions the value of LUS is limited, but it can help to plan further diagnostic strategies and imaging procedures.

Neoplastic Consolidations in the Lung: Primary Lung Tumors and Metastases

As a rule, the sonographic investigation is performed when the findings of various radiographic procedures are known.

In Ultrasound pulmonary malignancies may have a highly variable echotexture (Table 1).

In contrast to acute inflammatory infiltrations, the sonomorphology of malignant lesions does not change during a short course of disease. Decisive criteria to grade the malignant or benign nature of a pulmonary lesion are the following:

- Contours of the lung surface
- Margins to ventilated lung tissue
- Invasion of adjacent structures (chest wall, diaphragm, pericardium)
- Destruction of normal tissue architecture
- Displacement of regular vessels
- Neovascularization
- Differentiation between a central space-occupying lesion and a poststenotic invasion/atelectasis

Invasion of the Chest Wall by Bronchial Carcinoma

Owing to its high spatial resolution, ultrasonography is markedly superior to CT for evaluating an invasion of the chest wall (sensitivity 89–100 % versus 42–68 %) (Fig 6).⁹

Signs of invasion of the chest wall

Reliable signs

- Extra-organ invasion
- Rib destruction

Additional signs

- Pleural thickening
- Limited respiratory motion

Pulmonary Metastases

Pulmonary metastases are documented on sonography when they reach the margin of the lung. Owing to poor visibility in this region, sonography is not a suitable screening method. They are mostly smaller, but they look like the other malignant lesions.

Table 1: Sonomorphology of lung carcinomas

Morphology	Echotexture	Vessels	Complex structures
Sharp margins	Inhomogeneous	Displacement of vessels	Residual ventilated areas
Rounded	Hypoechoic	Destruction of vessels	Accompanying pneumonia at the margin
Polypoid	Rarely echogenic	Interruption of vessels	Solid-space-occupying lesion/pneumonia
Ramifications	Rarely anechoic	Neovascularization	Bacterial/fungal colonization
Serrated margin	Necrotic areas	-	Bizarre pattern in large necroses

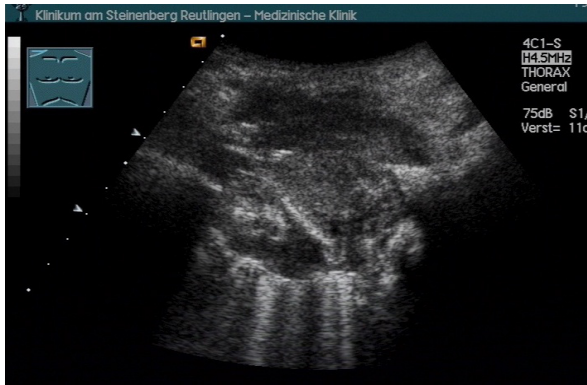

Figure 6: Pancoast tumor with a large infiltration in the chestwall and a rib destruction.

Vascular Lung Consolidations: Pulmonary Embolism and Pulmonary Infarction

Pulmonary embolism is the most frequent clinically nondiagnosed cause of death. Autopsy studies have demonstrated a frequency of 10–15%. Clinical symptoms are rare and tend to be quite harmless and unspecific. The chest X-ray is not very sensitive. Even in times of MSCT, one must assume that 40% of fatal pulmonary embolisms remain undiagnosed.

Pathophysiological Prerequisites for Sonographic Imaging of Pulmonary Embolism

A few minutes after a secondary pulmonary artery has been occluded, the surfactant collapses. Interstitial fluid and erythrocytes flow into the alveolar space. A hemorrhagic congestion offers the most ideal conditions for sonographic imaging. These consolidations are oriented towards the pleura and can be visualized with US.

The pulmonary embolism is a dynamic process. Small hemorrhages are rapidly absorbed. This small premonitory embolisms (signal embolisms) may occur before a massive or fulminant pulmonary embolism

and lead to the initiation of appropriate therapeutic measures.

Sonomorphology of Pulmonary Embolism

Peripheral pulmonary embolisms are hypoechoic and largely homogenous on ultrasound. The consolidations can be round or triangular with the base to the pleura (Fig.7). Two-thirds of lung infarctions are located dorsally in the lower lobes of the lung, more often on the right side than on the left side. The mean size of pulmonary infarctions is 12 mm × 16 mm (range 5–70 mm). Lesions less than 5 mm in size should not be taken into account because they might be merely scars. In approximately half of cases the investigator finds small pleural effusions either focally above the lesion or in the pleural sinuses.

Pulmonary infarctions and hemorrhage due to embolism are marked by the absence of circulation and the absence of contrast on contrast-assisted sonography as well as color-Doppler sonography. But only in very few cases is the investigator able to visualize, on color-coded duplex sonography, a circulation stop caused by embolism.

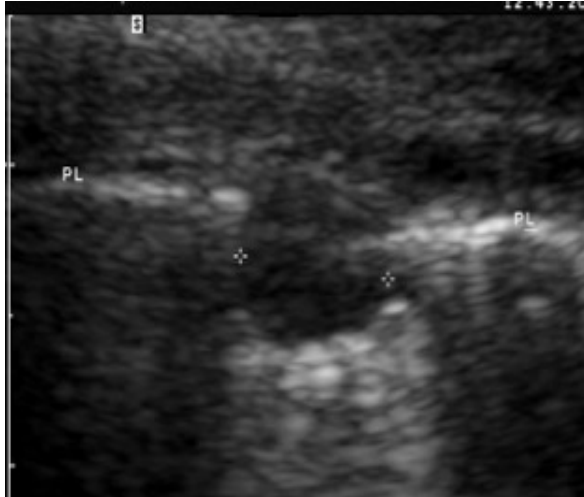
Phase of Healing—Infarction Pneumonia

Several weeks after a pulmonary embolism, the sonomorphology of the pulmonary infarction is no longer characteristic. As reventilation progresses, the sonographic image resembles that of pneumonia

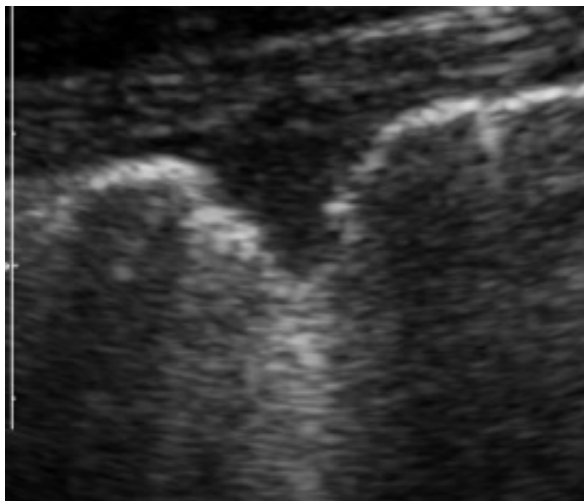
Tips on the procedure

Many patients with a pulmonary embolism report pleuritic chest pain. Others report discomfort in a specific region. The clinician first looks at the region of pain and is able to establish the cause very rapidly. When the patient does not mention a specific location, the clinician starts the investigation in the dorsobasal aspect, where the large majority of pulmonary embolisms can be seen. In cases

of continued clinical suspicion the clinician should perform an echo investigation of the entire lung, which may take several minutes. The dorsobasal region must be examined in all cases.



7a



7b

Figure 7a & 7b: Pulmonary embolism. **7a.** a round hypoechoic consolidation. **7b.** an older triangular consolidation.

Accuracy of Chest Sonography in the Diagnosis of Pulmonary Embolism

A large multicenter study comprising 352 patients in the ordinary clinical setting round the clock, which included less experienced investigators, showed that three-fourths of patients with pulmonary embolism have typical peripheral lesions on sonography.

A surprisingly high specificity of 95% was achieved in this study.¹⁰

Two recent meta-analyses of five resp 10 studies on 652/887 patients, the pooled sensitivity and specificity was 80%-87% and 82-93%. The authors conclude that, in view of the increasing numbers of CT investigations and the increasing collective radiation dose for specific clinical situations, such als emergency, pregnancy, renal failure, and contrast allergy chest ultrasound serves as a diagnostic alternative to CT. This is recommended it actual Consensus and guidelines .¹¹

Caution: A normal chest sonogram does not exclude the presence of pulmonary embolism, as is true for a negative computed tomography or a negative D-dimer test as well.

Triple-Organ-Ultrasound in Thromboembolism

In a single investigation step the experienced investigator is able to inspect several actual clinically or potentially involved regions of the body using a single imaging procedure. He/she is able to study the *source* (leg veins), *pathway*, (heart) and *target* (lung)of the embolic event.

Duplex Sonography of Leg Veins

Much more than half of pulmonary embolisms originate from leg veins. Compression sonography is a safe procedure to confirm that an embolism is originating from a deep vein thrombosis.

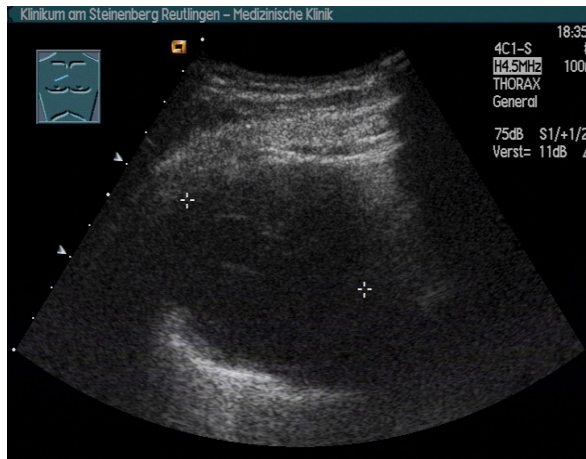
Echocardiography

About 40% of patients with acute pulmonary embolism have a right heart load.¹²

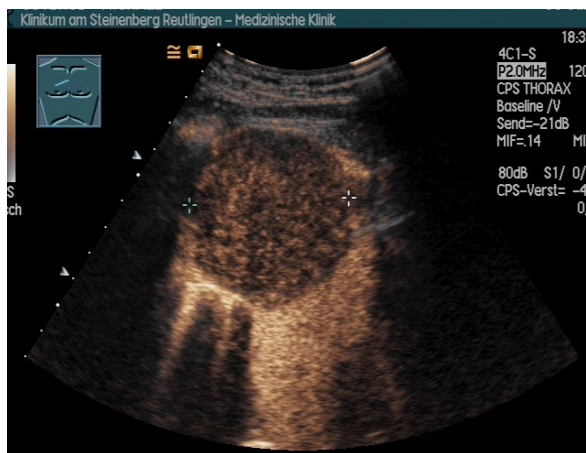
The **Triple-Organ-Ultrasound** in Thromboembolism leads to a sensitivity about 90%.

Mediastinum Transthoracal

Mediastinal space-occupying masses are most frequently found in the anterior upper mediastinum. In this region they can be evaluated with transthoracic sonography nearly as reliably as with computed tomography, and histological material can usually be easily obtained by sonography-guided puncture (Fig 8).



8a



8b

Figure 8a & 8b: Thymoma. 8a. an hypoechoic tumor in the upper mediastinum. **8b.** a intensive enhancement in CEUS (Contrast enhanced Ultrasound)

In the right- and left-sided position described by Wernecke et al.¹³ and by Brüggemann et al.¹⁴ in 1991 the mediastinum is shifted and the pulmonary cavity is displaced, which permits better viewing of the mediastinum.

In case of acute thoracic symptoms, this procedure can be implemented as a point-of-care sonography in emergency diagnosis.

The disadvantages of sonography, however, are significant. The procedure is strongly investigator dependent and only reveals portions of the mediastinum compared with computed tomography. Some of these disadvantages can be balanced by the application of endoluminal transesophageal and endobronchial sonography.¹⁵

Intervention

The cause of many diseases in chest organs can be determined by a combined evaluation of the patient's history, clinical findings and diagnostic imaging procedures.

A definitive evaluation often requires additional biochemical, microbiological, cytological or histological expert assessment. The material needed for such investigations can be obtained by targeted puncture.

Provided the indication is established with care, interventional measures in the thorax are very successful. The rate of complications is low when the procedure is performed by trained therapists.¹³

The basic principle to be applied is: “try ultrasound first”

REFERENCES

1. Cosgrove D, Piscaglia F, Bamber J et al .EFSUMB guidelines and recommendations on the clinical use of ultrasound. *Ultraschall Med* 2013;34(2):169-184. <https://doi.org/10.1055/s-0033-1335205>
2. Prosch H, Strasser G, Sonka et al. Cervical ultrasound (US) and US-guided lymph node biopsy as a routine procedure for a staging of lung cancer. *Ultraschall Med* 2007;28 (6):598–603. <https://doi.org/10.1055/s-2007-963215>

3. Turk F, Kurt AB, Saglam S .Evaluation by ultrasound of traumatic rib fracture missed by radiography. *Emerg Radiol* 2010;17 (6):473–477. <https://doi.org/10.1007/s10140-010-0892-9>
4. Reuß J. Sonographic imaging of the pleura: nearly 30 years experiences. *Eur. J Ultrasound* 1996;3(2):125-139
5. Volpicelli G .Lung sonography. *J Ultrasound Med: official journal of the American Institute of Ultrasound in Medicine J ULTRAS MED* 2013; 32 (1):165-171 <https://doi.org/10.7863/jum.2013.32.1.165>
6. Amatya Y, Rupp J, Russell F et al. Diagnostic use of lung ultrasound compared to chest radiograph for suspected pneumonia in a resource-limited setting. *Int J Emerg Med* 2018; 11:8 <https://doi.org/10.1186/s12245-018-0170-2>
7. Llamas-Alvarez AM, Tenza-Lozano EM, Latour-Perez J. Accuracy of lung ultrasound in the diagnosis of pneumonia in adults: Systematic review and meta-analysis. *Chest* 2017; 151(2):374-382 <https://doi.org/10.1016/j.chest.2016.10.039>
8. Hu QJ, Shen YC, Jia LQ et al. Diagnostic performance of lung ultrasound in the diagnosis of pneumonia: a bivariate meta-analysis. *Int J ClinExp Med* 2014; 7(1):115–121 Available from: <http://europepmc.org/articles/PMC3902248> [Accessed 2nd March 2018]
9. Bandi V, Lunn W, Ernst A, Eberhardt R, Hoffmann H, Herth FJ. Ultrasound vs CT in detecting chest wall invasion by tumor: a prospective study. *Chest* 2008;133(4):881–886. <https://doi.org/10.1378/chest.07-1656>
10. Mathis G, Blank W, Reissig A et al. Thoracic ultrasound for diagnosing pulmonary embolism. A prospective multicenter study of 352 patients. *Chest* 2005;128(3):1531–1538 <https://doi.org/10.1378/chest.128.3.1531>
11. Volpicelli G, Elbarbary M, Blaivas M et al. International Liaison Committee on Lung Ultrasound for International Consensus Conference on Lung Ultrasound. International evidence-based recommendations for point-of-care lung ultrasound. *Intensive Care Med* 2012;38 (4):577-591 <https://doi.org/10.1007/s00134-012-2513-4>
12. Konstantinides SV, Torbicki A, Agnelli G et al. 2014 ESC guidelines on the diagnosis and management of acute pulmonary embolism. *Eur Heart J* 2014;35(43):3033-3069 <https://doi.org/10.1093/eurheartj/ehu283>
13. Blank W, Annema JT, Veselić M, Rabe KF. Mediastinum. In: Mathis G.(eds) Chest Sonography. Springer, Berlin, Heidelberg 2011:p115-139 https://doi.org/10.1007/978-3-642-21247-5_5
14. Blank W, Heinzmann A, Annema JT. Mediastinum. In Mathis G.(eds) Chest Sonography .Springer ,Cham 2017:p99-122 https://doi.org/10.1007/978-3-319-44072-9_6
15. Blank W, Annema JT, Veselić M, Rabe KF. Interventional Chest Sonography. In Mathis.(eds).Chest Sonography. Springer, Berlin, Heidelberg 2011:p187-209 https://doi.org/10.1007/978-3-642-21247-5_9