

Characterization of Thyroid Nodule by Sonographic Features

Khadka H¹, Sharma S¹, Ghimire RK², Sayami G³

¹Department of Radiology, Bir Hospital(NAMS)

²Dept of Radiology,TUTH

³Dept of pathology,TUTH.

Received: January 15, 2016

Accepted: May 20, 2016

Cite this paper

Khadka H, Sharma S, Ghimire RK, Sayami G. Characterization Of Thyroid Nodule By Sonographic Features. *Nepalese Journal of Radiology* 2017;7(10):19-26.

ABSTRACT

Introduction: The thyroid is an endocrine gland situated in the infrahyoid compartment of neck in a space outlined by muscle, trachea, esophagus, carotid arteries and jugular veins. Though nodular thyroid disease is relatively common, thyroid cancer is rare and accounts for less than 1% of all malignancies indicating that overwhelming majority of thyroid nodules are benign.¹ The purpose of this study was to assess the sonographic characteristics in a solitary thyroid nodule and predict risk of malignancy.

Methods: This prospective study was conducted in a tertiary care hospital in Kathmandu. Sixty two patients with palpable thyroid nodule were evaluated for sonographic characteristics .USG guided FNA for cytopathological examination was then performed.

Results: Out of 66 patients, four were subsequently excluded because they didn't fulfill the inclusion criteria.

Of the 62 patients, 47 (75.8%) were females and 15 (24.2%) were males. Among 56 benign nodules, 45 (80.4%) were in females and 11(19.6) were in male. Among 6 malignant nodules, 4(66.7%) were in males and 2 (33.3%) were in females.

Result shows 5 malignant nodules (83.3%) were solid where as 1 malignant nodule (16.7%) was complex with solid predominance. All 4 cystic nodules (7.1%) were benign. All complex nodules with predominant cystic components were also benign.

One malignant nodule (16.7%) had snow storm type of microcalcification. None of the benign nodules had microcalcification. Nodule having microcalcification was malignant.

Findings showed that all malignant nodules (100%) had increased internal vascularity whereas benign nodules were variable in internal vascularity.

Conclusion: This study has shown that colloid goiter is the commonest benign diagnosis whereas papillary carcinoma is the commonest malignancy. Malignant nodules are solid or predominantly solid whereas cystic and predominantly cystic nodules are likely to be benign. Macrocalcification and internal vascularity are not reliable to differentiate benign from malignant nodule. However, snowstorm calcification makes a nodule likely to be malignant whereas egg shell calcification is characteristic for benign nodule.

Key words: Fine needle aspiration, Thyroid nodule, Ultrasonography

Correspondence to: Dr Hensan Khadka
Associate professor Bir Hospital(NAMS)
Email: hensankhadka@yahoo.com



Licensed under CC BY 4.0 International License which permits use, distribution and reproduction in any medium, provided the original work is properly cited

INTRODUCTION

Thyroid is an endocrine gland. It lies against C5 to T1 vertebral levels.¹ 4-7% of adult population has palpable thyroid nodule.^{2,3} Exposure to ionizing radiation increases the incidence.^{4,5} In autopsy 50% adults >60y have thyroid nodule.⁶ Thyroid cancer is however rare and accounts for less than 1% of all malignancies.⁷

About 80% of nodular thyroid disease is due to hyperplasia of the gland.⁸ Many cystic thyroid lesions are hyperplastic nodules having liquefactive degeneration. In the course, calcification, which is often coarse may occur.^{9,10} Though initially isoechoic, as the size of the mass increases, it may become hyperechoic, owing to the numerous interfaces between cells and colloid substance.^{9,11} The approximate prevalence of malignant nodule are: Papillary carcinoma 75-90%^{7,12}, Follicular carcinoma 5-15%⁷, Medullary carcinoma 5%, Lymphoma 4% and Anaplastic carcinoma <2% .¹³

Of these, papillary and follicular carcinomas have best prognosis whereas anaplastic carcinoma has worst prognosis.¹⁴ Other indicators of poor prognosis are male sex and age <20 years or >65 years.¹⁵ Papillary carcinoma is a predominant histologic type in those who had previous radiation exposure (85-90%).¹⁶ High iodine intake predisposes to papillary carcinoma but follicular carcinoma is more common in area with low iodine content.¹⁷ It has been previously thought that most papillary carcinoma of thyroid less than 10 mm in maximal diameter have low risk of metastases.^{18,19} But occult papillary carcinoma of the thyroid as small as 2 mm has been shown in some studies to have already metastasized to cervical nodes.¹⁸⁻²¹

The purpose of this study was to assess the sonographic characteristics in a solitary thyroid nodule and predict risk of malignancy.

METHODS

It was a prospective study carried out in a tertiary care hospital. Patients with solitary thyroid nodule referred for US evaluation were studied. USG of the neck was carried out with 7.5 MHZ probe. The nodules were interpreted with respect to vascularity, echostructure and calcification. Under sonographic guidance, FNA was performed by using 23 G needle with standard technique using suction aspiration and slides sent for cytological evaluation. The specific diagnosis for each case was confirmed by cytologic examinations. Statistical analysis was performed using SPSS software version 10.0 and statistical calculations were performed with Chi square, Fisher exact and independent samples t tests.

Data associations were considered statistically significant at $P < 0.005$.

RESULTS

Out of 66 patients, four were subsequently excluded because they didn't fulfill the inclusion criteria. The sonographic features of all nodules were obtained by high resolution USG and FNA was subsequently performed in all of them. Specimens were immediately sent for cytology examination. FNA was considered gold standard.

Of the 62 patients, 47 (75.8%) were females and 15 (24.2%) were males. Among 56 benign nodules, 45 (80.4%) were in Females and 11(19.6) were in male. Among 6 malignant nodules, 4(66.7%) were in males and 2 (33.3%) were in females.

Result shows 5 malignant nodules (83.3%) were solid whereas 1 malignant nodule (16.7%) was complex with solid predominance. All 4 cystic nodules (7.1%) were benign. All complex nodules with predominant cystic components were also benign.

One malignant nodule (16.7%) had snow storm type of microcalcification. None of the benign

nodules had microcalcification. Nodule having microcalcification was malignant.

whereas benign nodules were variable in internal vascularity.

Findings showed that all malignant nodules (100%) had increased internal vascularity

Hence, validity of these parameters was tested and the results are given below:

Table 1: Distribution Of Internal Vascularity In Benign Vs Malignant Nodules

		Tumour type		Total
		Benign	Malignant	
Internal vascularity	Nil	27		27
		48.2%		43.5%
	<25%	20	6	26
		35.7%	100.0%	41.9%
	26-50%	7		7
		12.5%		11.3%
	51-75%	2		2
		3.6%		3.2%
Total		56	6	62
		100.0%	100.0%	100.0%

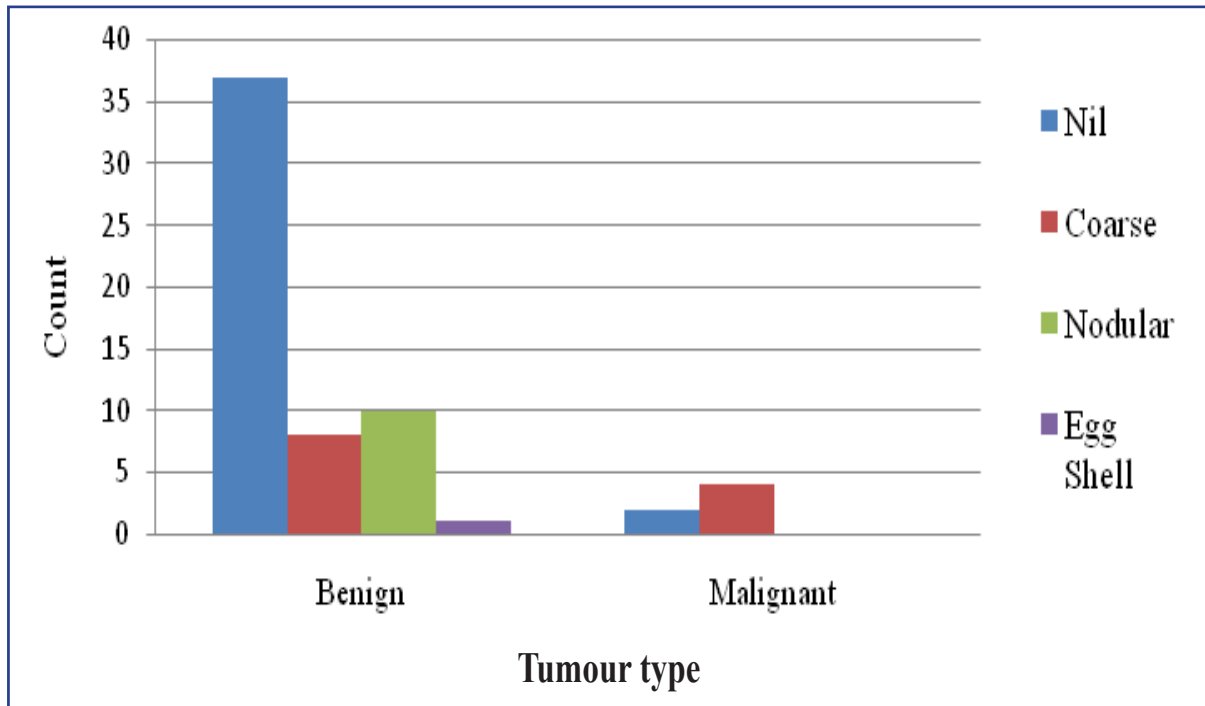


Figure 1: Distribution Of Macrocalcification In Benign Vs Malignant Nodules

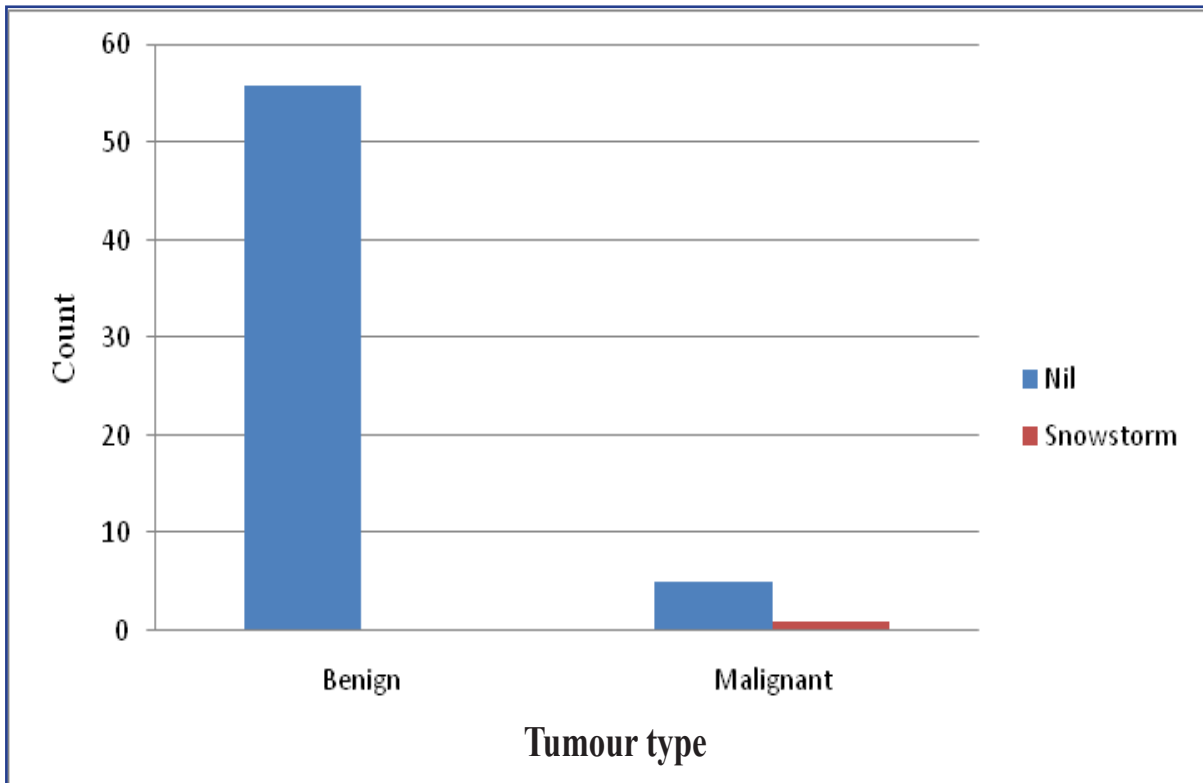


Figure 2: Distribution Of Microcalcification In Benign Vs Malignant Nodules

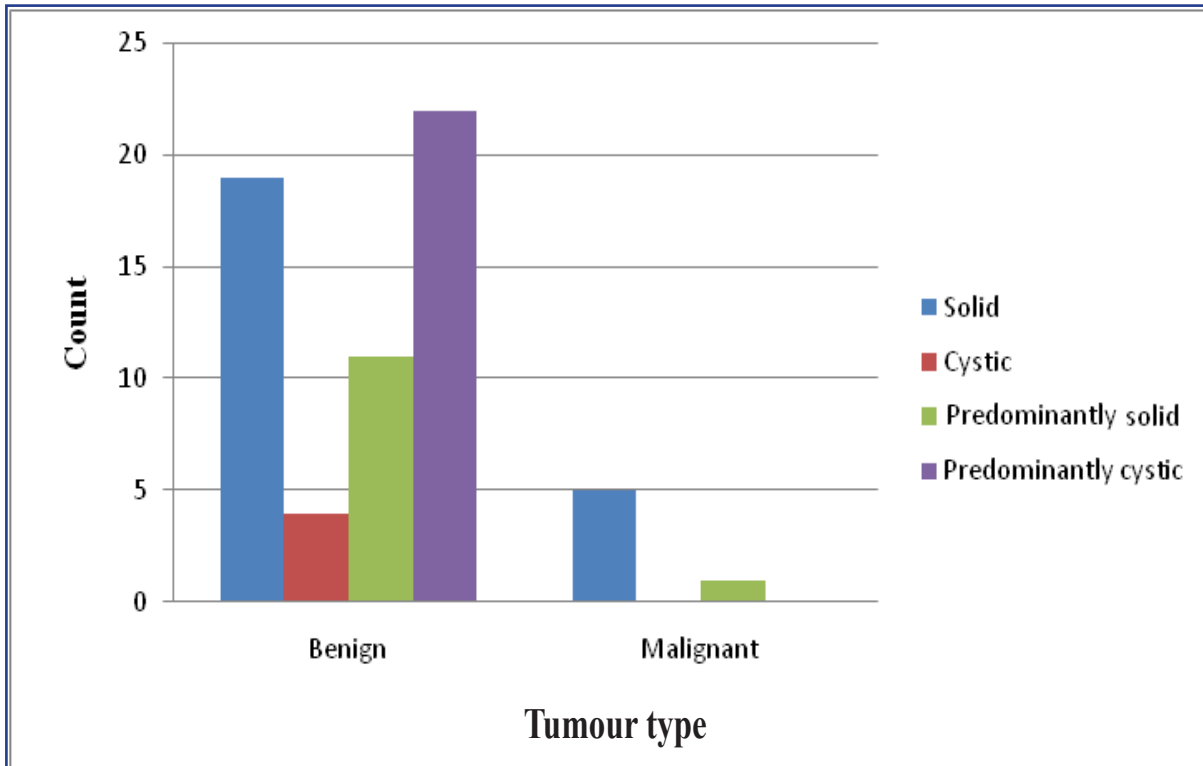


Figure 3: Distribution Of Internal Echotexture In Benign Vs Malignant Nodules

Table 2: FNAC Diagnosis

Diagnosis	F r e - quency	P e r - cent
Colloid goiter	50	75.8
Nodular goiter	4	6.1
Papillary carcinoma	5	7.6
Suspicious malignancy	1	1.5
Acute thyroiditis	1	1.5
Abscess	1	1.5
Follicular carcinoma	1	1.5
Follicular adenoma	1	1.5
Dequervain's thyroiditis	1	1.5
No definite opinion	1	1.5
Total	66	100.0

DISCUSSION

Evaluation of thyroid nodule frequently involves a stepwise performance of clinical evaluation to several imaging techniques. The use of USG in the assessment of nodular thyroid disease has greatly increased the detection rate of small thyroid nodules.²⁰ Evaluation of thyroid nodule by FNA has been the gold standard. The overall accuracy of FNA exceeds 95%, therefore it is currently the most accurate and cost effective method for initial evaluation of nodular thyroid disease. As thyroid nodule is shown by USG in 30-50% of general population and less than 5-6.5% of these are malignant²⁰, subjecting every patient with thyroid nodule to invasive procedure (FNA) would be a costlier venture. Evaluation of thyroid nodule primarily by FNA is common in North America and Northern Europe. In other European countries and Japan where goiter has a very high prevalence, the initial evaluation relies on radionuclide and sonographic imaging, owing to the need to select those nodules that must undergo FNA.¹

In this study 66 patients from different parts of the country were studied by their sonographic characteristics including color Doppler. Four patients were subsequently excluded making total cases of 62 for further analysis. Each characteristic was evaluated individually

and in combination to determine sensitivity, specificity, positive predictive value and negative predictive value in a malignant nodule. They were then subjected for FNA. Specimen was immediately sent for cytopathologic study.

Out of 62, 56 nodules (90.4 %) were benign and 6 nodules (9.6%) were malignant.

The prevalence of malignant nodule in this study resembles to the prevalence as shown by the study of Enrico papini et al²⁰(9.2%). 47 (75.8%) were female and 15 (24.2%) were male. Among 56 benign nodules, 45 (80.4%) were in females and 11(19.6) were in male. Among 6 malignant nodules, 4(66.7%) were in males and 2 (33.3%) were in females.

The mean size of benign and malignant nodules was 3.04 cm (SD 1.29) and 3.00 cm (SD 0.89) respectively with no significant difference. The largest size group was 2-3cm in benign nodules (23, 41.1%). Malignant nodules had the size range of 1-4 cm.

The mean age of patient with benign and malignant nodules was 47.93 years (SD 13.15) and 48.06 years (SD 13.09) with no significant difference.

The most common benign nodule was colloid goiter (50 of 56, 89.2%) with or without degeneration and most common malignant nodule was papillary carcinoma,(5 of 6, 83.3%). These figures resemble to the prevalence of 80% of colloid goiter. The prevalence of papillary carcinoma also closely resembles to the general prevalence of papillary carcinoma of 75%-90% .^{7,12}

In this study the sonographic characteristics of the nodule were studied according to internal echostructure (solid, cystic, predominantly solid and predominantly cystic), presence or absence of calcification (macrocalcification and microcalcification) and intranodular vascularity (no color flow,<25%, 26-50%, 51-75% and >75%). The cytopathologic finding was regarded as either benign or malignant.

EVALUATION OF ECHOSTRUCTURE

In this study 5 malignant nodules (83.3%) were solid whereas 1 malignant nodule(16.7%) was complex with solid predominance.

Solid echostructure as a single parameter, had sensitivity, specificity, positive predictive value and negative predictive value of 83.3%, 66.1%, 20.8% and 97.4% respectively to predict malignancy, with P value of 0.028 but after performing binomial logistic regression analysis P value increased to 0.135. This result is close to the study by Enrico papini et al²⁰ which showed 87% of the malignant nodules which were solid and hypoechoic.

Study by Jason D.Janniculi et al²² showed most of the malignant nodules were predominantly solid (85.3%) or mostly solid with cystic regions (11.8%).

This result contradicts to the study performed by Mary C.Frates et al²³ which showed 13 of 32 malignant nodules (40.1%) to be solid. All the 4 cystic nodules (7.1%) were benign. All nodules with predominantly cystic components were also benign (P-value: 0.101).

EVALUATION OF CALCIFICATION

This study showed that none of the benign nodules had microcalcification.1 malignant nodule (16.7%) had snow storm type of microcalcification. Nodule having microcalcification was malignant (P-value: 0.097). However this result was statistically insignificant. Eighteen benign nodules (32.2%) and 4 malignant nodules (66.7%) had macrocalcification. All macrocalcification in malignant nodules were coarse. Macrocalcification was not present in 37 benign nodules (66.1%) and 2 malignant nodules (33.3%). So 5 of 6 (83.4%) malignant nodules had calcification. Taking coarse macrocalcification as a single parameter, it had sensitivity, specificity, positive predictive value and negative predictive value of 66.7%, 85.8%, 33.3% and 100% respectively to predict

malignancy with P value of 0.011. But after binomial logistic regression analysis, P value was 0.051. Snow storm microcalcification as a single parameter to predict malignancy, it had sensitivity, specificity, positive predictive value and negative predictive value of 83.3%, 100%, 100% and 91.8% respectively but the result was statistically insignificant with P value of 0.097 and 0.189 without and with binomial logistic regression analysis respectively.

Study by Jason D. Janniculi et al²² showed calcification in 12(35.3%) of 34 malignant nodules of which 5(41.7%) of 12 calcified malignant nodules had snow storm type of calcification which was present in 1(20%) of 5 calcified malignant nodules in present study.

The study by Enrico papini et al²⁰ showed that presence of microcalcification had the highest specificity for malignancy (95%).But it had very low sensitivity (29.0%).

EVALUATION OF INTERNAL VASCULARITY

In this study all 6 malignant nodules (100%) had internal vascularity which was <25%(grade I). whereas benign nodules were variable in internal vascularity. Twenty seven benign nodules(48.2%) had no vascularity. Two benign nodules(3.6%) had 51-75% internal vascularity.7 of the 56 benign nodules(12.5%) had vascularity of grade II (26-50%). 20 benign nodules(35.7%) had internal vascularity of grade I (<25%).P-value: 0.027.

As a single parameter to predict malignancy, internal vascularity of grade I had sensitivity, specificity, positive predictive value and negative predictive value of 100%,64.3%,23.1% and 100% respectively with P value of 0.004. However after binomial logistic regressin analysis, P value was 1.000.

Many studies in the past showed that greater the degree of internal vascularity, the more the likelihood of malignancy. However study carried out by Jason D. Janniculi et al²² showed that the increased internal vascularity was

more common in benign nodules than in malignant nodules. In their study, 3 of 36 (8.3%) benign nodules showed internal vascularity >75% (grade 4), none of the malignant nodules in their study showed internal vascular flow >50%. Only 20.6% malignant nodules showed internal vascular flow >25%. 69.4% of benign and 64.7% of malignant nodules showed no internal vascular flow. The sensitivity and specificity of intranodular vascularity were 80.8% and 74.2% respectively.

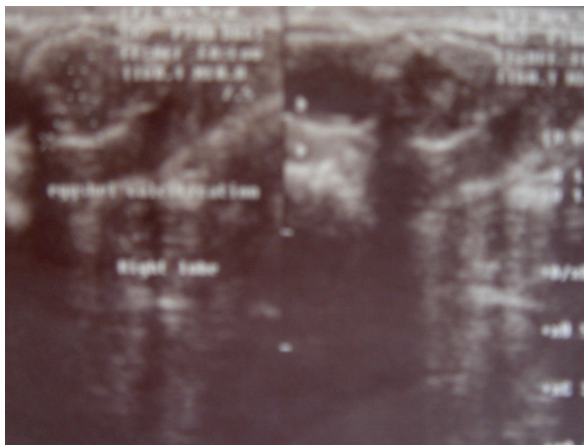


Figure 4: A solitary thyroid nodule with well-defined margin and eggshell calcification, a case of benign nodule

CONCLUSION

This study has shown that colloid goiter is the commonest benign diagnosis whereas papillary carcinoma is the commonest malignancy. Malignant nodules are solid or predominantly solid whereas cystic and predominantly cystic nodules are likely to be benign. Macrocalcification is not helpful to differentiate benign from malignant nodule. However snowstorm calcification makes a nodule likely to be malignant whereas egg shell calcification is characteristic for benign nodule.

CONFLICT OF INTEREST

None

SOURCES OF FUNDING

None

REFERENCES

1. Solbiati L, Charboneau JW, Osti V, James EM, Hay ID. The Thyroid Gland. In: Rumack CM, Wilson SR, Charboneau JW, editors. Diagnostic Ultrasound, 3rd edition. St Louis, Elsevier Mosby. volume 1, 2005:p735-770.
2. Rojeski MT, Gharib H. Nodular thyroid disease: Evaluation and management. *N Engl J Med* 1985;313:428-436. <https://doi.org/10.1056/NEJM198508153130707>
3. Van Herle AJ, Rich P, Ljung B-ME et al. The thyroid nodule. *Ann Intern Med* 1992;96:221-232. <https://doi.org/10.7326/0003-4819-96-2-221>
4. Favus MJ, Schneider AB, Stachura ME, et al. Thyroid cancer occurring as a late consequence of head-and-neck irradiation: Evaluation of 1056 patients. *N Engl J Med* 1976;294:1019-1025. <https://doi.org/10.1056/NEJM197605062941901>
5. Degroot LJ, Reily M, Pinnamenni K, et al. Retrospective and prospective study of radiation-induced thyroid disease. *Am J Med* 1983;74:852-862 [https://doi.org/10.1016/0002-9343\(83\)91077-X](https://doi.org/10.1016/0002-9343(83)91077-X)
6. Hegedüs L. The Thyroid Nodule. *N Engl J Med* 2004; 351:1764-1771. <https://doi.org/10.1056/NEJMcp031436>
7. Grebe SKG, Hay ID. Follicular cell-derived thyroid carcinoma. *Cancer treat Res* 1997; 89:91-140. https://doi.org/10.1007/978-1-4615-6355-6_6
8. Hennemann G. Non-toxic goiter. *Clin Endocrinol Metab* 1979; 8:167-179. [https://doi.org/10.1016/S0300-595X\(79\)80015-8](https://doi.org/10.1016/S0300-595X(79)80015-8)

9. Kerr L. High-resolution thyroid ultrasound: the value of color Doppler. *Ultrasound Q* 1994; 12:21-43. <https://doi.org/10.1097/00013644-199412010-00002>
10. Solbiati L, Cioffi V, Ballarati E. Ultrasonography of the neck. *Radiol Clin North Am* 1992;30:941-954. Available from: <https://www.ncbi.nlm.nih.gov/pubmed/1518938> [Accessed 21st Dec 2015].
11. Muller HW, Schroder S, Schneider C et al. Sonographic tissue characterization in thyroid gland diagnosis. *Klin Wochenschr* 1985;63:706-710. <https://doi.org/10.1007/BF01733114>
12. Schlumberger M-J,Filetti S, Hay ID. In: Nontoxic goiter and thyroid neoplasia. Larsen PR,Kronenberg HM,Melmed S,et al. (eds):Williams Textbook of Endocrinology,10th ed.Philadelphia,WB Saunders 2003:p 457-490.
13. Nel CJ,van Heerden JA,Goellner JR,James EM,et al. Anaplastic carcinoma of the thyroid :A clinicopathologic study of 82 cases. *Mayo Clin Proc* 1985; 60(1):51-58. [https://doi.org/10.1016/S0025-6196\(12\)65285-9](https://doi.org/10.1016/S0025-6196(12)65285-9)
14. Kumar V,Cotran RS, Robbins SL. Diseases of the endocrine system, Basic Pathology.5th edition, W.B Saunders Company1992:p 643-680.
15. Jameson JL,Weetman AP. Disorders of the thyroid gland. In: Braunwald E,Fauci AS,Kasper DL,Hauser SL, Longo DL, Jameson JL,editors.Harrison's Principles of internal medicine,15th edition. Mc Graw Hill. Volume 2 2003:p 2063-2081.
16. Sadlor GP, Clarj OH.Vanherden JA, Farley DR. Thyroid and parathyroid. In: Schwartz SI, Shires GT, Spencer FC, DalyJM, Fischer JE and Halloway AC, editors.Principles of Surgery.7th edition. Mc Graw Hill:p1661-1713.
17. Dudley N. The thyroid gland. In: Peter J Morris PJ. Malt DA,editors. Oxford Text Book of Surgery, International edition, Oxford University Press, volume 1, p731-754.
18. Harach HR, Franssila KO, Wasenius V. Occult papillary carcinoma of the thyroid: a "normal" finding in Finland. *Cancer* 1985; 56:531-538. [https://doi.org/10.1002/1097-0142\(19850801\)56:3<531::AID-CNCR2820560321>3.0.CO;2-3](https://doi.org/10.1002/1097-0142(19850801)56:3<531::AID-CNCR2820560321>3.0.CO;2-3)
19. Monchick JM, De Petris G, De Crea C. Occult papillary carcinoma of the thyroid presenting as cervical cyst. *Surgery* 2001;129:429-432. [https://doi.org/10.1016/S0039-6060\(01\)60495-1](https://doi.org/10.1016/S0039-6060(01)60495-1)
20. Papini E, Guglielmi R, Bianchini A, et al. Risk of malignancy in nonpalpable thyroid nodules: predictive value of ultrasound and color-Doppler features. *J Clin Endocrinol Metab* 2002; 87:1941-1946. <https://doi.org/10.1210/jcem.87.5.8504>
21. Kim E, Park CS, Chung WY, et al. New sonographic criteria for recommending fine-needle aspiration biopsy of non-palpable solid nodules of the thyroid. *AJR Am J Roentgenol* 2002; 178:687-691. <https://doi.org/10.2214/ajr.178.3.1780687>
22. Iannuccilli JD, Cronan JJ, and Monchik JM. Risk for Malignancy of Thyroid Nodules as Assessed by Sonographic Criteria: The need for biopsy. *J Ultrasound Med* 2004; 23(11):1455-1464. <https://doi.org/10.7863/jum.2004.23.11.1455>
23. Frates MC, Benson CB, Doubilet PM et al. Prevalence and Distribution of Carcinoma in Patients with Solitary and Multiple Thyroid Nodules on Sonography. *J Clin Endocrinol Metab* 2006 Sep; 91(9):3411-17. <https://doi.org/10.1210/jc.2006-0690>