

Huge Subserosal Leiomyoma fed by serpentine omental blood vessels

Suvana Maskey, Geeta Gurung, Josie Baral, Pooja Paudyal

Department of Obstetrics and Gynaecology, Tribhuvan University Teaching Hospital, Kathmandu

Received: May 5, 2020

Accepted: August 16, 2020

ABSTRACT

Leiomyoma is considered the most common benign tumor of genital tract with variable presentation and diverse operative findings. We are presenting a case of asymptomatic huge subserosal pedunculated leiomyoma in a 37 years unmarried nullipara lady diagnosed as highly vascular abdominopelvic mass preoperatively as suggested by imaging studies but of uncertain origin, imposing surgical challenge due to diagnostic dilemma and its vascularity. Laparotomy revealed solid mass of 26 x 24 cm occupying whole abdomen covered with torturous dilated serpentine vessels derived from omentum. The mass was arising from the fundus of bulky uterus with small pedicle suggesting subserosal pedunculated leiomyoma. Myomectomy with infracolic omentectomy with round ligament plication was done and her post operative recovery was smooth. Histological examination confirmed it as leiomyoma.

Keywords: Omentum, Pedunculated Leiomyoma, Serpentine

Citation: Maskey S, Gurung G, Baral J, Paudyal P. Huge Subserosal Leiomyoma fed by serpentine omental blood vessels. Nep J Obstet Gynecol. 2020;15(31):124–126. DOI: <https://doi.org/10.3126/njog.v15i2.32926>

INTRODUCTION

Leiomyoma is the most common benign tumour of female genital tract. Uterine leiomyomas are classified according to their location as intramural, subserosal or submucosal.¹ Among these subserosal leiomyomas are usually asymptomatic and sometimes may attain huge size without the patient being aware of it. When the leiomyoma outgrows its vascular supply from uterus it may derive its blood supply from adjacent structures such as omentum.^{2,3} The following is the case report of nulliparous woman with huge asymptomatic pedunculated subserosal leiomyoma covered with torturous dilated serpentine vessels derived from omentum suggesting its blood supply from omentum. Despite the diagnostic dilemma and surgical challenge due to abundant tortuous vessels of uncertain origin it was managed successfully.

CASE

A 37years old lady presented to Gynae OPD with complain of incidental finding of abdominal mass on examination detected by physician while doing evaluation for hand tremors. She was told to have firm to hard mass occupying whole abdomen. She

didn't give history of menstrual abnormalities, dysmenorrhoea, gastrointestinal symptom or urinary symptom. However she gave history of weight gain since 7 months. She was unmarried and sexually inactive. Examination of abdomen revealed huge mass corresponding to 30 weeks of gravid uterus measuring approximately 30x32 cm with regular margin, irregular surface, firm to hard in consistency, restricted mobility and non tender. Her hemoglobin was 15.7gm/dl, ovarian tumor markers and rest preoperative investigations were normal. Ultrasonography along with doppler showed large heterogeneously hypoechoic lesion measuring 17.6 x 17.4 x 11.2 cm occupying central part of abdomen with significant vascularity with bilateral mild hydronephrosis. MRI revealed 19.5 x 18.6 x 11.1 cm large lobulated T2 heterogenous signal intensity abdominopelvic mass, probably left ovarian sex cord stromal tumor with differential diagnosis of huge pedunculated leiomyoma. As the imaging studies showed large tortuous vessels along with the mass CT angiography was done which demonstrated anonymous branches of superior mesenteric artery with multiple collateral vessels and multiple

CORRESPONDENCE

Dr Suvana Maskey
Department of Obstetrics and Gynaecology, TUTH,
Kathmandu, Nepal
Email: suvanashrestha@yahoo.com; Mobile: +977-9851139574

feeders supplying the mass likely from the inferior pancreaticoduodenal and right colic artery [Fig-1].

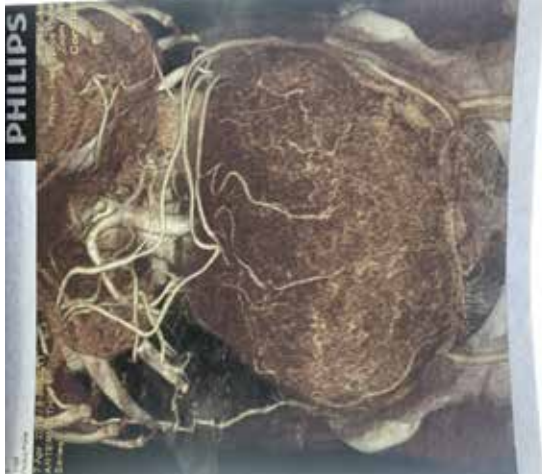

Figure-1: CT angiography showing mass with anonymous branches of superior mesenteric artery with multiple collateral vessels and multiple feeders supplying the mass.

In view of vascular mass of uncertain origin laparotomy was performed keeping vascular surgeons standby if needed. On opening abdomen it revealed abundant torturous dilated serpentine vessels running over omentum which was adhered to anterior surface of the mass and on further exploration solid mass of 26 x 24 cm occupying whole abdomen was present [Fig-2].

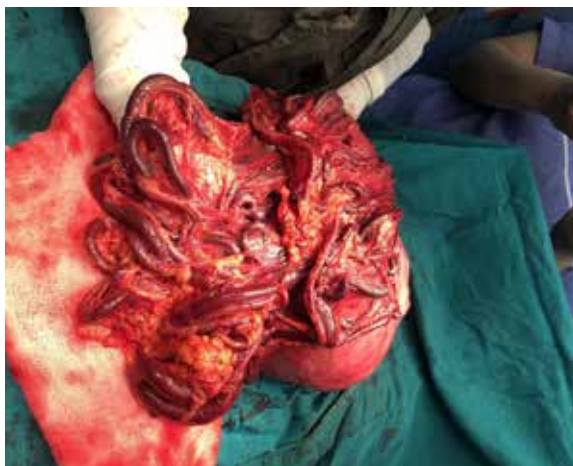

Figure-2: Mass of 26 x 24 cm torturous dilated serpentine vessels running over omentum anterior to the mass

Omentum was adhered to the anterior surface of the mass and blood vessels were derived from omentum suggesting its blood supply from it. Mass was arising from the fundus of bulky uterus with small avascular pedicle thus was subserosal in nature. Three buddings of 3x3 cm noted in posterior surface of mass [Fig-3].

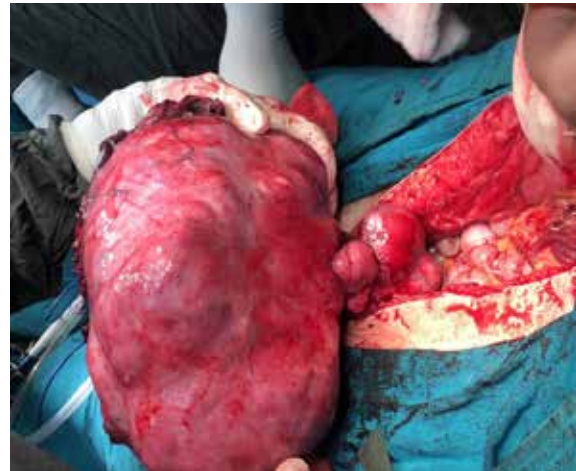

Figure-3: Subserosal myoma arising from the fundus of uterus with small avascular pedicle with three buddings of 3x3 cm in posterior surface of mass.

Bilateral tubes and ovaries were normal. After meticulous clamping, tying and cutting of the vasculatures obvious regression of size of the mass was observed. It was followed by infracolic omentectomy then myomectomy with round ligament plication was performed. The leiomyoma weighed 5.6 kg. Her post operative recovery was smooth and was discharged on 4th post operative day. Histological examination confirmed it as leiomyoma [Fig-4].




Figure-4: Microscopic picture showing interlacing fascicles of smooth muscles (A-10x, B-40x)

COMMENT

Leiomyoma is the most common benign tumour of uterus seen in 20- 30% of women older than 35 years.^{3,4} Symptoms depend on location, number and size of myoma though many are asymptomatic and detected incidentally especially in those with subserosal leiomyoma.¹ Leiomyoma, if not treated, can continue to grow to enormous size with or without any symptom like in the present case where the subserosal leiomyoma was incidentally detected

while doing evaluation for other problem. When the leiomyoma outgrows its vascular supply from uterus it may derive its blood supply from adjacent structures such as omentum, common iliac artery and inferior mesenteric artery.^{2,3,5} The uterine pedicle if disappears completely or becomes avascular the resultant tumor is known as “parasitic leiomyoma”.²⁻⁶

Ultrasonography is the first line investigation and usually is sufficient for diagnosis but additional imaging with MRI is sometimes needed if there is diagnostic dilemma. It helps in differentiating leiomyoma from solid adnexal mass, as in the present case, which can happen if the leiomyoma is large or pedunculated subserosal and away from uterus.^{1,7} In this case we had also done CT angiography to delineate the abnormal vasculature seen in Doppler ultrasonography. Different modalities of treatment are available depending upon the size and location of leiomyomas, the patient’s age, symptoms and desire to preserve fertility, but surgical resection is the treatment of choice in such huge leiomyoma thus myomectomy was done considering her age and marital status.^{1,6} During laparotomy huge leiomyoma was present with torturous dilated serpentine vessels coming from omentum and attached to uterine fundus with small pedicle thus suggesting that the tumor was acquiring blood supply predominantly from omental vessels. The large serpentine vessels

arising from adherent omentum presented surgical challenge requiring meticulous clamping and separation of the vasculature along with infracolic omentectomy before performing myomectomy. Such leiomyoma with tortuous massive vascularity from other structure is quite rare with true incidence not known till now though few similar cases have been reported by others.^{2,3,6} Ahmed S Elagwany and associates reported similar case of multi-lobulated leiomyoma attached to the fundus of the uterus by a thin avascular stalk which derived its blood supply from the greater omentum with a huge serpentine and spider shaped blood vessels.² Similarly in another case report also there was large irregular leiomyoma connected with the anterior uterine wall with a small pedicle and the large nutritive vascular omental pedicle on the surface of the tumor.³

CONCLUSIONS

Though uterine leiomyoma is the most common benign tumour of the uterus we may encounter such rare case of huge leiomyoma with enormous serpentine vascularity putting in diagnostic dilemma preoperatively. Proper preoperative evaluation, surgical plan and meticulous surgical approach are required to avoid possible complications and to achieve successful management.

REFERENCES

1. De La Cruz MS, Buchanan EM. Uterine fibroid tumors: Diagnosis and Treatment. *Am Fam Physician*. 2017;95(2):100-7.
2. Elagwany AS, Rady HA, Abdeldayem TM. A case of parasitic leiomyoma with serpentine omental blood vessels: An unusual variant of uterine leiomyoma. *J Taibah Univ Med Sc*. 2014; 9(4):338-40.
3. Elsayed MA. Primary parasitic myoma in a young virgin. *Middle East Fertil Soc J*. 2015;20:213-5.
4. Sreelatha S. A rare case of primary parasitic leiomyoma. *Int J Reprod Contracept Obstet Gynecol*. 2013;2(3):422-4.
5. Kanthikar SN, Shejwal DK, Nikumbh DB, Bagale PS, Rokade CM. Parasitic Leiomyoma: A Diagnostics Dilemma - A Case Report. *Int J Med Health Sci*. 2014;3(4):347-9.
6. Aksoy AN, Erdem EB, Sarıkas GT, Telli E. A Large Uterine Leiomyoma with Hypertrophied Omental Vessels: A Case Report. *Obstet Gynecol Cases Rev*. 2019;6:143.
7. Wilde S, Scott-Barrett S. Radiological appearances of uterine fibroids. *Indian J radiol Imaging*. 2009;19(3):222-31.