

Ovarian Adult Granulosa Cell Tumor – a rare case report

Joshi R¹, Baral G¹, Malla K¹

¹Paropakar Maternity and Women's Hospital, Kathmandu, Nepal

Received: 2 Mar 2018; Accepted: 30 Apr 2018

Introduction: Adult granulosa cell tumor is a rare tumor which accounts for 1% of all ovarian tumors. They usually present with postmenopausal bleeding and abdominal mass. Inhibin is used as the tumor marker.

Case: A 76 years multiparous post-menopausal women presented with vaginal bleeding for past three years and painless huge mass in lower abdomen. She underwent total abdominal hysterectomy with bilateral salphingo-oophorectomy with bilateral pelvic lymphnode dissection with appendectomy. Histopathology showed the adult granulosa cell tumor with few mitosis, Stage IA. Her postoperative period was uneventful.

Conclusion: Surgery is the mainstay of treatment of granulosa cell tumor and chemotherapy is indicated in advanced cases. Although they have better prognosis, life-long follow up is advised to detect late recurrence.

Keywords: granulosa cell tumor, inhibin, ovarian tumor.

<http://dx.doi.org/10.3126/njog.v13i1.21621>

INTRODUCTION

Ovarian sex-cord stromal tumors are rare hormone producing tumors.¹ It comprises of tumors arising from the variety of cells from the gonadal sex cords (granulosa cells, theca cells, stertoli cells) or stromal cells.^{1,2} Granulosa cell tumors (GCT) consist of granulosa cells often mixed with a variable number of fibroblasts and theca cells. Among the two distinct clinical and histological sub-types, adult GCT are more common (95%) than the juvenile counterpart (5%).^{1,3} The adult type are common in middle aged and in postmenopausal women while the juvenile type is common in young age and children.^{4,5} Adult GCT account for approximately 1% of all ovarian tumours.⁴ They typically present with postmenopausal bleeding in older women while 10% may present with acute abdominal symptoms. They are often diagnosed on the histopathological examination following surgery.^{1,2}

CASE

A 76 years multiparous post-menopausal lady presented to outpatient department of Paropakar Maternity and Women's Hospital with complaints of irregular and excessive per vaginal bleeding for past three years and painless mass in lower abdomen noticed since 2 months. She had attained menopause

at the age of 50 years. On clinical examination, she was thin built with weight of 41 kg. A non-tender mobile cystic mass of 26 cm x 20 cm with smooth surface and regular margin was palpable in the lower abdomen. Fresh bleeding was noted from the endocervical region and cervix was flushed with the vagina.

In ultrasound examination there was a large heterogenous intrapelvic lesion with multiple thin septa with solid component with increased vascular flow in left adnexa. Contrast enhanced CT scan of abdomen and pelvis showed extensively enlarged multilocular cystic mass of 21 x 15 x 9 cm at left adnexa with variable thickness of cyst wall and septations with solid component. Uterus was normal in size with endometrial thickness of 7 mm. Tumor marker (CEA, α -FP, LDH, β -hCG) were within normal range except for CA-125 which was double than normal (78 IU/ml).

Staging laparotomy with total abdominal hysterectomy with bilateral salphingo-oophorectomy with bilateral pelvic lymphnode dissection with appendectomy was done on 13/06/2018. Hemorrhagic peritoneal fluid of 50 ml was noted on opening of abdomen. Left ovarian cystic mass of around 25x 25 cm was seen with intact capsule and smooth surface. Uterus, fallopian tubes and right ovary were normal. There were no gross tumor deposits inside the abdomen. On cut section, cyst wall was thick; multiple loculi with thick and thin septa were present; most of the loculi had hemorrhagic fluid while some loculi had

CORRESPONDENCE

Dr Rijuta Joshi
Paropakar Maternity and Women's Hospital, Kathmandu
Email: dr.rijutajoshih@yaho.com;
Phone: +977-9851151830

clear fluid (total fluid-1500 ml); solid component of around 5x5 cm was also seen [Figure-1, 2 and 3]. Her post-operative period was uneventful and she was discharged from the hospital on 12th post operative day.

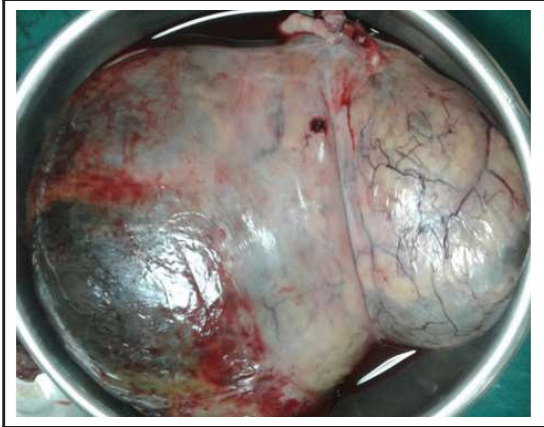

Figure-1: Gross specimen of left ovarian tumor

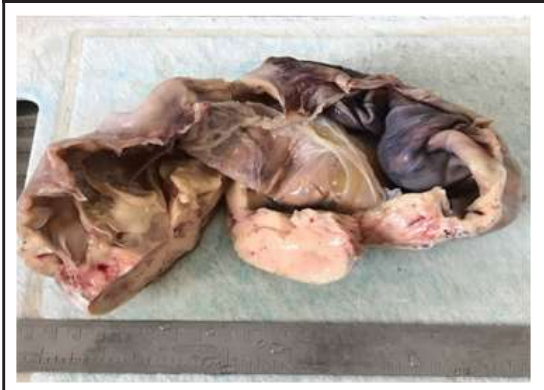
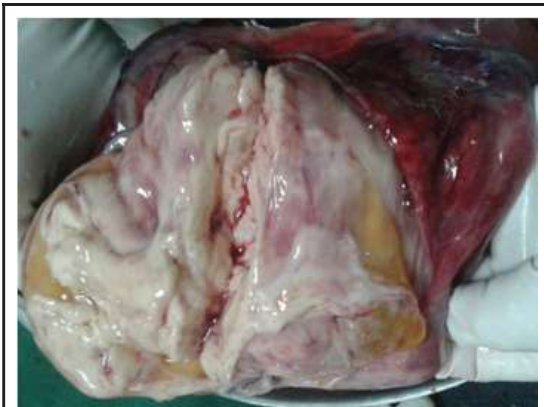
Figure-2 & 3: Cut section of tumor showing the solid component

Histopathological examination showed tumor cells arranged predominantly in inter-anastomosing trabeculae of ribbon, cords and sheets while few cells were arranged in micro-follicular pattern. The tumor cells were forming microcystic spaces containing

eosinophilic secretions. The individual tumor cells were uniform with round to oval nuclei with single small nucleoli, longitudinal grooves and pale cytoplasm with few mitoses (0-2/10 HPF). Peritoneal fluid and pelvic lymphnodes were negative for malignant cells (0/10). There was no lymphovascular and perineural invasion. The histopathological diagnosis was pure sex-cord tumor – adult granulosa cell tumor, Stage IA [Figure-4 and 5]. Serum inhibin was done on 14th post operative day which was 0.80 pg/ml (inhibin level for postmenopausal age <2.1 pg/ml).

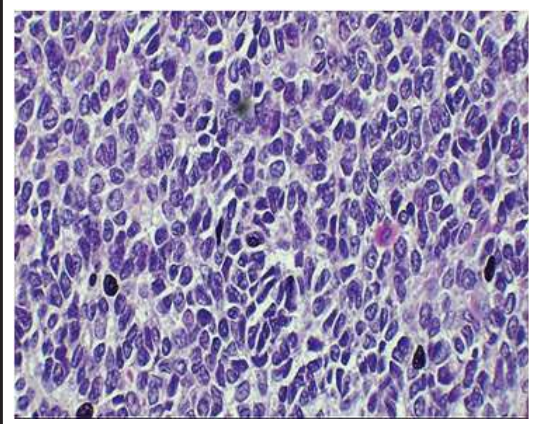
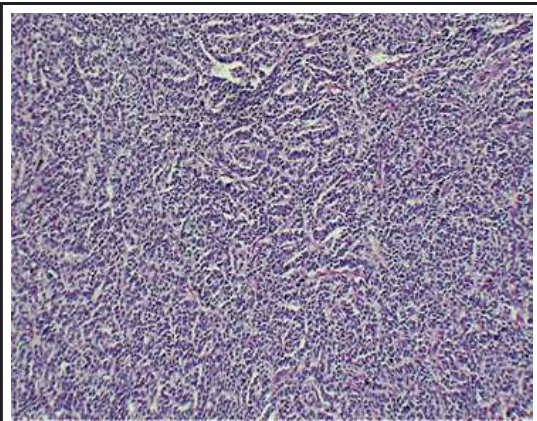


Figure-4 & 5: Low (100x) and high power (400x) of left granulosa cell tumor

Tumor cells arranged in inter-anastomosing trabeculae of ribbons and cords. (HE, 100x); Sheets of monotonous small cells with scant cytoplasm and nuclei with occasional longitudinal grooves (HE, 400x)

DISCUSSION

GCT is low malignant ovarian tumor which arises from the granulosa cells, the somatic cells of the sex cords of the ovary. The age ranges from 35 to 81 years and the peak incidence is at 50-55 years.⁶⁻⁸ In three cases of GCT reported by Moustaid H and

colleagues age group ranged from 52 to 81 years.⁹ They have a long natural history with indolent growth. Granulosa cells are responsible for the production of sex steroids and peptides necessary for ovulation. These tumors may present with features of hyper-estrogenicity as precocious puberty, altered menstrual patterns and vaginal bleeding in postmenopausal age.^{1,3,6} Small group may present with infertility due to unregulated inhibin and virilizing features due to androgen.³ Among the post menopausal women, vaginal bleeding is the most common finding.^{1,6} These tumors may also present with a large palpable abdominal mass.^{1,3,6} In a study done by Dridi M et al abdominal mass and post menopausal bleeding was seen in 61% (19/31) and 32% (10/31) of cases respectively.⁷ Similar presentation of abdominal mass and postmenopausal bleeding were seen in other case reports as in this case.⁹ Minor problems like mastalgia and risk of breast cancer development is also increased in these women secondary to higher exposure to estrogen.^{3,6,10} Some cases may present with features of acute abdomen due to the rupture of the tumor.^{6,10} It may be associated with endometrial hyperplasia (32-85%) as well as the endometrial cancer (3-22%).^{3,10} Continuous exposure to ovulation induction drugs like selective estrogen receptor modulators (SERM), clomiphene citrate, gonadotropins may also increase the risk of GCT. Chromosomal abnormalities like trisomy 12, monosomy 22, and deletion of chromosome 6 have also been seen in cases of GCT.⁶

In ultrasound, usually they present as the predominantly multi-cystic mass with variable solid components or solid masses, none of which are diagnostic.^{1,3} Similar to this case, in majority of case reports unilateral cystic masses were seen on ultrasonography with median tumor size of 20 cm (4-33 cm).^{7,9} Similar to the case, in a case report by Moustaid H, there was a heterogenous vascularised ultrasonographic picture of GCT.⁹

As in this case, elevated levels of CA-125 were seen in 42% of cases (13/31) of GCT in a retrospective study.⁷ Suspicion arises when there is hyper-estrogenism, thickened endometrium and raised inhibin levels.^{6,1} However, estradiol levels cannot be used as a reliable marker as its level does not correlate with the disease and has variable response to treatment.¹⁰ Inhibin acts as the granulosa cell growth factor and its level reflects the tumor burden; so it

can be used as the tumor marker.^{6,10} Inhibin B is more specific than inhibin A.¹ However, not all granulosa cell tumors express inhibin.⁶ As GCT are diagnosed usually in the pathological specimens, serum inhibin is usually not done in preoperative period.^{1,6} Similar to this case, serum inhibin was not studied in any cases in a large retrospective study.⁷

Surgery is the diagnostic as well as therapeutic option for histological diagnosis, staging and cytoreduction.^{1,6,10} They are usually unilateral confined to the ovary at the time presentation.^{3,4,6} Ascites, bilaterality and peritoneal seedlings are rarely seen in these type of tumors.⁶ These features make it different from the epithelial ovarian tumors. Advanced disease is seen in 10% of cases.¹⁰ As in this case, all had undergone surgery and disease was limited to Stage I in majority of the cases.^{7,8,10-12} On gross examination, they are predominantly cystic and resemble mucinous cystadenoma while on cut section they have serous fluid or clotted blood.¹⁰ The nuclei of the tumor cells have characteristic coffee-bean appearance (grooved nuclei).^{1,9,10} Similar finding was noted on histopathological examination of the specimen of this case. Call-Exner bodies which consist of rosette arrangement of cells around an eosinophilic fluid space, are diagnostic of GCT.^{1,10} However, this feature may not be sharply defined in many cases.¹⁰ Extracellular expression of Vimentin, CD99, smooth muscle actin and inhibin aids on confirmation of the diagnosis of adult GCT which was seen in some case reports.^{9,12}

Majority of them are symptomatic and detected at stage I. They have a long natural history and compared to the epithelial tumors, they have better prognosis.^{6,10} Stage of the disease best correlates with the prognosis while other factors which are not well established for the prognosis are tumor size, tumor rupture, nuclear atypia and aneuploidy.¹⁰ Associated endometrial cancers are usually the well differentiated early stage endometrioid adenocarcinoma and have a good prognosis.^{3,6} GCT is responsive to platinum based chemotherapy (bleomycin, etoposide and cisplatin).^{5,6,10} Usually surgery is sufficient in stage I disease but when there is a large tumor with high mitotic index or ruptured capsule, chances of recurrences increases and then chemotherapy may be indicated.¹⁰ Conservative surgeries can be done for Stage I adult GCT in young women.⁵ For inoperable advanced and recurrent diseases, chemotherapy as

well as hormonal therapy (progestins) have been considered. Although radiotherapy has a limited role, it has been found to prolong survival in advanced cases.¹⁰ In the study done by Sehouli J et al, majority of cases did not require chemotherapy.⁸ Although five year survival is more than 90%, late recurrence has been noted, even with the stage I disease.^{3,5,10} In one fourth of them, recurrence may be seen after many years, even decades of apparent clinical cure.^{1,3} Recurrences have been found to be associated with increased fatality in majority of the cases.^{1,6}

CONCLUSIONS

Majority of adult GCT presents with abdominal mass and postmenopausal bleeding. Surgery is the mainstay of treatment and chemotherapy is indicated in advanced cases. Serum inhibin test as a tumor marker of granulosa cell tumor is usually run in retrospect after histopathological report. However, life-long follow up is advised as it is a late recurring malignancy.

REFERENCES

- Hoffman BL, Schorge JO, Schaffer JJ, Halvorson LM, Bradshaw KD, Cunningham FG. *William's gynaecology*. 2nd ed. New York: McGraw-Hill; 2012. Chapter 36, Ovarian Germ Cell and Sex Cord-Stromal Tumors; p.879-89.
- Haroon S, Zia A, Idrees R, Memon A, Fatima, Kayani N. Clinicopathological spectrum of ovarian sex cord-stromal tumors; 20 years' retrospective study in a developing country. *J Ovarian Research*. 2013;6:87.
- Horta M, Cunha TM. Sex cord-stromal tumors of the ovary: a comprehensive review and update for radiologists. *Diagn Interv Radiol*. 2015;21:277-86.
- Classification of tumours of the ovary. In: Kurman RJ, Carcangiu ML, Herrington CS, Young RH, editors. *WHO classification of tumours*. 4th ed. Lyon. IARC;2014.
- Ray-Coquard I, Morice P, Lorusso D, Prat J, Oaknin A, Pautier P, Colombo N. Non-epithelial ovarian cancer: ESMO clinical practice guidelines for diagnosis, treatment and follow-up. *Ann Oncol*. 2018;00:1-18.
- Kottarathil VD, Antony MA, Nair IR, Pavithran K. Recent Advances in Granulosa Cell Tumor Ovary: A Review. *Indian J Surg Oncol*. 2013;4(1):37-47.
- Dridi M, Chraiet N, Batti R, Ayadi M, Mokrani A, Meddeb K et al. Granulosa cell tumor of the ovary: a retrospective study of 31 cases and a review of the literature. *Int J Surgical Oncol*. 2018;2018:4-9.
- Sehouli J, Drescher FS, Mustea A, Elling D, Friedmann W, Kühn W et al. Granulosa cell tumor of the ovary: 10 years follow-up data of 65 patients. *Anticancer research*. 2004;1(24-2C):1223-30.
- Moustaide H, Taheri H, Benkirane S, Saadi H, Mimouni A. Ovarian adult granulosa cell tumor: report of 3 cases. *J Clin Case Rep*. 2017;7:1062.
- Koukourakis GV, Kouloulis VE, Koukourakis MJ, Zacharias GA, Papadimitriou, Mystakidou K et al. Granulosa cell tumor of the ovary: tumor review. *Integrative Cancer Therapies*. 2008;7(3):204-15.
- Shim SH, Lee SJ, Kim DY, Kim J, Kim SN, Kang SB et al. A long-term follow-up study of 91 cases with ovarian granulosa cell tumors. *Anticancer research*. 2014;34(2):1001-10.
- Vani BR, Geethamala K, Geetha RL, Srinivasa MV. Granulosa cell tumor of ovary: a clinicopathological study of four cases with brief review of literature. *J Mid-life Health*. 2014;5(3):135-8.