

## Ruptured Right Cornual Pregnancy

Pokharel S<sup>1</sup>, Dangal G<sup>1</sup>, Karki A<sup>1</sup>, Pradhan HK<sup>1</sup>, Shrestha R<sup>1</sup>, Bhattachan K<sup>1</sup>, Thapa S<sup>1</sup>, Paudel R<sup>1</sup>, Bajracharya N<sup>1</sup>

<sup>1</sup>Department of Obstetrics and Gynaecology, Kathmandu Model Hospital Kathmandu, Nepal

Received: 2 Mar 2018; Accepted: 30 Apr 2018

The ectopic implantation is implantation of fertilized ovum outside the uterine cavity, ampulla of fallopian tube being the most common site. A cornual or interstitial pregnancy is an ectopic pregnancy that develops in the interstitial portion of the fallopian tube which is one of the most hazardous type of ectopic gestation. Treatment depends on the week of gestation at the time of diagnosis, level of serum  $\beta$  HCG, findings of ultrasonography, hemodynamic stability of the patient and the choice of future fertility. In this case report, we present a case which was previously misdiagnosed as a case of missed abortion at 8 weeks of gestation by transabdominal ultrasound and patient underwent medical abortion with mifepristone and misoprostol after 1 month presented with pain abdomen and was confirmed as extrauterine pregnancy by transabdominal ultrasound followed by surgical management.

**Keywords:** cornual pregnancy; ectopic pregnancy; laparoscopy

<http://dx.doi.org/10.3126/njog.v13i1.21619>

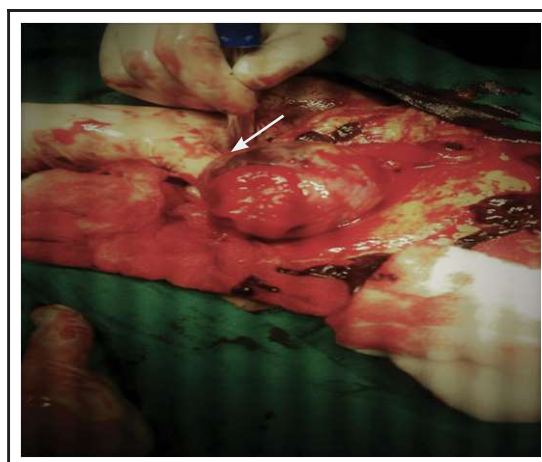
### INTRODUCTION

Ectopic pregnancy is a the one which develops following implantation anywhere other than endometrial cavity of the uterus. Ectopic pregnancy is one of the serious complication of pregnancy and is one of the leading causes of maternal morbidity and mortality. About 95% of ectopic pregnancy occurs in fallopian tube and of these 55% occurs in ampulla. Cornual(interstitial) pregnancy is a rare form of ectopic pregnancy accounting for 2-4% of ectopic pregnancy or once every 2,500 to 5000 live birth.<sup>1</sup>Risk factors for interstitial pregnancy are similar to other type of ectopic pregnancy.<sup>2</sup>

### CASE

A 41 years multigravida, G3P2L2, presented to emergency of Kathmandu Model Hospital on Mangsir 21, 2074 with the complaint of pain lower abdomen 5 hours prior to presentation to hospital. Her vitals were stable. Lower abdomen was tender over right iliac region. On her pelvic examination uterus was retroverted, 12 weeks size, tenderness present in right fornix, cervical motion tenderness present. Urine pregnancy test was positive and she gave history of medical abortion at some other health center for missed abortion at 8w6d of gestation 1 month ago

and had minimal bleeding after taking medicine for abortion. No other significant past medical and surgical history. Her previous two pregnancy were uneventful vaginal deliveries. The initial laboratory test included Hb 12.4gm%, total count, differential count, platelets, renal function test, serum amylase were within normal limit. On the abdominal ultrasonography, single live embryo of 12+ weeks of gestation (CRL 59mm= 12w3d) noted at right side of uterus possibly right cornu, moderate amount of free fluid noted in the abdomen and pelvis.



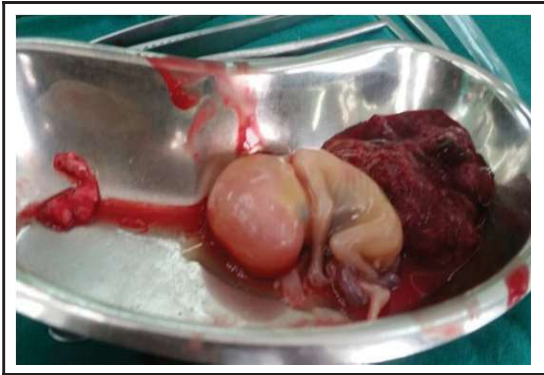**Figure-1: Intra-operative picture of ruptured right ectopic interstitial pregnancy. Arrow shows the rupture site**

An emergency laparotomy with bilateral tubal ligation was performed under general anaesthesia. There was approximately 2000 ml blood in abdominal cavity with a male foetus protruding from the right

### CORRESPONDENCE

Dr Shreesiya Pokharel  
Department of Obstetrics and Gynaecology  
Paropakar Maternity and Women's Hospital, Thapathali,  
Kathmandu  
Email: shreesiya03@gmail.com  
Phone: +977-9843-051234

ruptured cornual region. The rupture measured 10-12 cm in length and placental tissue protruding through it. Normal left fallopian tube and both ovaries were normal. Three pints of whole blood was transfused. Postoperative period was uneventful and she was discharged on third postoperative day in good condition.



**Figure-2: Single non-viable male fetus with placenta.**

## COMMENTS

Cornual gestation is one of the most hazardous type of ectopic gestation. The diagnosis and treatment are challenging and mostly is a medical emergency. The interstitial part of the fallopian tube is the proximal portion that lies within the muscular wall of the uterus and the pregnancies implanted in this site are called interstitial (cornual) pregnancy.<sup>3</sup> It should be differentiated from the angular pregnancy in which the embryo implants in the lateral angle of the uterine cavity medial to the internal ostium of the fallopian tube. The gestational sac is better protected in the interstitial portion than in other portion of the tube, the symptoms of interstitial pregnancies usually manifest later (>12 weeks of gestation). Due to its location there is difficulty in the diagnosis and treatment, leading to high mortality compared to other ectopics. Pelvic pain and vaginal spotting are common early symptoms and because the pregnancy occurs at the most vascularized area of the female pelvis, that is, the junction of uterine and ovarian vessels rupture usually causes profound and sudden shock.<sup>1</sup>

Clinically, risk factors are as for other type of ectopic pregnancy: PID, previous pelvic surgery, previous ectopic pregnancy, in vitro fertilization, ipsilateral salpingectomy.<sup>3</sup> The combination of a high index of suspicion, sensitive serum  $\beta$ -hCG assays, and transvaginal sonography has revolutionized the diagnosis of tubal pregnancy. Interstitial pregnancy,

however, remains the most difficult ectopic pregnancy to diagnose preoperatively. An eccentrically located gestational sac surrounded by an asymmetric myometrial mantle and a separate empty uterine cavity with endometrial echoes were the most common ultrasonographic findings of interstitial gestations.<sup>4</sup> Timor-Tritsch et al<sup>6</sup> adopted the same parameters and diagnosed interstitial pregnancy according to three sonographic criteria: an empty uterine cavity, a chorionic sac seen separately and 1 cm from the most lateral edge of the uterine cavity, and a thin myometrial layer surrounding the chorionic sac.

The traditional treatment of interstitial pregnancy has been cornual resection or hysterectomy in cases with severely damaged uteri.<sup>3</sup> Ruptured interstitial pregnancy may present with hypovolemic shock, necessitating emergency laparotomy and cornual resection or hysterectomy. However, in patients who are hemodynamically stable, conservative measures may be attempted, including laparoscopy or medical management. Laparoscopic resection may be assisted by direct injection of vasoconstrictive agents such as diluted vasopressin. There is no general consensus on the best surgical procedure for interstitial ectopic pregnancy. Increasingly more conservative approaches are being used, such as cornuostomy instead of cornual resection, as well as laparoscopy in place of laparotomy.<sup>5</sup> The Royal College of Obstetricians and Gynaecologists recommends that the women with tubal pregnancy who are most suitable for methotrexate therapy are those with a serum hCG level of <3000 iu/l and with minimal symptoms. Future fertility is possible in patients with a history of interstitial pregnancy. There is a concern regarding uterine rupture because of the weakened myometrial scar.<sup>5</sup>

## CONCLUSIONS

Cornual pregnancy poses a significant diagnostic and therapeutic challenge and carries a greater maternal mortality risk than tubal pregnancy. Transvaginal sonography can be helpful but often is not conclusive. Early clinical diagnosis aided by ultrasound or laparoscopy may help to contribute towards effective conservative management. The serious consequences of cornual pregnancy are caused mainly by rupture after 12 weeks of pregnancy, leading to catastrophic haemorrhage and even death. Cornual excision or hysterectomy used to be the treatment for such

cases. Conservative management has, however, been increasingly practiced successfully. This includes laparoscopic conservative treatment and medical

treatment with systemic methotrexate. Appropriate individual counseling is needed regarding risks of future pregnancy and mode of delivery.

---

## REFERENCES

1. Damario MA. Ectopic pregnancy. In: Rock JA, Thompson JD, editors. *TeLinde's Operative Gynaecology*. 11th ed. New York: Lippincott Williams & Wilkins; 2016. p.771-98.
2. Hoffman BL, Schorge JO, Bradshaw KD, Halvorson LM, Schaffer JI, Corton MM. *Williams Gynaecology*. 3rd ed. New York: McGrawHill; 2016. Chapter 7, Ectopic Pregnancy; p.161-79.
3. Faraj R, Steel M. Management of cornual (interstitial) pregnancy. *Obstet Gynaecol*. 2007;9:249-55.
4. Lau S, Tulandi T. Conservative medical and surgical management of interstitial ectopic pregnancy. *Fertil Steril*. 1999;72(2):207-15.
5. Warda H, Mamik MM, Ashraf M, Abuzeid MI. Interstitial ectopic pregnancy: Conservative surgical management. *JSLs*. 2014;18(2):197-203.
6. Naredi N, Sandeep K, Jamwal VD. Interstitial implantation in a setting of recurrent ectopic pregnancy: A rare combination. *MedJ Armed Forces India*. 2015;71(2):194-6.