


## Post-Stroke Mania- A Case Series

Yogi Rana<sup>1</sup>, Abhishek Pathak<sup>2</sup>, Manish Singh<sup>3</sup>, Vishesh Yadav<sup>4</sup>, Rahul Singh<sup>5</sup><sup>1, 2, 3, 4, 5</sup> Department of Psychiatry, Hind Institute of Medical Sciences, Sitapur, Uttar PradeshDate of submission: 29<sup>th</sup> December 2023Date of Acceptance: 10<sup>th</sup> May 2024Date of publication: 15<sup>th</sup> May 2024

## Abstract

**Introduction:** Post-stroke mania is a complex neuropsychiatric phenomenon that poses challenges in both diagnosis and management. This paper presents a detailed analysis of three distinct cases, comprising two females and one male, each exhibiting post-stroke mania following cerebrovascular events. Our study aims to provide insights into the varied clinical presentations, contributing factors, and therapeutic interventions in this unique subset of stroke survivors.

**Case 1:** A 71-year-old female experienced a left hemispheric stroke, subsequently displaying manic symptoms characterized by elevated mood, impulsivity, and increased energy. Neuroimaging revealed damage to the parieto-occipital lobe, prompting further exploration into the neural correlates of post-stroke mania.

**Case 2:** A 51-year-old female presented with right hemiparesis. Shortly after the stroke, she manifested manic features, including decreased need for sleep and heightened irritability. Psychosocial factors and pharmacological interventions were investigated to better understand the interplay of biological and environmental influences.

**Case 3:** A 55-year-old male suffered a left hemispheric stroke. Poststroke, she exhibited manic symptoms such as distractibility and excessive goal-directed activity. The impact of lesion location on the manifestation of post-stroke mania was explored in this case.

**Conclusion:** Through a comprehensive analysis of these cases, we aim to contribute to the growing body of literature on post-stroke mania, shedding light on its clinical heterogeneity and paving the way for tailored treatment approaches. Recognizing the nuanced nature of post-stroke mania is crucial for healthcare providers to optimize care strategies and improve the quality of life for stroke survivors grappling with this challenging neuropsychiatric condition

**Keywords:** Post stroke Presentation, Old age, Atypical Presentation, Secondary Mania, Acute Psychosis

## Introduction

Mania is defined as history of abnormally and persistently elevated or irritable mood, over activity and social disinhibition associated with flight of ideas, grandiose ideation, lack of insight and behavioral disturbances for a period of more than seven days<sup>1</sup>. Late onset of first episode mania is relatively uncommon<sup>2</sup>. Secondary mania, as defined by Krauthammer and Klerman<sup>3</sup> is caused by underlying neurological, metabolic or toxic disorder. Research in geriatric population has documented the fact that organic damage to brain has a more significant

impact as compared to life events in precipitating episodes of late-onset mania<sup>4,6</sup>. Anxiety, psychosis, posttraumatic stress disorder (PTSD), and post-stroke depression (PSD) are some of the common post psychiatric sequelae of stroke and cerebrovascular disease<sup>7</sup>.

Mania has been reported as an unusual manifestation after cerebrovascular accidents; its frequency is <1% in comparison with depression and other mood disorders<sup>8</sup>. Mania appears to occur with greater frequency following right-sided lesions; however, there are also reports of mania arising after left-sided lesions<sup>9</sup>. A vast body of research has focused on secondary depression in patients due to stroke and cerebrovascular disease. However, reported cases of manic episodes following a stroke are limited. Case series and individual case reports play a significant role in contributing to the formation of a robust database, facilitating a deeper understanding of this condition. Therefore, authors are presenting a case series which highlights patients developing mania secondary to stroke.

## Case Report- 1

Mrs. S, 71 years old Hindu married female, born to lower socioeconomic class, belonging to rural background, presented to psychiatry outpatient services with an abrupt onset of right sided numbness and weakness of the body, irrelevant talk, inappropriate behavior, increased talk with increased goal directed activities, tall claims that patient has a supreme power to cure any diseases, decreased need for sleep and seeing people not seen by others. Patient reported to psychiatry outpatient services of HIMS, Sitapur on the 6th day. After taking informed consent from the patient's attendant, she was admitted to the

## Access this article online

Website: <https://www.nepjol.info/index.php/NJN>DOI: <https://doi.org/10.3126/njn.v21i1.61170>

## HOW TO CITE

Pathak A, Rana Y, Singh M, Yadav V, Singh R. Post-Stroke Mania- A Case Series. NJNS. 2024;21(1):43-46



## Address for correspondence:

Prof. (Dr). Abhishek Pathak, Professor  
Department of Psychiatry Hind Institute of Medical Sciences Sitapur,  
Uttar Pradesh  
Email: drpathak7@gmail.com

Copyright © 2023 Nepalese Society of Neurosurgeons (NESON)

ISSN: 1813-1948 (Print), 1813-1956 (Online)



This work is licensed under a Creative Commons  
Attribution-Non Commercial 4.0 International License.

female psychiatry ward. Patient had past medical history of hypertension from last 1 year. There was history of poor compliance to antihypertensive drugs and patient was off medication from last 15 days. There was no significant family history of medical or psychiatry illness.

On examination, she was found to be alert, conscious and oriented to time, place, person. Her blood pressure was 170/104 millimeter of mercury and her pulse rate was 110 beat per minutes. There was no audible murmur. Her lungs were bilaterally clear. Her abdominal examination was normal. Neurological examination revealed a full Glasgow Coma Scale score. She was right-handed, using her right hand predominantly for grasping objects and manual dexterity tasks. Facial symmetry was present. There was no abnormality detected during examination of cranial nerves. Musculoskeletal system examination revealed that power in the right upper and lower limbs was 4/5 with increased tone. Right side planter was extended, and tendon reflexes were slightly brisk on right side. Sensation was normal on both sides. Fundoscopy was normal. Mental status examination revealed features suggestive of mania such as overfamiliarity, increased psychomotor activity, pressured speech, elation, grandiose delusion, visual hallucination. Computerized tomography of the brain was done and revealed left posterior cerebral territory infarct (Figure 1). Echocardiogram (ECG) was normal. Troponin T test was negative and thyroid function was normal. Her lipid profile was raised. She was managed by psychiatrist and neurologist. She was prescribed antihypertensive, anti-platelets treatment. For manic symptoms she was prescribed tablet Risperidone 4mg per day and tablet Lorazepam 2mg HS. Patient condition started improving gradually and was discharged 10 days later.

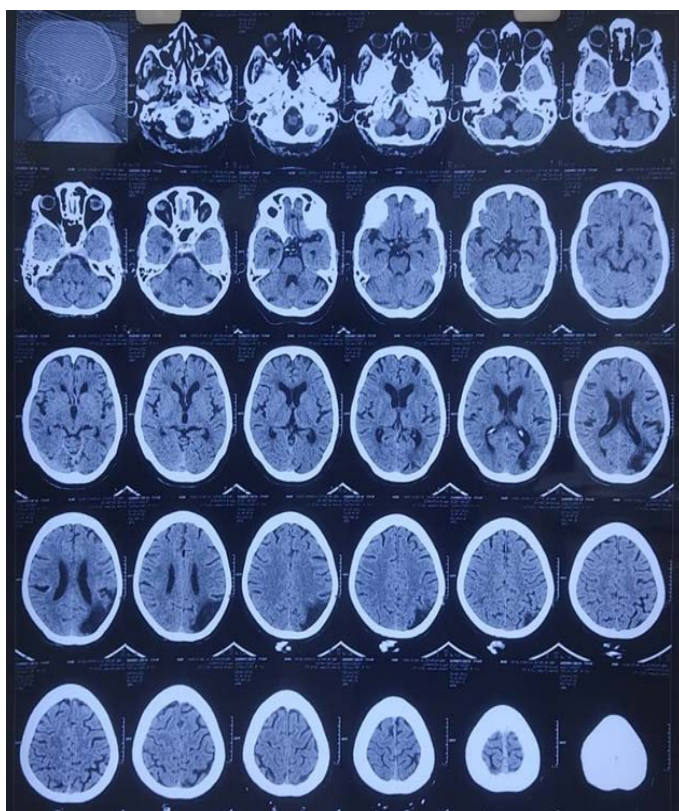


Figure 1 Computerized tomography Scan (Brain) showing infarct in the left hemisphere

## Case Report- 2

Mrs. V, 51 years old Hindu married female, born to lower socioeconomic status, belonging to rural background presented to psychiatry outpatient services with an abrupt onset of left side weakness of the body and difficulty in walking, increased talks laced with grandiosity, disinhibited behaviour, increased goal directed activities, reckless expenditure, increased religious activity and decreased need for sleep. She reported to psychiatry outpatient services of HIMS, Sitapur on the 8th day. After taking informed consent from the patient's attendant, she was admitted to the female psychiatry ward.

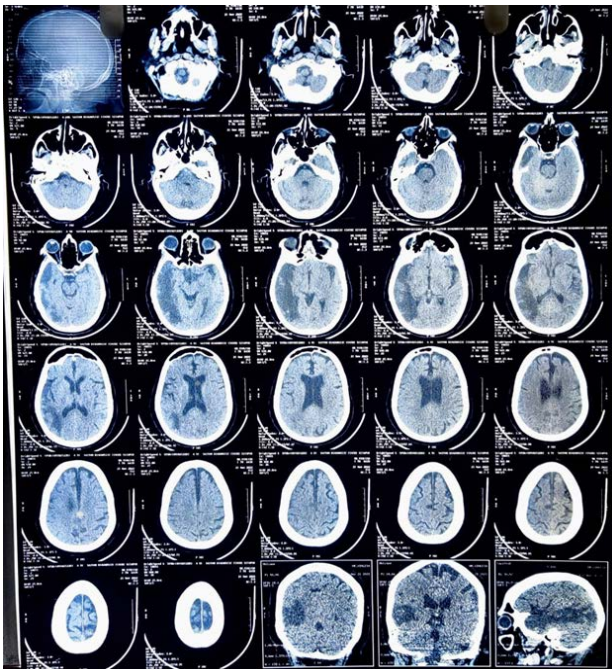
Patient had past medical history of type 2 diabetes mellitus since 2005 and was on ayurvedic medication. She had poor compliance to drugs. She was off medication from 2 years but she was taking ayurvedic medication from last 40 days. Patient also had past medical history of hypertension since 2005, however she was not on any antihypertensive drugs from last 5 years.

There was no significant family history of medical or psychiatry illness.

On examination, she was found to be alert, conscious and oriented to time, place, person. Her blood pressure was 150/100 millimeter of mercury and her pulse rate was 108 beat per minutes. There was no audible murmur. Her lungs were bilaterally clear. Her abdominal examination was normal. Neurological examination revealed a full Glasgow Coma Scale score. She was right-handed, using her right hand predominantly for grasping objects and manual dexterity tasks. Facial symmetry was present. All cranial nerves were intact. Musculoskeletal system examination revealed that power on the left upper and lower limbs was 4/5 with increased tone. Left side planter was extended and tendon reflexes were slightly brisk on left side. Gait of the patient was hemiplegic gait. Sensation was normal on both sides. Fundoscopy was normal.

Mental status examination revealed features of mania such as increased psychomotor activity, pressured speech, flight of ideas, elated affect, grandiose delusion. Computerized tomography of the brain was done and revealed right sided temporo-parietal infarct (Figure 2). Echocardiogram (ECG) was normal. Fasting and postprandial blood sugar was within normal range. Troponin T test was negative and thyroid function was normal. Her lipid profile was raised. She was managed by psychiatrist and neurologist. She was prescribed antihypertensive, anti-platelet treatment. For manic symptoms she was prescribed tablet Risperidone 2mg per day and 10 mg of zolpidem on a need basis. Patient condition started improving gradually and was discharged 10 days later.





*Figure 2: Computerized tomography Scan (Brain) showing infarct in the right hemisphere*

### Case Report- 3

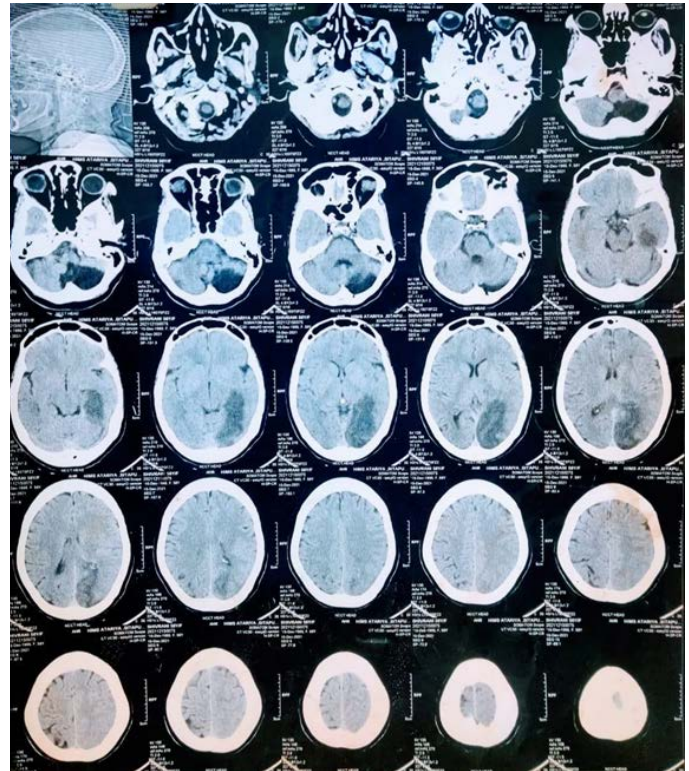
Mr. M, 55 years old Muslim married man, born to lower socioeconomic status, belonging to rural background, farmer by occupation presented to psychiatry outpatient services with an abrupt onset of abusive and assaultive behavior, increased talk and increased goal directed activities, wandering and escaping behavior, muttering to self, tall claims as patient describing him as a central government minister and decreased need for sleep. Patient reported to psychiatry outpatient services of HIMS, Sitapur on the 7th day. After taking informed consent from the patient's attendant, he was admitted to the male psychiatry ward.

Patient had past medical history of hypertension from last 10 years. Patient was on anti hypertensive medication (Amlodipine 5 mg/day) from last 10 years. There was no significant family history of medical or psychiatry illness.

On examination, he was found to be alert, conscious and oriented to time, place, person. His blood pressure was 160/100 millimeter of mercury and his pulse rate was 108 beat per minutes. There was no audible murmur. His lungs were bilaterally clear. His abdominal examination was normal. Neurological examination revealed a full Glasgow Coma Scale score. He was right-handed, using his right hand predominantly for grasping objects and manual dexterity tasks. Facial symmetrical was present. All cranial nerves were intact. Musculoskeletal system examination was normal. Superficial and deep reflexes were normal. Bilateral planter flexion was present. Sensation was normal on both sides. Fundoscopy was normal.

Mental status examination revealed features of mania such as increased psychomotor activity, pressure of speech, elation, flight of ideas, grandiose delusion and decreased need for sleep. Computerized tomography of the brain was done and revealed left sided temporo-occipital infarct (Figure 3).

Echocardiogram (ECG) was normal. Troponin T test was negative and thyroid function was normal. His lipid profile was within normal range. He was managed by psychiatrist and neurologist. He was prescribed antihypertensive, anti-platelet treatment. For manic symptoms he was prescribed tablet Risperidone 4mg per day and 10 mg of zolpidem on a need basis. Patient condition started improving gradually and was discharged 10 days later.



*Figure 3 Computerized tomography Scan (Brain) showing infarct in the left hemisphere*

### Discussion

All the three patients had the following features in common: all of them presented with the acute onset of manic behavior, were known case of hypertension, and were right-handed. Out of three, two are female and one is male. Out of three two had left sided infarct and one had right sided infarct. Two of them had neurological deficit i.e. weakness of the corresponding side of the body but one did not have any neurological symptoms. Both had rapid improvement in their neurologic deficits. In all the patients, the mania resolved gradually over 2-4 week. Neither patient had a personal or family history of affective disorder, and three of them were older than expected for the onset of an idiopathic manic-depressive disorder.

Secondary mania is often misdiagnosed as delirium in elderly patients. The course of organic mania is not clear and its prevalence and incidence are not known<sup>9</sup>. The temporal relationship between stroke and mania ranged from immediately after stroke to up to 2 years thereafter<sup>10</sup>. However, the majority of mania cases seem to appear within the first month following a stroke, as in our patients. Secondary mania is very similar to primary mania in clinical profile, characterized

mainly by elevated mood/euphoria, pressured speech, flight of ideas, grandiosity and decreased need for sleep. The causal relationship between stroke and mania has also been based on other factors than left sided lesions include lack of a previous personal or family psychiatric affective disorder, the presence of vascular risk factors and a temporal relationship between

the vascular event and the mood change in the absence of other potential precipitants of mania<sup>11</sup>. Secondary mania has been attributed to various conditions, including drug use, CNS trauma, neoplasms, vascular and degenerative diseases, epilepsy, infections and metabolic conditions<sup>12</sup>.

*Table 1: Summary of case series*

S. No.	Age	Sex	Duration of symptoms	Brain Hemisphere involved	Neurological deficit	Affective symptoms	Cognitive impairment
1	71	Female	6 days	Left	Present	Present	Absent
2	51	Female	8 days	Right	Present	Present	Absent
3	55	Male	7 days	Left	Absent	present	Absent

## Conclusion

We suspect that post-stroke mania, like other psychiatric features following a stroke, is under recognised due to its atypical presentation. Early recognition of poststroke mania in patients such as ours helps direct appropriate management and minimise risk and suffering. Post-stroke mania should be considered in any manic patient who presents concomitant neurological focal deficits and is older than expected for the onset of primary mania.

### Limitations

Considering the financial challenges faced by the patients, we proceeded with CT scan over an MRI.

## Reference

- American Psychiatric Association: Mood disorders; in: Diagnostic and Statistical Manual of Mental Disorders, ed 4, text revision. Washington, American Psychiatric Association, 2002: 345–428.
- Young RC, Klerman GL. Mania in late life: focus on age at onset. *Am J Psychiatry* 1992;149:867-76.
- Krauthammer C, Klerman G: Secondary mania. Manic syndromes associated with antecedent physical illness or drugs. *Arch Gen Psychiatry* 1978; 35: 1333–1339
- Blazer DG, Steffens DC, Busse EW. Textbook of Geriatric Psychiatry, 3rd edn. American Psychiatric Publishing, 2004.
- Broadhead J, Jacoby R. Mania in old age: A First Prospective Study. *Int J Geriatr Psychiatry* 1990; 5(4):215-22.
- Subramaniam H, Dennis MS, Byrne EJ. The role of vascular risk factors in late onset bipolar disorder. *Int J Geriatr Psychiatry* 2007;22(8):733-7.
- Capaldi VF, 2nd, Wynn GH. Emerging strategies in the treatment of poststroke depression and psychiatric distress in patients. *Psychol Res Behav Manag.* 2010;3:109–118.
- Huffman JC, Stern TA. Poststroke neuropsychiatric symptoms and pseudoseizures: a discussion. *Prim Care Companion J Clin Psychiatry.* 2003;5(2):85–88.
- Starkstein SE, Boston JD, Robinson RG: Mechanisms of mania after brain injury. 12 case reports and review of the literature. *J Nerv Ment Dis* 1988; 176: 87–100.
- Celik Y, Erdogan E, Tuglu C, Utku U: Poststroke mania in late life due to right temporoparietal infarction. *Psychiatry ClinNeurosci* 2004; 58: 446–447.
- Jorge et al: Secondary mania following traumatic brain injury. *Am J Psychiatry* 1993; 150:916-921.
- Evans DL, Byerly MJ, Greer RA: Secondary mania: diagnosis and treatment. *J Clin Psychiatry* 1995; 56 (suppl 3):31–37.