

Non-tuberculous long multi-segment spinal epidural abscess with co-existing giant psoas abscess in an intravenous drug abuser: A rare case report from India


Manish Kumar Mishra¹, Nityanand Pandey²

Department of Neurosurgery, Institute of Medical Sciences, BHU, Varanasi, UP,

Date of submission: 14th August 2023

Date of Acceptance: 17th January 2024

Date of publication: 30th January 2024



Abstract

In developing countries, Mycobacterium tuberculosis is rampant and it's the first differential in causation of spinal epidural abscess (SEA) or Psoas abscess (PA). This microbiota pertaining to these diseases, is in contrast with that of developed nations, where it is primarily bacterial. The burden of intra-venous drug abusers is very high in India, however there is corresponding rarity of intravenous drug abuse (IVDA) related SEA/ PA case studies. Even at global scale, there is no fixed recommendation in the surgical management (instrumentation and fusion) of IVDA-SEA subset of patients owing to their low volume and poor-follow-up. In this back-ground authors present their experience of managing an IVDA associated long segment multi-level SEA with giant PA who presented with ASIA Grade-C neurological deficit.

Key words: Spinal epidural abscess, Psoas abscess, intravenous drug abuser, Staphylococcus aureus, Mycobacterium tuberculosis

Introduction

The curse of drug abuse is global and India is no exception. The abusers are notorious for habitual lies, delayed presentation, poor compliance to treatment and attrition while follow up.¹ Intravenous drug abuse (IVDA) is an established risk factor in the causation of spinal epidural abscess (SEA) and psoas abscess (PA).² SEA is a neurosurgical emergency. Both SEA and PA are rare conditions with vague symptomatology of backache, fever, gait disturbance with or without neurological deficits. Till date literature has no guidelines for management of spinal infections in this sub-set of population. Hereby authors report, probably the first case of multilevel SEA and large psoas abscess associated with IVDA from Indian subcontinent. Patient was surgically treated to near normalcy and rehabilitated.

Case Presentation:

A 44 years-old-gentleman, was brought to neurosurgical emergency with 3 months' history of backache, left flank pain and progressive weakness of both lower limbs. There was no history of fever. He was an intra-venous heroine abuser for 8 years. His symptoms were initially neglected by family members. On deterioration, they brought him with grade C neurological deficit on ASIA (American Spinal Injury Association) Impairment scale. Magnetic resonance imaging (MRI) spine showed multi-level epidural collection spanning from D11 to L4 vertebrae, communicating with pre-spinal, paraspinal (left > right) and posterior spinal collections (Fig:1).

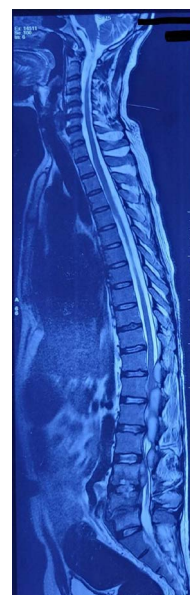

Figure1: T2 weighted sequence of MRI spine (lumbo-sacral region with whole spine screening) showing multilevel (D11-L4) epidural collection with peri-spinal collection in sagittal view.

Access this article online

Website: <https://www.nepjol.info/index.php/NJN>

DOI: <https://doi.org/10.3126/njn.v20i4.58977>

HOW TO CITE

Mishra MK, Pandey N. Non-tuberculous long multi-segment spinal epidural abscess with co-existing giant psoas abscess in an intravenous drug abuser: A rare case report from India. NJNS. 2023;20(4):50-53

Address for correspondence:

Dr. Manish Kumar Mishra,
Senior Resident
A-605, French Apartment, Sector: 16B, Greater Noida (West), UP, India,
E-mail: drmanishmishravmmc@gmail.com

Copyright © 2023 Nepalese Society of Neurosurgeons (NESON)
ISSN: 1813-1948 (Print), 1813-1956 (Online)



This work is licensed under a Creative Commons Attribution-Non Commercial 4.0 International License.

Non-tuberculous long multi-segment spinal epidural abscess with co-existing giant psoas abscess in an intravenous drug abuser:

There was an adjacent huge (16 × 10 × 8 cm) left paraspinal retro-peritoneal psoas collection (Fig:2).

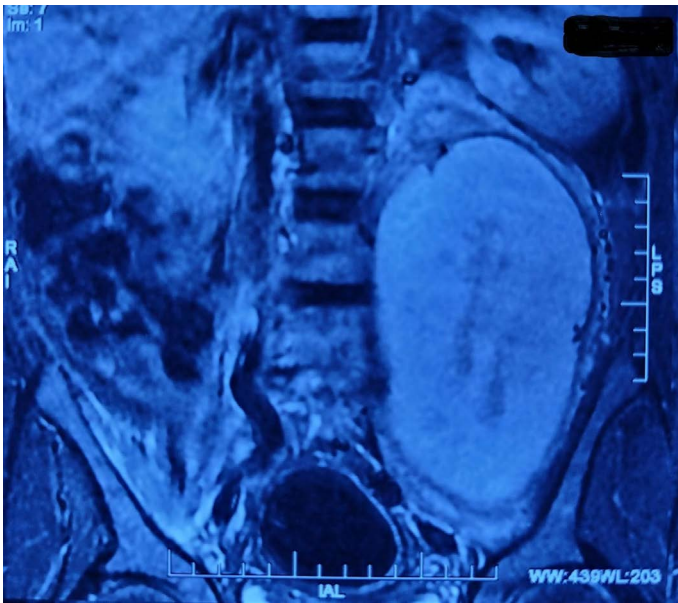


Figure 2: MRI lumbo-sacral spine with Left psoas abscess in coronal section. SEA-PA complex with infective spondylitis features.

The spino-retroperitoneal abscess complex was resembling “Fig-Tree” on imaging. Computed tomography (CT) spine had erosion-destruction changes of L3 to L5 vertebrae with reduced L4 vertebral body height with eroded articular margins at L3-L4 and L4-L5 interface with grade-I anterolisthesis of L4 over L5 vertebral body (Fig: 3) hypo-attenuated left psoas collection (Fig 4).

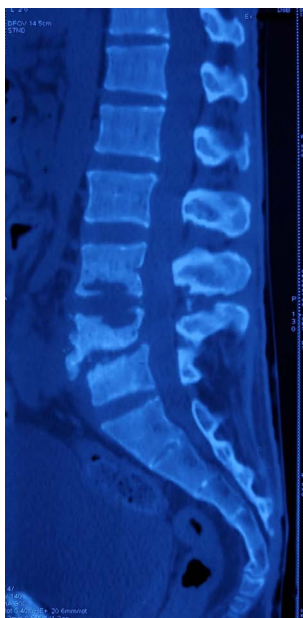


Figure 3: Erosion-destruction of L3, L4 & L5 vertebrae with reduced L4 vertebral height with anterolisthesis of L4 over L5 vertebral body in CT (plain) lumbo-sacral spine.

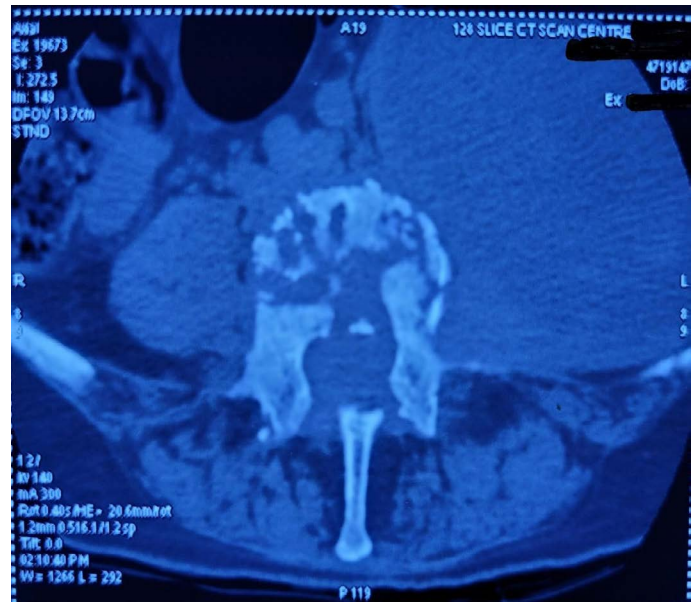

Figure 4: Axial section of lumbar spine at L4 level showing destroyed vertebral body with hypo-attenuated left psoas collection in plain CT

Anti-tubercular treatment (ATT) was started empirically as tuberculosis of spine is very common in this part of country [3] and patient was taken-up for surgery. In the back drop of long segment collection (D11 to L4), to prevent spinal instability, laminectomy of shorter segment (L1-L2-L3) was done and cranial pus pocket was addressed by Infant Feeding Tube assisted D11-D12 inter-laminar drainage. Approximately 250 ml non-foul-smelling pus was evacuated [Fig 5].

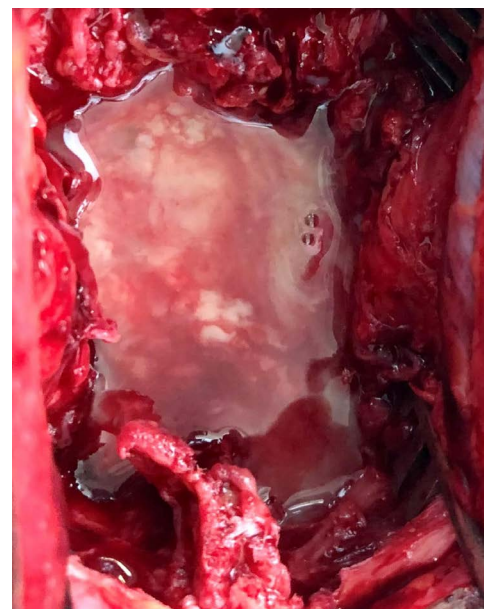

Figure 5: Intra-operative post-laminectomy spinal epidural abscess, communicating with paraspinal collection.

Pig-tail catheter was inserted in the left psoas collection under sonological guidance and approx. 1100 ml pus was drained stat.

Pus had clusters of gram-positive cocci and culture yielded heavy growth of Methicillin-resistant *Staphylococcus aureus* (MRSA) sensitive to Linezolid, Vancomycin and Clindamycin. There were no acid fast bacilli in Ziehl-Neelsen staining of pus. Mycobacterium was detected in Xpert-MTB (nucleic acid amplification) assay of pus. High resolution computed tomography (HRCT) chest was normal. ATT was stopped & patient was administered intra-venous Linezolid. Convalescence was uneventful. Pig-tail catheter was removed on day-6 when residual collection was minimal on ultrasound. Intra-venous Linezolid was continued for 28 days and he was discharged on its oral formulation for next 4 weeks. At 1 month, disability status improved to ASIA grade D. MRI spine had no residual collection (Fig: 6, 7).

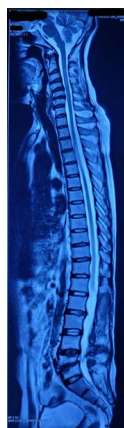


Figure 6: Post-operative screening MRI spine (T2 sequence) sagittal section (status-L1L2L3 laminectomy with drained pus collection).

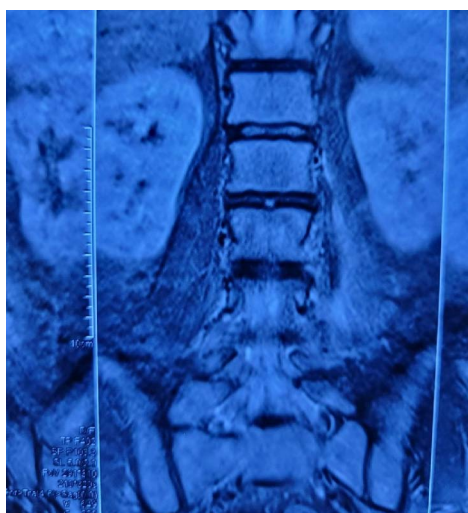


Figure 7: Post-operative MRI spine (T2 sequence) coronal section. Its notable to see the drained left psoas abscess with residual soft tissue edema

At 3-months, patient was ambulatory with help of stick. At 1-year follow-up patient has achieved normal ambulation (ASIA grade E).

Discussion

SEA is an infection of spine where there is accumulation of pus in the epidural space. Its incidence is 1.2/10,000 patients. Backache (75%), fever (48%) and neurologic deficits (33%) constitute the classical triad, which is found in approximately 8% of patients.⁴ It is mostly pyogenic in developed countries and the most common isolated microbe is *Staphylococcus*. But in developing nations like India, *Mycobacterium* is a more common causative organism.³ It damages spinal cord via direct compression, thrombosis and thrombophlebitis of adjacent veins, interruption of arterial blood supply, and/or bacterial toxins.⁴

SEAs are commonly distributed in lumbar & thoracic areas, where epidural space is larger and contains fatty tissue. Bacteria get inoculated into the epidural space via hematogenous route or local seeding from surrounding infection.^{1,5} Single level involvement (70-80%) is commonly seen.^{5,6,7} Immunocompromised states (Diabetes mellitus, IVDA, steroids, chemotherapy), spinal/vascular interventions etc. are common predisposing conditions.^{4,7} Drug abuse downregulates both cellular and humoral immune components of acquired immune system, probably by lymphocyte opiate receptor mediated natural killer T-lymphocyte inactivation. Use of contaminated equipment with non-sterile practice while injecting recreational drugs coalesced with blunted immunity makes abuser vulnerable for infections.⁶ In IVDA-associated SEAs, common pathogens are MRSA (*Methicillin-resistant Staphylococcus aureus*) and MSSA (*Methicillin-sensitive Staphylococcus aureus*).^{1,5}

With an annual turnover of approx. \$500 billion, drug business globally ranks third, next to petroleum and ammunitions in world trade. Around 190 million people all over the world are drug abusers. As per reports, India itself has got dreadful figure of approx. 1 million registered heroin addicts and unofficially as many as 5 million.⁸

Psoas abscess in another rare entity with incidence of 12/100,000 population.² There is collection of pus within iliopsoas muscle. It can be primary (hematogenous) or secondary (infection in-contiguity). *Staphylococcus* is the commonest pathogen in primary PA while members of *Enterobacteriaceae* (developed nations) or, *Mycobacterium* (developing world) are isolated from the culture from secondary PA.^{2,9} Triad of fever, flank pain and restricted hip movement is seen in 30% of patients. Intra-peritoneal rupture leads to septic shock/ fatal peritonitis with 50-100% mortality rate.⁹

Clinical suspicion forms the foundation of diagnostic work-up for SEA & PA both. Contrast (Gadolinium) enhanced magnetic resonance imaging (CEMRI) has more than 90% sensitivity and specificity in diagnosing SEA and is the gold standard.^{5,9} It is also diagnostic for PA.^{2,9} Supportive investigations like erythrocyte sedimentation rate (ESR), C-reactive protein (CRP) are raised in both SEA & PA. Roentgenogram (X-ray) findings are non-specific in SEA. Sclerotic changes of bony structures of vertebral column and surrounding soft tissue edema are found in chronic/late stages.⁷

Depending upon clinical presentation SEA can be managed both medically or surgically in both IVDA and non-IVDA groups. There is no fixed guideline regarding selection

of antibiotic. Empirically, it should be broad-spectrum and effective against *Staphylococcus aureus*, with low toxicity enabling it for prolonged intra-venous administration over 4-6 weeks with bony penetration (to treat spondylodiscitis).^{7,10} Surgical indications are failed medical treatment, newly diagnosed kyphotic deformity (secondary to spondylodiscitis) of more than 11o in cervical spine or 20o in thoraco-lumbar spine or, neurological compromise.^{1,5,6} Surgical modalities can be imaging-guided per-cutaneous drainage, laminotomy, laminectomy (most commonly used) or, corpectomy; with or without instrumentation.^{2,5,7} Precise indication of instrumentation and fusion in IVDA-SEA sub-group is still controversial owing to low volume and poor follow-up, but compromised spinal integrity leaves the surgeon with no other choice than to fix it up.^{1,11}

Treatment of psoas abscess (PA) ranges from immobilization coupled with antibiotics/anti-tubercular treatment with or without abscess drainage, depending upon volume of abscess and patient's fitness for anaesthesia and surgery. Surgical options are imaging (ultrasound/ computed tomography) guided aspiration, catheter/drain insertion or, extra-peritoneal (open/endoscopic) drainage.^{2,9,12}

Conclusion

Spinal and retro-peritoneal abscesses are common presentations of tuberculosis of the vertebral column in Indian sub-continent. However purulent collections at uncommon anatomical locations in the spinal column should raise a suspicion of bacterial abscess, other than tuberculosis and drug abuse should be investigated in the clinical history of the patient.

Reference

1. DiGiorgio AM, Stein R, Morrow KD, Robichaux JM, Crutcher CL, Tender GC. The increasing frequency of intravenous drug abuse-associated spinal epidural abscesses: a case series. *Neurosurg Focus*. 2019;46(1):E4. doi:10.3171/2018.10.FOCUS18449
2. Shoakazemi A, Amit A, Nooralam N, Abouharb A, Gormley M, McKinstry S. Panspinal epidural and psoas abscess with secondary cervical disc space infection. *Ulster Med J*. 2013;82(1):23-25
3. Diyora B, Patil S, Bhende B, Patel M, Dhall G, Nayak N. Concurrent Spinal Epidural Tubercular and Pyogenic Abscess of Cervical Spine without Bony Involvement. *J Neurosci Rural Pract*. 2019;10(2):374-378. doi:10.4103/jnrp.jnrp_318_18
4. Ameer MA, Knorr TL, Mesfin FB. Spinal epidural abscess. *InStatPearls [Internet]* 2021 Feb 11. StatPearls Publishing
5. Ziu M, Dengler B, Cordell D, Bartanusz V. Diagnosis and management of primary pyogenic spinal infections in intravenous recreational drug users. *Neurosurg Focus*. 2014;37(2):E3. doi:10.3171/2014.6.FOCUS14148
6. Wang Z, Lenehan B, Itshayek E, et al. Primary pyogenic infection of the spine in intravenous drug users: a prospective observational study. *Spine (Phila Pa 1976)*. 2012;37(8):685-692. doi:10.1097/BRS.0b013e31823b01b8
7. Reihnsaus E, Waldbaur H, Seeling W. Spinal epidural abscess: a meta-analysis of 915 patients. *Neurosurg Rev*. 2000;23(4):175-205. doi:10.1007/pl00011954
8. Sharma B, Arora A, Singh K, Singh H, Kaur P. Drug abuse: Uncovering the burden in rural Punjab. *J Family Med Prim Care*. 2017;6(3):558-562. doi:10.4103/2249-4863.222037
9. Martins DLN, Cavalcante Junior FA, Falsarella PM, Rahal Junior A, Garcia RG. Percutaneous drainage of iliopsoas abscess: an effective option in cases not suitable for surgery. *Einstein (Sao Paulo)*. 2018;16(3):eRC4254. Published 2018 Sep 21. doi:10.1590/S1679-45082018RC4254
10. Alexandre AR, Raimundo P. Epidural, paravertebral and bilateral psoas abscess after lumbar acupuncture. *BMJ Case Rep*. 2018;11(1):e228047. Published 2018 Nov 28. doi:10.1136/bcr-2018-228047
11. Bydon M, De la Garza-Ramos R, Macki M, et al. Spinal instrumentation in patients with primary spinal infections does not lead to greater recurrent infection rates: an analysis of 118 cases. *World Neurosurg*. 2014;82(6):e807-e814. doi:10.1016/j.wneu.2014.06.014
12. Iida K, Yoshikane K, Tono O, Tarukado K, Harimaya K. The effectiveness of a percutaneous endoscopic approach in a patient with psoas and epidural abscess accompanied by pyogenic spondylitis: a case report. *Journal of Medical Case Reports*. 2019 Dec;13(1):1-6. doi:10.1186/s13075-019-1708-8