


Anti- NMDAR Encephalitis in a 28 years old female: Revisited



Rajiv Jha¹ , Pankaj Jalan² , Rajiv Shah³ , Adarsha Chaturvedi⁴ 

^{1,4}National Academy of Medical Sciences, Bir Hospital, Mahaboudha, Kathmandu, Nepal

²Norvic International Hospital, Thapathali, Kathmandu, Nepal

³Bhaktapur Cancer Hospital, Bhaktapur

Date of submission: 17th July 2023

Date of acceptance: 28th September 2023

Date of publication: 15th October 2023

Abstract

Anti-N-methyl-D-aspartate receptor (NMDAR) encephalitis is the prevailing subtype of autoimmune encephalitis, commonly misdiagnosed initially as infectious encephalitis due to its symptomatology resembling that of viral encephalitis and meningitis. The condition exhibits a higher incidence in females, with a gender ratio of 4:1 compared to males. While electroencephalogram (EEG) and magnetic resonance imaging (MRI) aid in the diagnostic process, the presence of antibodies in the cerebrospinal fluid (CSF) serves as the definitive confirmation. Autoimmune encephalitis typically presents with a spectrum of neuropsychiatric symptoms.

Introduction

Anti-N-methyl-D-aspartate (NMDA) receptor encephalitis is a prevalent form of autoimmune encephalitis. However, the clinical presentation varies, and the disease often follows a nonsequential multiphasic course, leading to diagnostic delays.¹ NMDA receptors are ion channels involved in synaptic transmission and plasticity. They consist of NR1 and NR2 subunits, which bind glycine and glutamate, respectively. Excessive receptor activity leads to excitotoxicity seen in acute ischemic stroke and traumatic brain injury, while insufficient activity is associated with symptoms of schizophrenia. In anti- NMDA receptor encephalitis, antibodies target and reduce the number of NMDA receptors on post-synaptic dendrites, impacting their function.²

Anti-NMDA receptor encephalitis is a severe form of encephalitis primarily affecting women. It is characterized by psychotic symptoms, motor changes like catatonia, seizure like activity, and dyskinesias. Behavioral changes, autonomic dysfunction, and impaired consciousness are also observed.³

Although ovarian teratomas and viral infections, particularly herpes simplex viruses, have been identified as triggers for anti-NMDA receptor encephalitis, the precise cause remains unclear in many cases. The detection of anti- NMDA receptor antibodies in cerebrospinal fluid (CSF), along with other abnormalities observed in CSF analysis, electroencephalography (EEG), or magnetic resonance imaging (MRI), often aids in confirming the diagnosis.⁴ Brain MRI appears normal in a significant proportion of patients, up to 67%. On the other hand, EEG abnormalities are observed in 90% of individuals. The EEG findings are often nonspecific, characterized by background slowing, disorganization, and the presence of electrographic seizures. The definitive diagnosis is established by detecting the presence of NMDAR antibodies in the cerebrospinal fluid (CSF).⁶

In the cerebrospinal fluid (CSF) or serum of individuals affected by this condition, one can detect antibodies generated by body's own immune system that target N-methyl-D-aspartate (NMDA) receptors. While it is possible for this disorder to be triggered by a virus, vaccination, or tumor, the underlying cause frequently remains elusive. Treatment options encompass first-line immunotherapies, including steroids, intravenous immunoglobulin (IVIG), or plasmapheresis (also known as plasma exchange). In cases where the initial treatments prove inadequate, second-line immunotherapies such as rituximab or cyclophosphamide may be employed.⁵

Access this article online

Website: <https://www.nepjol.info/index.php/NJN>

DOI: <https://doi.org/10.3126/njn.v20i3.56715>

HOW TO CITE

Jha R, Jalan P, Shah R, Chaturvedi A. Anti- NMDAR Encephalitis in a 28 years old female: Revisited: Anti - NMDAR Encephalitis. NJNS. 2023;20(3):70-72.



Address for correspondence:

Prof. Rajiv Jha

National Academy of Medical Sciences, Bir Hospital, Mahaboudha, Kathmandu, Nepal

E-mail: medrajiv18@gmail.com

Copyright © 2023 Nepalese Society of Neurosurgeons (NESON)

ISSN: 1813-1948 (Print), 1813-1956 (Online)



This work is licensed under a Creative Commons Attribution-Non Commercial 4.0 International License.

Case presentation

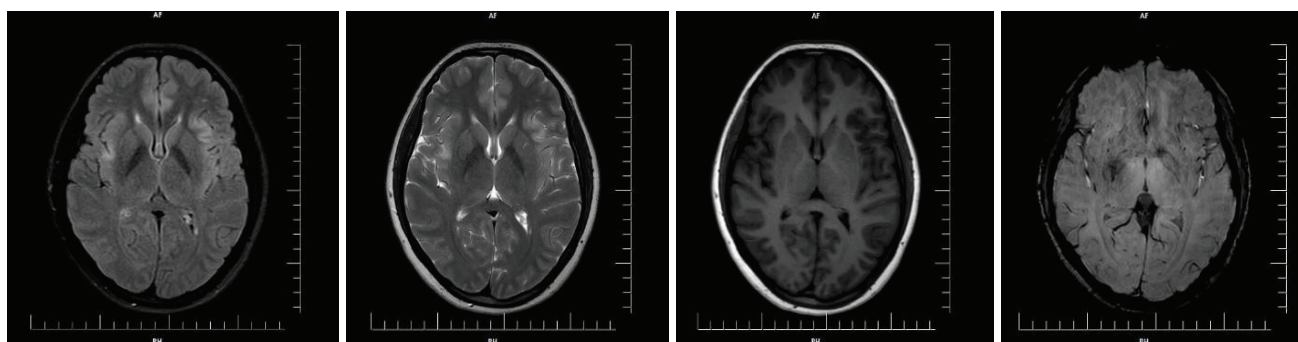
This is a case of a 28-year-old female with an unremarkable medical history who presented to the Emergency Department. Her family reported that she displayed restless behavior, fear, mood changes, and multiple episodes of acute seizures. Additionally, her family noticed short-term memory loss, inability to recognize family members, and associated hallucinations. Her mental state deteriorated, leading to an altered level of consciousness characterized by a fixed staring gaze. The patient did not experience any preceding symptoms such as fever or flu-like illness. There was no evidence of substance abuse, and her family had no history of autoimmune diseases.

During the examination, the patient exhibited disorientation to time, place, and person. She had a fixed staring gaze and produced incomprehensible sounds while responding to painful stimuli (Glasgow Coma Scale E4V2M5). Bilateral Babinski's reflex was elicited, showing downward movement. Both pupils were 3 mm in size and reacted to light. The patient did not exhibit neck rigidity, Kernig's sign, or Brudzinski's sign. However, her vegetative symptom (sinus tachycardia) was typical for anti-NMDA receptor encephalitis, possibly caused by catecholaminergic hyperstimulation, similar to the well-known ketamine effects.⁷

The patient was admitted to the Intensive Care Unit with a provisional diagnosis of encephalitis. Empirical antibiotics and acyclovir were initiated as treatment. Infective encephalitis was initially suspected, but a cerebrospinal fluid (CSF) analysis yielded negative results

for infectious causes. The CSF culture did not show the growth of any organisms. An initial electroencephalogram (EEG) showed fast beta activity in the background with intermittent slow waves in the theta range, which did not provide a definitive conclusion. A normal CT scan was followed by a Magnetic Resonance Imaging (MRI) study, which revealed small areas of increased signal intensity in the bilateral frontal and parietal deep cortical white matter without restricted diffusion. Tumor markers were also evaluated but did not indicate any abnormalities. The possibility of autoimmune encephalitis was considered, leading to the submission of the patient's CSF for an autoimmune panel to detect antibodies. Surprisingly, the results were positive for the NR1 subunit of the NMDA receptor. Since teratomas are commonly associated with Anti-NMDAR Encephalitis, an abdominal and pelvic contrast-enhanced computed tomography (CECT) scan was performed, revealing a cystic lesion measuring 6.1 * 6.1 * 7.6 cm in the right adnexa, suggestive of a dermoid cyst.

As part of the initial treatment, a course of methylprednisolone was initiated for five days. However, the patient continued to experience orofacial dyskinesias, hallucinations, and exhibited mutism. Subsequently, an exploratory laparotomy with right ovarian cystectomy was performed, and intraoperative findings confirmed the presence of a dermoid cyst. Following the surgery, the patient's clinical condition gradually improved. The orofacial dyskinesias significantly reduced, and she began to express herself verbally more frequently. Due to the recurrence of seizures, the patient was prescribed long-term antiepileptic drugs (AEDs).



Subtle T2 and FLAIR hyperintensity in bilateral anterior insula and left inferolateral frontal cortices without evidence of diffusion restriction.

Discussion

Anti-NMDAR Encephalitis is the most common autoimmune encephalitis which is increasing in incidence over the years. Patients usually present with Neuropsychiatric symptoms ranging from speech dysfunction, disorganized thoughts, decreased level of consciousness, cognitive dysfunction, orofacial dyskinesia to memory loss along with psychiatric symptoms like agitation, delusions, hallucinations, emotional liability, catatonia. It is usually caused in young women and almost invariably paraneoplastic in origin, associated with some form of germ cell tumors, mostly arising from ovaries, also called teratomas. Prodromal symptoms such as low-grade fever, headache, common cold like symptoms and gastroenteritis are commonly observed. Since its identification in 2007, global case studies have significantly improved our understanding of its epidemiology and clinical presentation, with a particular focus on enhancing immunotherapy and overall prognosis.⁸ Early diagnosis and appropriate treatment can lead to a favorable prognosis in a subset of patients with anti-NMDAR receptor encephalitis. The recovery period for cases achieving complete recovery varies, spanning from several months to several years.⁹

Anti-NMDAR encephalitis, although it can be severe and life threatening, is potentially reversible, and the majority of patients experience recovery if the condition is identified and treated promptly. Optimal outcomes are typically achieved through a combination of tumor removal, immunotherapy (such as IV steroids, IV immunoglobulin, or plasma exchange), and in certain cases, additional treatment with cyclophosphamide and rituximab has shown effectiveness.¹⁰

Conclusion

Although infrequent, Anti-NMDAR Encephalitis begs a question regarding its identification and potential treatability. Although the initial symptoms are similar to that of infective causes of encephalitis, it is only confirmed by detection of antibodies in serum or CSF. EEG and diagnostic approaches such as Computed Tomography and Magnetic Resonance Imaging may not give definite lead towards diagnosis. Variety of Neuropsychiatric symptoms may be present varying from case to case, usually occurring in children and young adults particularly in women. Typically associated with germ cell tumor,

ovarian or testicular teratoma, treatment ranges from primary removal of tumor along with immunotherapy to rituximab and cyclophosphamide modulation.

References

1. Ford B, McDonald A, Srinivasan S. Anti-NMDA receptor encephalitis: a case study and illness overview. *Drugs in context*. 2019;8.
2. Chapman MR, Vause HE. Anti-NMDA receptor encephalitis: diagnosis, psychiatric presentation, and treatment. *American Journal of Psychiatry*. 2011 Mar;168(3):245-51.
3. Barry H, Hardiman O, Healy DG, Keogan M, Moroney J, Molnar PP, Cotter DR, Murphy KC. Anti-NMDA receptor encephalitis: an important differential diagnosis in psychosis. *The British Journal of Psychiatry*. 2011 Dec;199(6):508-9.
4. Endres D, Rauer S, Kern W, Venhoff N, Maier SJ, Runge K, Süß P, Feige B, Nickel K, Heidt T, Domschke K. Psychiatric presentation of anti-NMDA receptor encephalitis. *Frontiers in neurology*. 2019 Nov 5;10:1086.
5. Wang H. Anti-NMDA receptor encephalitis and vaccination. *International journal of molecular sciences*. 2017 Jan 18;18(1):193.
6. Bartolini L. Practice current: how do you treat anti-NMDA receptor encephalitis?. *Neurology: Clinical Practice*. 2016 Feb 1;6(1):69-72.
7. Endres D, Rauer S, Kern W, Venhoff N, Maier SJ, Runge K, Süß P, Feige B, Nickel K, Heidt T, Domschke K. Psychiatric presentation of anti-NMDA receptor encephalitis. *Frontiers in neurology*. 2019 Nov 5;10:1086.
8. Espinola-Nadurille M, Flores-Rivera J, Rivas-Alonso V, Vargas-Cañas S, Fricchione GL, Bayliss L, Martinez-Juarez IE, Hernandez-Vanegas LE, Martinez-Hernandez R, Bautista-Gomez P, Solis-Vivanco R. Catatonia in patients with anti-NMDA receptor encephalitis. *Psychiatry and Clinical Neurosciences*. 2019 Sep;73(9):574-80.
9. Wang H. Efficacies of treatments for anti-NMDA receptor encephalitis. *Frontiers in Bioscience-Landmark*. 2016 Jan 1;21(3):651-63.
10. Braakman HM, Moers-Hornikx VM, Arts BM, Hupperts RM, Nicolai J. Pearls & Oy-sters: electroconvulsive therapy in anti-NMDA receptor encephalitis. *Neurology*. 2010 Sep 7;75(10):e44-6.