


# Intraventricular Meningiomas - Case Series and Review of Literature

Anand Shanmugaiah<sup>1</sup> , Raj Kumar R<sup>2</sup> <sup>1,2</sup> Institute of Neurosurgery, Madras medical collegeDate of submission: 19<sup>th</sup> April 2023Date of Acceptance: 28<sup>th</sup> June 2023Date of Publication: 15<sup>th</sup> July 2023

## Abstract

**Introduction:** Meningioma is the most common benign primary intracranial tumour after glioma. Meningioma occurring in intraventricular region is very rare. When located in intraventricular space, majority of intraventricular meningioma (IVM) are located in lateral ventricles.

**Material and methods:** This is a Study of four cases of intraventricular meningioma in Madras medical College from January 2022 to December 2022. In this study, the symptoms, MRI findings, operative procedure, histology images, surgical outcomes and a detailed review is done from various literature.

**Results:** Among the various symptoms, headache, disturbance in vision, changes in cognition and speech disturbance were commonly found. The site of all the lesion was in the lateral ventricle. MRI was used to confirm the diagnosis before surgery. In our patients, the intraventricular meningioma was completely excised via parietal craniotomy or temporoparietal craniotomy based on the location of the tumour. The tumour was completely excised in all four patients. Histologically it was meningothelial meningioma in all 4 patients.

**Conclusion:** From our case series we observed that all the IVM were WHO grade I and total excision is possible in intraventricular meningiomas with properly planned surgical trajectory with minimum post operative morbidity.

**Key words:** Intraventricular, Meningioma, Parietal approach, temporoparietal approach, Total Excision, Outcome.

## Introduction

Of all primary intracranial neoplasms, meningiomas are the most common benign intracranial tumour following glioma with incidence of 35.9%<sup>1</sup>. Female predominance is seen in meningiomas with a ratio of about 2.1. Meningiomas are extra axial except when they occur within the ventricles which is intraaxial, which is a very rare type. It represents only 1-2 % of all meningiomas<sup>2</sup>. The most common location of IVM is left lateral ventricular trigone<sup>3</sup>. There are three features which

differentiates intraventricular meningiomas from other meningiomas. First, location of these are extremely rare compared to other meningiomas. Second, intraventricular meningiomas have no dural attachment. And third, due to their location it is very difficult to do complete excision without complications like damaging the optic radiation leading to visual field defect<sup>5</sup>. As per a recent study, these patients with IVM does not present early when the tumour is small due to the enough room the ventricular system provides for the tumour to grow large enough to produce symptoms. Symptoms of elevated intracranial pressure including headache, vomiting, visual disturbance, impaired cognition would be seen in larger lesions<sup>3,4</sup>. A study conducted by Danica Grujicic et al. on a larger case series of 42 patients also showed that symptoms of raised ICP was seen in 83% of the patients, Visual disturbance in 78.6% and impaired cognition seen in 50%. Surgical total excision is the goal for intraventricular meningiomas. Transcortical parieto-occipital and transtemporal routes for sufficient, safe resection of IVM have been recommended in studies conducted by Grujicic, Ma and Nanda<sup>6,8,9</sup>. The rarity of pathology, specifically in our population is clearly depicted with the availability of limited research papers. In this study of case series, we present 4 patients with intraventricular meningiomas, the clinical symptoms, CT/MRI findings, treatment strategy, outcome and we reviewed with various available literature for better understanding of this condition.

### Access this article online

Website: <https://www.nepjol.info/index.php/NJN>DOI: <https://doi.org/10.3126/njn.v20i2.54255>

### HOW TO CITE

Shanmugaiah A, Rajkumar, V.T. Suresh babu. Intraventricular Meningiomas: Case series and Review of Literature. NJNS. 2023;20(2):57-61.



### Address for correspondence:

Anand Shanmugaiah

Post graduate in Neurosurgery

Madras Medical College

E-mail: anand29browsing@gmail.com

Copyright © 2023 Nepalese Society of Neurosurgeons (NESON)

ISSN: 1813-1948 (Print), 1813-1956 (Online)



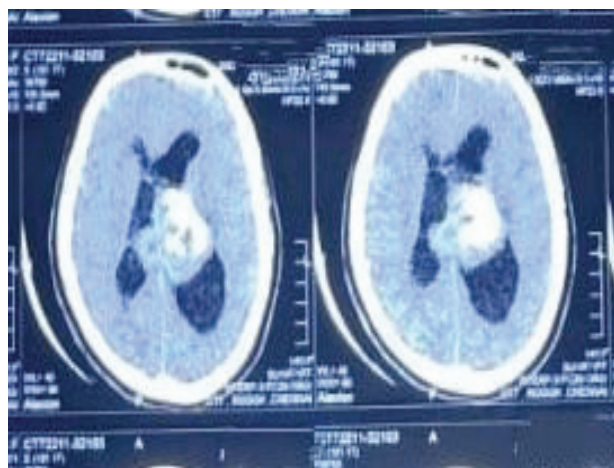
This work is licensed under a Creative Commons Attribution-Non Commercial 4.0 International License.

## Material and Methods

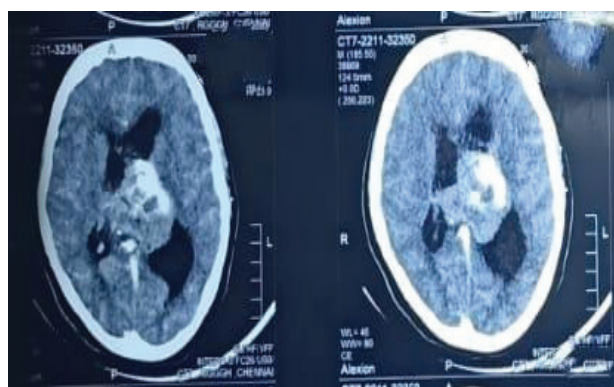
This is a retrospective study of 4 patients with intraventricular meningioma from January 2022 to december 2022 at madras medical college. Out of 4 patients, 2 were male and 2 female. Mean age at presentation was 40 years. The clinical symptoms, MRI findings, operative procedure done and complications, histological features were analyzed in these 4 patients. Preoperative work up was done including CT, Gadolinium enhanced MRI in all 4 patients. All 4 patients underwent surgical excision of the tumour by using either parieto-occipital (1 case ) and parieto-temporal(3 cases) approaches. Intraventricular meningioma was confirmed histopathologically in all 4 cases according to WHO grading. Glasgow Outcome Scale (GOS) was used to analyze the outcome. We have reviewed various literature starting from January 2003 to december 2021 and analysed with our study of case series. From these various literature which was reviewed, Age at presentation, sex, presenting symptoms, MRI findings, treatment done and complications was analysed.

## Results

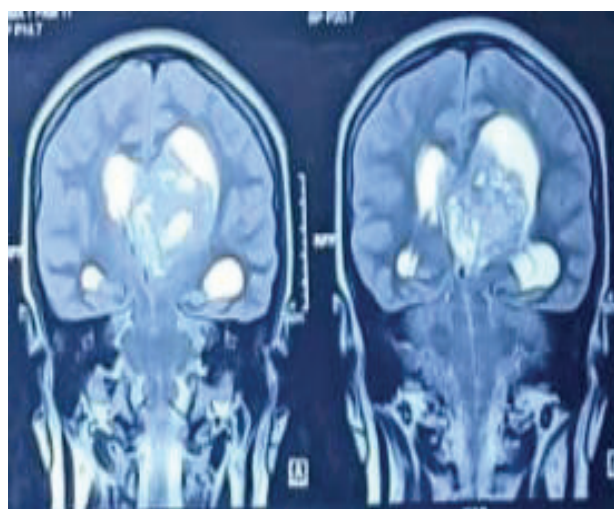
In our case series, four patients with intraventricular meningioma were analysed. The mean age of presentation to the hospital was 40 years with a range of 38-42 years. In our case series there were two male and two female with ratio of 1:1. The commonest symptoms with which patient came to our hospital was headache seen in all 4 patients followed by nausea/vomiting seen in 3 patients, visual disturbance in 2 patients, impairment of cognition and speech disturbance in one patient. In our case series, the symptoms was present ranging from 2-6 months. Papilledema was seen in 3 cases and contralateral homonymous hemianopia seen in two patients. Admission Ct brain and MRI with contrast done in all 4 cases and the intraventricular meningioma was confirmed. Tumour calcification on CT brain was seen in all 4 cases in our study. In our case series of 4 patients with IVM, the tumour was found to be originating from lateral ventricles on MRI. On T1WI MRI, the tumour was hypointense and gadolinium contrast enhancing in all 4 cases. In our stude of 4 case series, the tumour size was 3cm-6cm, with a mean size of 4 cms. Total excision was done in all 4 patients via the transparieto-occipital approach in two patients and transtemporal approaches in two patients. During the post operative period, CSF leakage was seen in 1 case and hemiparesis was seen in 1 case and dysphasia in 1 case. In our study series there was no mortality. Biopsy report of all 4 cases showed meningotheial meningioma( WHO grade I).



*Image 1: Ct brain plain - arrow mark showing heterodense lesion in left lateral ventricle*



*Image 2: Contast CT brain showing contrast enhancing lesion in left lateral ventricle with extention into right lateral ventricle*



*Image 3: T2 Coronal MRI brain showing heterointense lesion involving left lateral ventricle and extending into right lateral ventricle causing dilatation of left lateral ventricle*

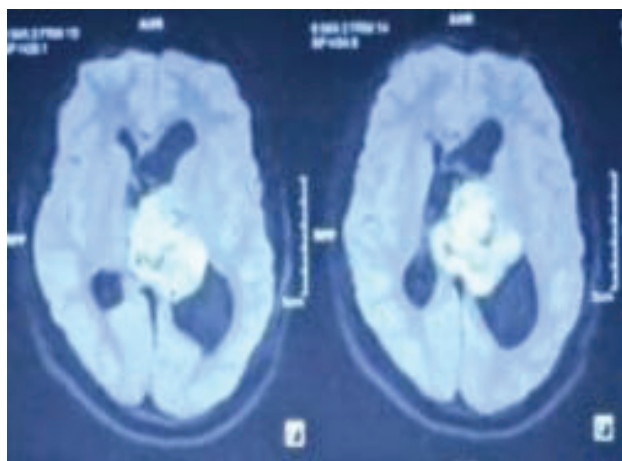


Image 4: DWI MRI showing diffusion restriction

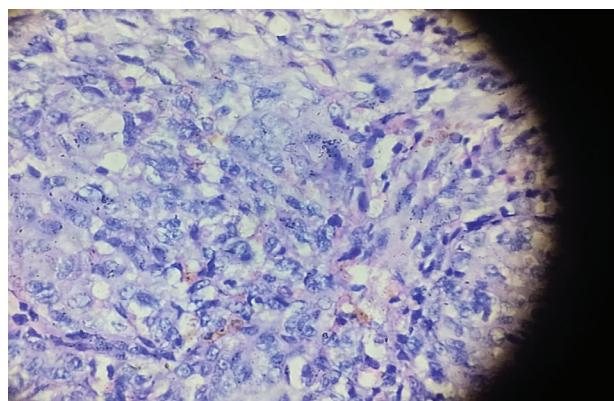


Image 5 : Histopathology showing spindle-shaped tumor cells, with narrow rod-shaped nuclei and the cells are embedded in abundant collagenous background

Table 1: Demography and presentation of various case series from 2003-2021

AUTHORS	CASES N	SEX M:F	AGE RANGE	SYMPTOMS				SIGNS	
				H/A	N/V	SD	IC	PE	VFD
Nakamura et al. 2003	16	1:1	25-77	8	-	3	2	4	7
Bhatoe et al. 2006	12	3:1	30-50	12	-	-	-	8	-
Lyngdoh et al. 2007	9	1:1.3	12-60	7	7	3	4	8	4
Menon et al. 2009	15	1:2	14-75	10	-	-	-	10	6
Ødegaard et al. 2012	22	1:2.7	26-81	16	9	-	-	-	2
Ma et al. 2014	43	1:2.6	14-61	23	4	2	2	-	4
Faquini et al. 2015	4	1:3	17-45	4	-	-	-	3	1
Nanda et al. 2016	18	1:1.25	26-87	11	1	-	-	8	2
Grujicic et al. 2017	42	1:2.5	1-67	35	35	-	21	35	31
Siddiqui UF et al. 2021	15	2:1	27-50	15	10	4	4	10	6
Present study	4	1:1	38-42	4	3	1	1	3	2
Total	200	1:2	1-87	145	69	13	34	89	65

H/A= headache; N/V = nausea/vomiting; SD= speech difficulty; IC= impaired cognition; VFD = visual field defects; PE = papilledema

Table 2: Location, operative approach and outcome of various case series from 2003-2021.

Authors	Cases N	Location	Side	Size cm	HCP	Surgical approach	Total removal	Recurrence	Mortality
Nakamura et al. 2003	16	L=13, III=1 IV=2	Lt=9 Rt=4	2-7	14	PO=10 TC=3 FT=1 SO=2	15	1	-
Bhatoe et al. 2006	12	L=9 III=1 IV=2	Lt=7 Rt=2	-	-	PO=9 FT=1 SO=2	12	-	1
Lyngdoh et al. 2007	9	L=7, IV=2	Lt=5 Rt=2	4.5- 7.4	8	PO=2 TT=5 SO=2	8	-	0
Menon et al. 2009	15	L=15	Lt=8 Rt=7	-	-	PO=11 TT=4	13	2	-
Ødegaard et al. 2012	22	L=20, III=1 IV=1	Lt=8 Rt=12	1.9-7	11	PO=20 FT=1 SO=1	21	1	-
Ma et al. 2014	43	L=43	Lt=16 Rt=27	1.7- 8.2	6	PO TT	43	0	-
Faquini et al. 2015	4	L=4	Lt=1 Rt=3	>3	3	PO=4	4	0	0



Nanda et al. 2016	18	L=15, IV=3	Lt=8 Rt=7	-	8	PO=12 TT=1 TC=1 SO=3	17	4	-
Grujicic et al. 2016	42	L=40, III=2	Lt=25 Rt=15	1-10	-	PO=20 TT=7 TP=12 TC=3	39	1	0
Siddiqui UF et al. 2021	15	L=15	Lt=8 Rt=7	3-7	10	PO=8 TT=7	13	-	0
Present study	4	L=4	Lt=3 Rt=1	3-6	2	PO=2 TT=2	4	-	0
Total	200	L=185 III=5 IV=10	Lt=98 Rt=87	1-10	62	PO=98 TT=26 TP=12 TC=7 FT=3 SO=10	189	9	1

HCP= hydrocephalus; L= lateral ventricle PO= parieto-occipital; TT= trans-temporal; TC= transcallosal; FT= frontal transcortical; TP= temporo-parietal; SO= suboccipital

## Discussion

Though meningiomas are most common, intraventricular meningiomas are a very rare type and there are limited number of published clinical series. IVM was first described by Shaw in 1854<sup>10</sup>. Various studies including the study conducted by Harvey Cushing, Delandsheer, Nakamura et al, Grujicic et al, Crisculo and Symon, identified a total of 617 cases of intraventricular meningiomas<sup>2,6,8</sup>. Of these 617 cases, lateral ventricles was found to be commonest location for IVM accounting for 85% followed by third ventricle and fourth ventricle. The various findings of the published case series of patients with IVMs since 2003 has been summarised in table 2. The tumour arises from choroid plexus and later on extends into the lumen of the ventricle. The anterior or posterior choroidal arteries, enters tumor. Trigone is drained by the medial and lateral atrial veins<sup>7</sup>. Optic radiation pass over the roof and the lateral wall of the temporal horn as well as on the inferolateral aspect of the atrium. There is female predominance for IVMs, with ratio of 2:1 for female-to-male<sup>15</sup>. In our series of 4 cases there was 2 males and 2 females with a ratio of male to female of 1:1. Further risk increases as age progresses<sup>16</sup>. In our series, the age ranged from 38-42 years and the mean age was 40 years. Intraventricular meningioma present late as it gradually enlarges in size unless it is causing obstruction to CSF flow. Five clinical presentations of IVMs in trigone has been described by Cushing and Eisenhardt in 1938: (1) symptoms of elevated ICP; (2) contralateral homonymous hemianopia; (3) contralateral sensorimotor deficit (4) cerebellar affection and (5) dysphasia in left-sided tumors<sup>11</sup>. In our case series, the clinical presentations complies with these theories. According to various studies, the duration of symptoms ranged from a few months up to 20 years<sup>11</sup>. In our case series, the duration of symptoms were 2 to 6 months. Various diagnostic modalities have been attributed in the literature yet currently MRI is the diagnostic modality of

choice as it gives detailed brain anatomy, lesion location and surgical planning. In the study conducted by Crisculo and Symon in 400 patients with IVMs, 80% IVMs found to arise within lateral ventricle followed by third in 15% and fourth ventricle in 5%<sup>13</sup>. In our case series, all of the IVMs were found to arise from lateral ventricles. According to various literature, IVMs were found to be more common on the left side, as shown in Table-2. In our case series, 3 patients had left sided IVMs and 1 patient had right sided IVM. Radiologically IVMs are well circumscribed lesion without a dural attachment<sup>18</sup>. On CT scan, IVM are usually hyperdense with contrast enhancement and may have calcified areas (47%) and hydrocephalus<sup>6,15</sup>. In our case series, calcifications were seen in all 4 cases and hydrocephalus was seen in 2 patients (50%) which correlates with the study by Odegard et al and Nanda et al series (50, 44%) as in Table-2. In our case series, the MRI findings were similar as reported in literature; T1 iso to hypointense and T2 hyperintense along with dense enhancement on contrast<sup>19</sup>. According to various literature, the treatment of choice for IVMs is total excision of the tumour. Total excision is relatively challenging owing to its deep location, the proximity of motor, sensory, and language cortex, plus optic radiation and the vascular structures. In our series, tumor resection was done via parieto-occipital (PO) approach in 2 patients and transtemporal (TT) approach in 2 patients. Moreover these approaches were the most commonly employed routes in literature of 196 IVM resections in last 15 years with parieto occipital route in 49% and Transtemporal route in 12%. In our cases, total excision was accomplished in all 4 patients (100%) comparable with Grujicic et al and Nanda et al (93%, 94%) as shown in Table-2. As per Grujicic et al, mortality rates ranged from 0 to 42% in previous case series. Subsequently, there is a significant decline in the operative mortality in last 15 years. In our series of 4 patients, surgical mortality was 0%. On 3 month follow-up, 75% showed Glasgow Outcome Score of 5 which is comparable with Grujicic et al series (83.3%)<sup>6</sup>.

## Conclusion

Intraventricular meningiomas are a rare type which presents late until it acquires larger dimensions. MRI brain with contrast is the investigation of choice. Total excision should be the goal. The main challenge is to resect IVMs in the trigone without damaging the geniculocalcarine tracts. Hence, the surgical approach should be precisely planned, in accordance with tumor location. Parieto-occipital and trans-temporal approaches are the most commonly recommended surgical routes.

## References

- Ostrom QT, Gittleman H, Fulop J, Liu M, Blanda R, Kromer C, et al. CBTRUS statistical report: primary brain and central nervous system tumors diagnosed in the United States in 2008-2012. *Neuro Oncol*. 2015 Oct;17;Suppl 4:iv1-iv62. doi: 10.1093/neuonc/nov189, PMID 26511214.
- Nakamura M, Roser F, Bundschuh O, Vorkapic P, Samii M. Intraventricular meningiomas: a review of 16 cases with reference to the literature. *Surg Neurol*. 2003;59(6):490-503. doi: 10.1016/S0090-3019(03)00082-X.
- Lyngdoh BT, Giri PJ, Behari S, Banerji D, Chhabra DK, Jain VK. Intraventricular meningiomas: A surgical challenge. *J Clin Neurosci*. 2007;14(5):442-8. doi: 10.1016/j.jocn.2006.01.005, PMID 17350844.
- Bhatoe HS, Singh P, Dutta V. Intraventricular meningiomas: A clinicopathological study and review. *Neurosurg Focus*. 2006 Mar 15;20(3):E9. doi: 10.3171/foc.2006.20.3.10, PMID 16599425.
- Menon G, Nair S, Sudhir J, Rao R, Easwer HV, Krishnakumar K. Meningiomas of the lateral ventricle – a report of 15 cases. *Br J Neurosurg*. 2009;23(3):297-303. doi: 10.1080/02688690902721862, PMID 19533463.
- Grujicic D, Cavallo LM, Somma T, Illic R, Milicevic M, Raicevic S et al. Intraventricular meningiomas: A series of 42 patients at a single institution and literature review. *World Neurosurg*. 2017 Jan;97:178-88. doi: 10.1016/j.wneu.2016.09.068, PMID 27686504.
- Faquini I, Fonseca RB, Vale de Melo SLV, Negri H, Vieira E, Saboia T, et al. Trigone ventricular meningiomas: is it possible to achieve good results even in the absence of high tech tools? *Surg Neurol Int*. 2015 Nov 26;6:180. doi: 10.4103/2152-7806.170540, PMID 26674002.
- Ma J, Cheng L, Wang G, Lin S. Surgical management of meningioma of the trigone area of the lateral ventricle. *World Neurosurg*. 2014 Nov;82(5):757-69. doi: 10.1016/j.wneu.2014.05.026, PMID 24878623.
- Nanda A, Bir SC, Maiti T, Konar S. Intraventricular meningioma: technical nuances in surgical management. *World Neurosurg*. 2016 Apr;88:526-37. doi: 10.1016/j.wneu.2015.10.071, PMID 26548837.
- Shaw A. Fibrous tumour in the lateral ventricle of the brain, bony deposits in the arachnoid membrane of the right hemisphere. *Trans Pathol Soc Lond*. 1853-1854;5:18-21.
- Cushing H, Eisenhardt L, Schlesinger EB. Meningiomas: Their Classification, Regional Behaviour, Life History, and Surgical End Results. *JAMA*. 1939;112(2):175. doi: 10.1001/jama.1939.02800020081030.
- Delandsheer JM. Meningiomas of the lateral ventricle. *Neuro-Chirurgie*. 1965;11:3-83. PMID 14306954.
- Crisuolo GR, Symon L. Intraventricular meningioma. A review of 10 cases of the National Hospital, Queen Square (1974-1985) with reference to the literature. *Acta Neurochir*. 1986;83(3-4):83-91. doi: 10.1007/BF01402383, PMID 3492867.
- Kepes JJ. Presidential address: the histopathology of meningiomas. A reflection of origins and expected behavior?. *J Neuropathol Exp Neurol*. 1986;45(2):95-107. doi: 10.1097/00005072-198603000-00001, PMID 3005518.
- Ødegaard KM, Helseth E, Meling TR. Intraventricular meningiomas: A consecutive series of 22 patients and literature review. *Neurosurg Rev*. 2013;36(1):57-64; discussion 64. doi: 10.1007/s10143-012-0410-5, PMID 22847766.
- Claus EB, Bondy ML, Schildkraut JM, Wiemels JL, Wrensch M, Black PM. Epidemiology of intracranial meningioma. *Neurosurgery*. 2005;57(6):1088-95; discussion 1088-95. doi: 10.1227/01.neu.0000188281.91351.b9, PMID 16331155.
- Winkler PAB, R, Tonn JC. Intraventricular meningiomas. In: Lee JH, editor. *Meningiomas: diagnosis, treatment and outcome*. London: Springer; 2009. p. 491-514.
- Kendall B, Reider-Grosswasser I, Valentine A. Diagnosis of masses presenting within the ventricles on computed tomography. *Neuroradiology*. 1983;25(1):11-22. doi: 10.1007/BF00327474, PMID 6856076.
- Majós C, Cucurella G, Aguilera C, Coll S, Pons LC. Intraventricular meningiomas: MR imaging and MR spectroscopic findings in two cases. *AJNR Am J Neuroradiol*. 1999;20(5):882-5. PMID 10369360.
- Sun GC, Chen XL, Yu XG, Zhang M, Liu G, Hou BK, et al. Functional Neuronavigation-Guided transparieto-occipital cortical resection of meningiomas in trigone of lateral ventricle. *World Neurosurg*. 2015;84(3):756-65. doi: 10.1016/j.wneu.2015.04.057, PMID 25957723.