


# Visual field defects in neuro-ophthalmological diseases at a tertiary hospital in Nepal



Sanjeeta Sitaula<sup>1</sup> , Hira Nath Dahal<sup>2</sup> , Manisha Dahal<sup>2</sup>, Rajeev Ojha<sup>4</sup> ,  
Ananda Kumar Sharma<sup>5</sup> 

<sup>1,2,3</sup> and <sup>5</sup>Department of Ophthalmology, B.P.Koirala Lions Centre for Ophthalmic Sciences, Maharajgunj Medical Campus, Institute of Medicine

<sup>4</sup>Department of Neuromedicine, Maharajgunj Medical Campus, Institute of Medicine

Date of submission: 5<sup>th</sup> April 2023

Date of acceptance: 21st June 2023

Date of publication: 15<sup>th</sup> July 2023

## Abstract

**Introduction:** This retrospective study aims to describe the pattern of visual field defects among patients presenting with neuro-ophthalmological diseases in a tertiary hospital of Kathmandu.

**Materials and Methods:** Medical records of patients undergoing Goldmann visual fields (GVF) for neuro-ophthalmological diseases from July 2019 to June 2021 were retrospectively reviewed. Patient demographics, laterality of the disease, clinical diagnosis and pattern of visual field defect were evaluated and entered and analyzed using SPSS version 20 using descriptive univariate and bivariate analysis.

**Results:** A total of 216 subjects (378 eyes) with the mean age  $34.52 \pm 14.80$  years were included in the study. The visual field defects were divided 4 categories: optic nerve disorders (76.4%, n=165), chiasmal disorders (17.6%, n=38), retrochiasmal disorders (2.8%, n=6) and miscellaneous (3.2%, n=7). Papilledema was the most common diagnosis in optic nerve disorders with enlarged blind spot (79.1%) and constriction of visual fields (18.3%) as pattern of visual field defects followed by optic neuritis. Common lesions affecting the chiasma in our study were pituitary lesions where 30% showed constriction of peripheral fields, 57.5% showed temporal field defects (mostly superotemporal) in both eyes and craniopharyngioma on whom 50% had the classical temporal field involvement (bitemporal-20%, inferotemporal-20% and superotemporal-10%) Retrochiasmal lesions were less common but all showed a bilateral and homonymous pattern of visual field defect.

**Conclusion:** Optic nerve disorders were the most common group of conditions undergoing visual fields. Understanding the varied patterns of visual field defects can aid in early diagnosis and guide timely treatment of common neuro-ophthalmological diseases.

**Key words:** Neuro Ophthalmology, Optic nerve disease, Perimetry, Visual field, Chiasmal lesion

## Introduction

The field of vision is that portion of gaze in which objects are visible at the same moment during steady fixation of the gaze in one direction.<sup>1</sup> Perimetry, which is visual field testing, is a common clinical diagnostic test procedures in the history of ophthalmology being performed for more than 150 years. Perimetry can provide information about both the likely anatomic locus and the disease process for afferent system abnormalities; hence it remains a vital part of the neuro-ophthalmologic evaluation. Perimetry helps in early detection of visual pathway abnormalities, aids in making a differential diagnosis, helps in monitoring progression and remission and sometimes also reveals hidden visual loss in patients having normal visual acuities.<sup>1-3</sup> Visual field testing is therefore important in identifying visual abnormalities that might otherwise not be detected by either a history or other parts of a standard eye examination.

Visual field evaluation should be performed as part of a standard neuro-ophthalmologic examination in

### Access this article online

Website: <https://www.nepjol.info/index.php/NJN>

DOI: <https://doi.org/10.3126/njn.v20i2.53901>

### HOW TO CITE

Sitaula S, Dahal H, Dahal M, Ojha R, Sharma AK. Visual field defects in neuro-ophthalmological diseases at a tertiary hospital in Nepal. NJNS. 2023;20(2):49-56.



### Address for correspondence:

Dr. Sanjeeta Sitaula

Lecturer

Department of Ophthalmology, B. P. Koirala Lions Centre for Ophthalmic Studies, Institute of Medicine, Tribhuvan University, Kathmandu, Nepal

E-mail: [sanjeeta8272@gmail.com](mailto:sanjeeta8272@gmail.com)

Copyright © 2023 Nepalese Society of Neurosurgeons (NESON)

ISSN: 1813-1948 (Print), 1813-1956 (Online)



This work is licensed under a Creative Commons Attribution-Non Commercial 4.0 International License.

all patients.<sup>4</sup> There are many techniques of performing perimetry out of which manual kinetic perimetry with the Goldman perimeter and static automated perimeter are commonly used. Goldmann perimeter is preferred in patients with severe vision loss (visual acuity worse than 20/200), young children or severely restricted visual fields, peripheral visual field defect or for patients with severe neurologic deficits who may not be able to follow instructions well.<sup>1,2,4</sup> It correlates better with activities of daily living but it is time-consuming and requires a skilled technician. Since the perimetric stimulus presentation is done by a person, a rest break can be given when the patient is fatigued or not comprehending the instructions making it more patient-friendly. Automated perimetry has the advantages of automatic calibration of instruments, standardized test procedures, high sensitivity and specificity, reliability checks, and quantitative statistical analysis procedures. The disadvantages of automated perimetry are prolonged test time, increased cognitive demands, fatigue, and lack of flexibility for evaluating difficult patient populations. Both the techniques have certain advantages making them suitable for particular circumstances in selected patients. In our study we studied the pattern of visual field defect by using a Goldmann perimeter.

Visual fields are indispensable tools in diagnosing many neuro-ophthalmological diseases. Understanding the varied patterns of visual field defects can help in early diagnosis by the general ophthalmologist and timely referral which aids in rapid treatment of common neuro-ophthalmological diseases. The aim of this study is to familiarize the general ophthalmologists and neurologists about the common neuro-ophthalmological diseases and its diagnosis by using a tool as simple as a visual field.

## Material and Methods

This retrospective descriptive study analyzed the visual field pattern of patients referred from the neuro-ophthalmology clinics at B P Koirala Lions Centre for Ophthalmic Studies (BPKLCOS) from July 2019 to June 2021. This study was done according to the tenets of the Declaration of Helsinki and ethical approval for the study was obtained from the institutional review board (IRC No. 67(6-11)E2).

The medical records of consecutive patients obtaining Goldmann visual fields from the neuro-ophthalmology department and Out-patient department from BPKLCOS were reviewed. All first ophthalmic visits were included in the study. GVF done for non-neuro-ophthalmological problems like glaucoma or retinal diseases were excluded. Patients with incomplete records, without proper diagnosis or without Goldmann visual fields were also excluded. Patients who required multiple visits and multiple fields

were counted as single patients. Patients with visual acuity of 6/60 or more in the eye being tested and who were able to understand and follow instructions for the tests were included in the study. Parameters evaluated were the patient demographics (age, gender), laterality of the disease, clinical diagnosis and pattern of visual field defect. This information was entered into a proforma designed for data collection.

The Goldmann perimeter is a white hemispheric bowl of uniform luminance (31.5 asb) onto which a small bright stimulus is projected. For the purpose of the study, Goldmann perimeter was used to evaluate the entire visual field. With one eye occluded, the patient fixated a small target in the center of the bowl, and the perimetrist monitored the eye position by means of a telescope. A particular stimulus size and luminance was projected onto the bowl, the target was moved from the far periphery toward fixation at a constant rate of speed, and the patient was instructed to press a response button when he or she first detected the stimulus. The location of target detection was noted on a chart, and the process was repeated for different meridians around the visual field. To delineate scotomata and the blind spot, stimulus was moved from inside to outwards in the scotoma. Blind spot was assessed using a size III4e target. A minimum of twelve vectors were assessed for the peripheral visual field. A trained technician who was unaware of the clinical diagnosis diagnosed the pattern of visual field defect.

All the proformas were thoroughly reviewed for completeness of data. Data was then entered in MS Excel version 10. Then the data was transferred to SPSS software version 20 and analyzed. The statistical methods and tests used for the analysis of data were descriptive univariate and bivariate analysis.

## Results

A total of 378 eyes of 216 subjects with the age ranging from 9 years to 81 years were included in the study. The mean age of the subjects was  $34.52 \pm 14.80$  years and 63% were females (n=136) and 37% (n=80) were males. Bilateral visual field defects were observed in 75 % (n=162) subjects. We further divided the clinical diagnosis into 4 categories: optic nerve disorders, chiasmal disorders, retrochiasmal disorders and miscellaneous. The most common diagnosis was optic nerve disorder (76.4%, n=165) followed by chiasmal disorder (17.6%, n=38), retrochiasmal disorders (2.8%, n=6) and miscellaneous (3.2%, n=7) as shown in Table 1. Bilateral visual field defect was present in 72% of optic nerve disorders, 84% of chiasmal lesions and 100% cases in retrochiasmal lesions.

The common pathologies under each category are listed in table 2. Papilledema (n=110) was the most common disease of optic nerve undergoing visual fields followed

## Visual field defects in neuro-ophthalmological diseases at a tertiary hospital in Nepal

by optic neuritis(n=44) and optic atrophy(n=43). Pituitary tumors, craniopharyngioma and meningioma were the common pathologies causing chiasmal compression in our study. Infarction and trauma were the common causes leading to retrochiasmal visual field defect.

Optic nerve disorders have variable pattern of visual field defect like central scotoma, centrocecal scotoma, generalized constriction, paracentral scotoma, superior or

inferior visual field defect. Figure 1 shows the Goldman Visual field of a 43 year old male showing bilateral cecocentral scotoma involving fixation due to ethambutol induced optic neuropathy.

The chiasmal disorder showed a characteristic bitemporal field defect pattern or generalized constriction of fields.

The retrochiasmal disorders had constriction of homonymous hemianopia or constriction of fields.

**Table 1: Clinical diagnosis of patients having undergoing Goldman visual field perimetry**

Disease category	n (%)	Laterality	
		Unilateral (n)	Bilateral (n)
Optic nerve disorders	165 (76.4%)	46	119
Chiasmal disorders	38 (17.6%)	6	32
Retrochiasmal disorders	6 (2.8%)	0	6
Miscellaneous	7 (3.2%)	2	5
<b>Total</b>	<b>216 (100%)</b>		

**Table 2: Pattern of disease under different disease category (n= number of eyes)**

Optic Nerve disorders	Chiasmal disorders	Retro chiasmal Disorders	Miscellaneous
1. Papilledema (n=110) (Acute Meningoencephalitis (n= 4), Idiopathic Intracranial Hypertension (n=52), cerebral- dorsal/superior sagittal/ transverse sinus thrombosis, (n=12) Hypertensive Retinopathy (n=4), Hydrocephalus- ICSOL/Intraventricular tumour/Tubercular Meningitis (n=18) Others(n=20))	Craniopharyngioma (n=15) Meningioma (n=11) Pituitary tumors (n=44)	Infarction (Vascular disease of posterior/ middle cerebral artery territory) (n=6) Fronto- temporal lobe hematoma (n=2) Left Occipital Lobe Injury (n=2) Veno lymphatic malformation of temporal lobe (n=2)	Acoustic Schwannoma (n=2) Migraine headache (n=6) Myasthenia gravis (n=2) Pineal Tumour (n=2) Sixth nerve palsy (n=1) Third Nerve Palsy (n=1)
2. Anterior/ posterior Ischemic Optic Neuropathy (n=6)			
3. Congenital anomalies - Coloboma, Tilted Disc, Disc drusen (n=4)			
4. Disc Edema of unknown etiology (n=13)			
5. Optic Atrophy (n=43)			
6. Optic Neuritis (n=44)			
7. Optic Neuropathy (n=18)			
8. Compressive (Orbital Apex Syndrome/Retro-orbital abscess/Orbital hematoma) (n=3)			
9. Resolved Optic Neuritis (n=3)			

**Table 3: Pattern of visual field defects in different disease category**

Optic nerve disorders	Chiasmal disorders	Retro chiasmal disorders	Miscellaneous
Centrocecal scotoma			
Central scotoma			
Generalized constriction	Bitemporal hemianopia		Generalized constriction
Inferior visual field defect	Bitemporal hemianopic scotoma	Homonymous hemianopia	Normal
Infero nasal Defect	Bilateral inferotemporal field defect	Homonymous inferior quadrantanopia	Superior visual field defect
Nasal visual field defect	Bilateral superotemporal field defect	Homonymous superior quadrantanopia	Supero nasal visual field defect
Normal	Generalized constriction	Generalized constriction	Infero nasal defect
Paracentral scotoma	Normal		
Superior visual field defect			
Superonasal Visual field defect			
Supero temporal visual field defect			
Temporal Visual field defect			

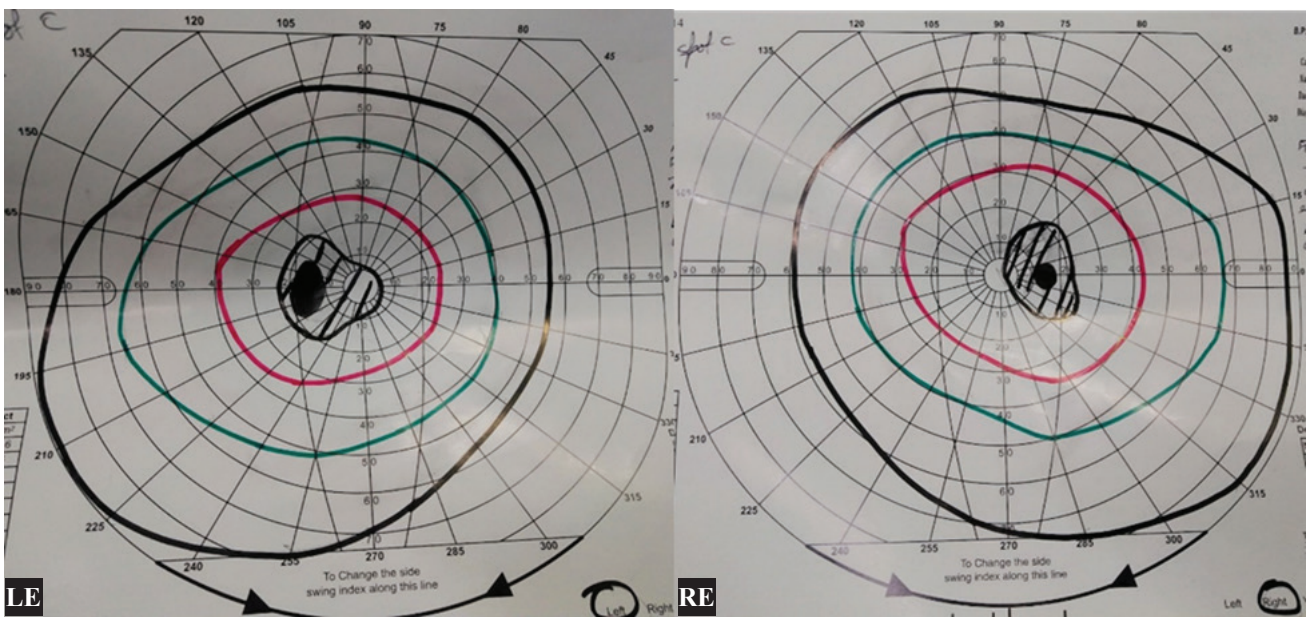
Table 4: Pattern of visual field defect in some common diseases

Disease	Pattern of visual field	Status of Blind spot
Craniopharyngioma (n=15)	Constriction (50%)	Enlarged (80%) Normal (20%)
	Bilateral inferior temporal scotoma (20%)	
	Bilateral supero temporal visual field defect (10%)	
	bitemporal visual field defect (20%)	
Disc Edema / Papilledema(n=123)	Constriction (18.3%)	Enlarged (79.1%) Normal (19.1%) Couldn't be assessed (1.7%)
	Infero nasal defect (0.9%)	
	Nasal visual field defect (3.5%)	
	Normal (65.2%)	
	Superior visual field defect (4.3%)	
	Supero nasal visual field defect (2.6%)	
	Supero temporal visual field defect (3.5%)	
Temporal visual field defect (1.7%)		
Hypertensive Retinopathy (n=4)	Constriction (50%)	Enlarged (100%)
	Normal (25%)	
	Supero nasal visual field defect (25%)	
Idiopathic Intra cranial Hypertension (n=52)	Constriction (56.3%)	Centrocecal scotoma (12.5%) Enlarged (81.3%) Normal (6.3%)
	Normal (12.5%)	
	Superior visual field defect (6.3%)	
	Supero nasal visual field defect (12.5%)	
	Temporal visual field defect (12.5%)	
ICSOL ( n=15)	Constriction (40%)	Enlarged (46.7%) Normal (53.3%)
	Normal (40%)	
	Superior visual field defect (6.7%)	
	Temporal visual field defect (13.3%)	
Migraine Headache (n=6)	Normal (66.7%)	Enlarged (100%)
	Superior visual field defect (33.3%)	
Optic Atrophy (n=43)	Central scotoma (4.5%)	Centro cecal scotoma (4.5%) Enlarged (45.5%) Normal (38.6%) Not able to plot (11.4%)
	Centro caecal scotoma (2.3%)	
	Constriction (27.3%)	
	Inferior visual field defect (4.5%)	
	Inferonasal defect (13.6%)	
	Nasal visual field defect (2.3%)	
	Normal (20.5%)	
	Superior visual field defect (4.5%)	
Supero nasal visual field defect (4.5%)		
Temporal visual field defect (6.8%)		
Optic Neuritis (n=44)	Central scotoma (2.3%)	Centrocecal (16.3%) Enlarged (65.1%) Normal (14.0%) Not able to plot (4.7%)
	Constriction (34.9%)	
	Inferior visual field defect (2.3%)	
	Infero nasal defect (2.3%)	
	Infero temporal visual field defect (2.3%)	
	Nasal visual field defect (4.7%)	
	Normal (27.9%)	
	Superior visual field defect (2.3%)	
	Supero nasal visual field defect (2.3%)	
	Supero temporal visual field defect (9.3%)	
	Temporal hemianopia (4.7%)	
Temporal visual field defect (2.3%)		

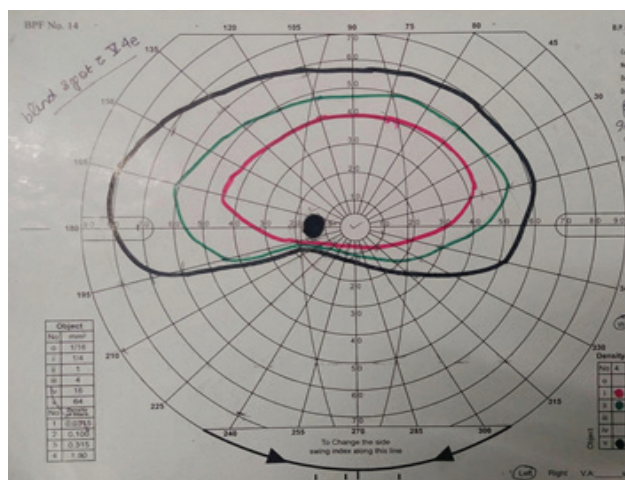


**Visual field defects in neuro-ophthalmological diseases at a tertiary hospital in Nepal**

Optic neuropathy (n=18)	Centrocecal scotoma (33.3%) Constriction (44.4%) Normal (11.1%) Superior visual field defect (11.1%) Supero nasal visual field defect (5.6%) Supero temporal visual field defect (5.6%) Temporal visual field defect (5.6%)	Enlarged (66.7%) Normal (5.6%)
Pituitary tumors (n=42)	Constriction (30%) Normal (12.5%) Superior bitemporal visual field defect (35%) Bitemporal hemianopic scotoma (10%) Bitemporal hemianopia (12.5%)	Enlarged (40%) Normal (50%) Not able to plot (10%)



*Figure 1: Goldman Visual field of a 43 year old male showing bilateral cecocentral scotoma involving fixation due to ethambutol induced optic neuropathy*



*Figure 2: Goldman visual field of the left eye showing Inferior altitudinal field defect in a 65 year old hypertensive male characteristic of Nonarteritic ischemic optic neuropathy.*

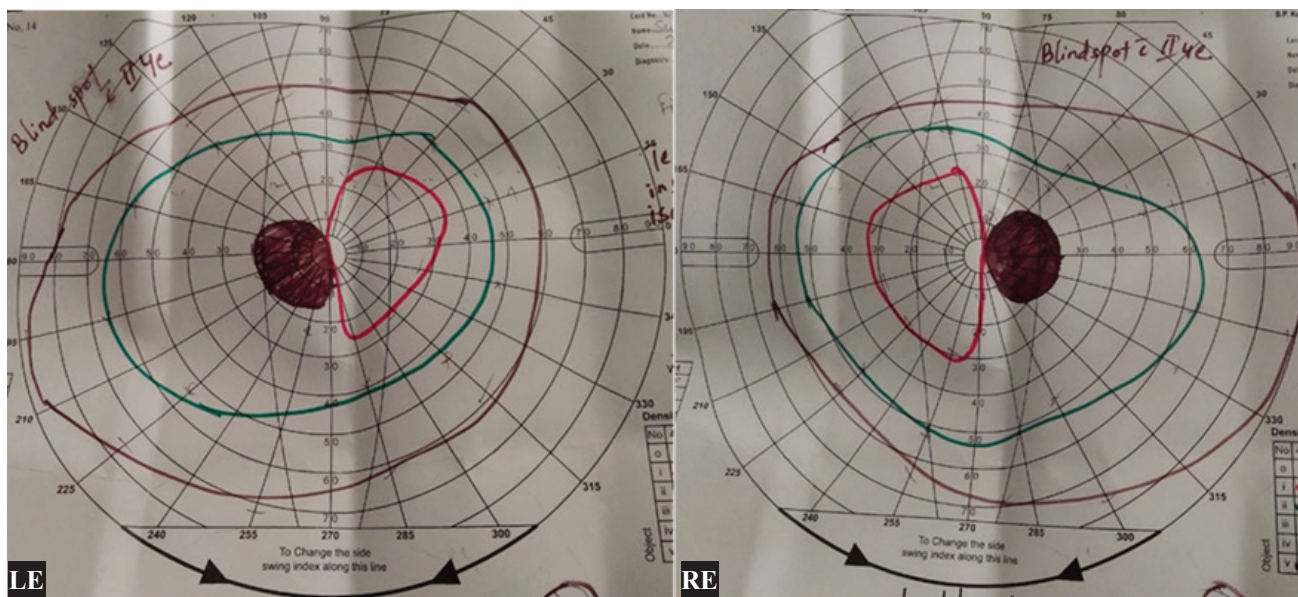


Figure 3: Goldman visual field of a 43 year old female of both eyes showing reduction of central sensitivity in both eyes in the temporal side hinting bitemporal hemianopic scotoma. MRI of the brain showed pituitary macroadenoma.




Figure 4: Goldman visual field of a 59 year old male showing right inferior quadrantanopia (pie in the floor visual field defect) due to old infarction of the parietal lobe

### Discussion

Visual field examination is vital for a complete neuro-ophthalmological evaluation of a patient for diagnosing the disease condition, planning of treatment modality and monitoring the condition of disease. Presence of visual field defects indicate involvement of the visual pathways and the pattern of visual field defects help in localizing the site of the lesion. Assessment of the visual fields is

integral to monitoring resolution and/or recurrence of disease processes affecting the visual pathways. Visual field defects also affect the patient’s ability to perform day-to-day activities and have a negative influence on the quality of life of the patient. In this study we aim to concisely describe the pattern of visual field defects among the common neuro-ophthalmological disorders and to highlight the characteristics of visual field defects which require urgent neuro-ophthalmological attention.

Various patterns of visual field defects are observed depending upon the location of lesion in the visual



pathway. The normal dictum is that diseases of the retina and optic nerves respect the horizontal meridian because of the specific pattern of arrangement of the nerve fiber layer of the retina whereas pathology at or beyond the optic chiasma have bilateral involvement with visual field defect originating from the point of fixation respecting the vertical meridian due to the crossing of nasal fibers of the optic nerves in the optic chiasma.<sup>5</sup>

The common disorders requiring visual field examination in the neuro-ophthalmology clinic are optic nerve disorders like papilledema, Idiopathic intracranial hypertension (IIH), optic neuritis, non-arteritic anterior ischemic optic neuropathy (NAION) and hereditary or toxic optic neuropathy. Lesions in chiasma by sellar or suprasellar masses produce characteristic visual field defect in both eyes helping in anatomic localization of the disease. Retrochiasmal disorders produce varied patterns of homonymous hemianopia, depending on the site of the lesion which was immensely helpful to localize the lesion in the visual pathway before the era of modern neuroimaging. Identifying the pattern of visual field deficits helps us understand how the quality of life and activities of daily living is affected and helps us in planning the appropriate visual rehabilitation.

For the purpose of this study we divided the diseases into four categories: Optic Nerve disorders, Chiasmal disorders, and Retrochiasmal Disorders and Miscellaneous cases. The common diseases of the optic nerves that were evaluated were optic neuritis and various types of optic neuropathy, optic atrophy due to varied etiology, Anterior Ischemic Optic Neuropathy (AION), congenital anomalies of optic disc (coloboma, optic disc pit, and tilted disc), papilledema and optic disc edema. The common causes of papilledema were secondary to IIH, cortical venous sinus thrombosis, intracranial space occupying lesion and hypertensive retinopathy in our study. The most common visual field defect associated with optic nerve pathology was enlargement of blind spot followed by constriction of the peripheral fields in our study.

The most common pattern of defects seen in IIH in our study was blind spot enlargement (81.3%), generalized constriction (56.3%), and loss of the superonasal (12.5%) and temporal visual fields (12.5%) which was similar to other previous reports.<sup>2,6</sup> Other common field defects described include inferior altitudinal loss, superonasal and superotemporal loss, arcuate defects, and central, cecocentral, and paracentral scotomas.<sup>7,8</sup> The common visual field defects in patients with optic neuritis in the Optic Neuritis Treatment Trial (ONTT) included diffuse visual field loss, altitudinal defects, central or cecocentral scotoma, arcuate or double arcuate, hemianopic defects, and others.<sup>9</sup> In our study, optic neuritis presented with variable pattern of visual field defects as described in other previous reports, however the most common pattern

was enlargement of blind spot (65.1%), constriction of peripheral fields (34.9%), and cecocentral scotoma (16.3%). Hereditary and toxic optic neuropathy typically present with central or cecocentral scotoma which was also similar to the finding of our study.<sup>10</sup> There were 3 cases of ethambutol induced optic neuropathy undergoing GVF and all 6 eyes of these patients had centrocecal scotoma as described in previous reports.<sup>1,2</sup> Other types of optic neuropathy due to compressive causes presented with enlargement of blind spot (66.7%) and constriction of peripheral fields (44.4%).<sup>2</sup> Visual field defects in nonarteritic anterior ischemic optic neuropathy (NAION) classically is inferior altitudinal field defect however inferior nasal defect, superior altitudinal field defect, central scotoma, arcuate scotoma, and quadrantic defects can also be seen.<sup>10,11</sup> In this study, inferonasal visual field defect, inferior altitudinal field defect followed by superior visual field defect were commonly seen in patients with NAION where visual field charting was possible.

Lesions of the optic chiasm can produce a variety of visual field defects including bitemporal hemianopia, junctional scotoma (anterior chiasmal defect), quadrantanopia and bitemporal, or unilateral temporal scotoma depending on the site and extent of the lesion. Common lesions affecting the chiasma in our study were pituitary tumors followed by craniopharyngioma. In cases with craniopharyngioma 50% had the classical temporal field involvement (bitemporal- 20%, inferotemporal -20% and superotemporal-10%) and 50% had generalized constriction with 80% cases showing blind spot enlargement. However in cases with pituitary lesions, 30% showed constriction of peripheral fields, 35% showed bilateral superotemporal field defects, 12.5% showed bitemporal hemianopia, 10% had bitemporal hemianopic scotoma and the rest had nonspecific or normal findings. Our findings are similar to the study by Astorga-Carballo where they reported 39.8% of cases with chiasmal syndrome presenting with bitemporal hemianopia where pituitary adenoma were the most common cause of chiasmal lesions.<sup>12</sup>

Retrochiasmal disorders produce varied patterns of homonymous hemianopia from lesions of the optic tract, lateral geniculate body, temporal and parietal lobes (optic radiations) and occipital lobes. A total or complete homonymous hemianopia does not have any localizing value other than the lesion is retrochiasmal in location. However the more congruous the visual field defect, the more posterior is the lesion. That means that a grossly incongruous homonymous field defect points to an anterior lesion like in the optic tract.<sup>13,14</sup> A homonymous pie shaped defect that centers on fixation is characteristic of the lateral geniculate body lesion. Lesions of the optic radiations usually produce a mildly incongruous homonymous hemianopia with an upper quadrant pie in the sky defect

often due to a temporal lobe lesion and lower quadrant pie on the floor defect often due to a parietal lobe lesion. Lesions in the occipital lobe show markedly congruous homonymous hemianopia. Other localizing features of occipital lobe are macular sparing and monocular loss of the unpaired temporal crescent. A quadrantic defect that stops sharply at the horizontal meridian is also seen as the upper and lower occipital lobes have distinctive vascular supply. Inferior quadrantanopias were caused commonly by occipital lobe lesions (76%) followed by parietal lesions (22%) and superior quadrantanopias are caused by occipital (83%), temporal lobe (13%) and parietal lobe lesion (3%) in a study by Jacobson.<sup>15</sup>

The common lesions responsible for retrochiasmal field defect in our study were cerebrovascular infarction followed by trauma. There were 3 cases with infarction in the PCA territory with 2 cases presenting with contralateral homonymous hemianopia and 1 case with homonymous inferior quadrantanopia (pie in the floor) due to old infarction of the parietal lobe. Two other retrochiasmal field defects presented post trauma with pie in the sky ? in one case due to fronto temporal hematoma and right homonymous hemianopia due to left occipital lobe injury. The miscellaneous category consisted of patients who had visual symptoms and underwent visual field examination for neurological diseases which did not directly affect the visual pathway. These patients had mostly normal visual fields followed by constriction and other nonspecific patterns of visual field defects.

## Conclusion

Optic nerve disorders were the most common neuro-ophthalmological conditions undergoing Goldman visual fields. There was bilateral visual field defect in 72 % of optic nerve disorders with a varied pattern of visual field defects according to the etiology, however enlargement of blind spot was a common finding in Goldman visual fields. Disorders affecting the chiasma had bilateral visual field involvement in 84% of cases and typically had bitemporal hemianopia. Retrochiasmal lesions had bilateral homonymous field defects in all cases. Awareness about the varied patterns of visual field defects among ophthalmologists and neurologists can help in early diagnosis and aid in timely treatment of common neuro-ophthalmological diseases.

## References

- Hickman SJ. Neurological Visual Field Defects. *Neuro-Ophthalmol.* 2011;35(5-6):242-250. doi:10.3109/01658107.2011.616980
- Kedar S, Ghate D, Corbett J. Visual fields in neuro-ophthalmology. *Indian J Ophthalmol.* 2011;59(2):103. doi:10.4103/0301-4738.77013
- Bhaskaran K, Phuljhele S, Kumar P, Saxena R, Angmo D, Sharma P. Comparative evaluation of Octopus semi-automated kinetic perimeter with Humphrey and Goldmann perimeters in neuro-ophthalmic disorders. *Indian J Ophthalmol.* 2021;69(4):918. doi:10.4103/ijo.IJO\_1266\_20
- Miller NR, Biousse V, Kerrison JB. *Walsh and Hoyt's Clinical Neuro-Ophthalmology. Vol. 3.*; 2004.
- Kline L. *Neuro-ophthalmology review manual.* SLACK Incorporated; 2012.
- Wall M, George D. Idiopathic intracranial hypertension. A prospective study of 50 patients. *Brain J Neurol.* 1991;114 ( Pt 1A):155-180.
- Wall M. Visual Loss in Pseudotumor Cerebri: Incidence and Defects Related to Visual Field Strategy. *Arch Neurol.* 1987;44(2):170. doi:10.1001/archneur.1987.00520140040015
- Salgarello T, Tamburrelli C, Falsini B, Giudiceandrea A, Colotto A. Optic nerve diameters and perimetric thresholds in idiopathic intracranial hypertension. *Br J Ophthalmol.* 1996;80(6):509-514. doi:10.1136/bjo.80.6.509
- Keltner JL. Baseline Visual Field Profile of Optic Neuritis: The Experience of the Optic Neuritis Treatment Trial. *Arch Ophthalmol.* 1993;111(2):231. doi:10.1001/archophth.1993.01090020085029
- Hayreh SS. Visual Field Abnormalities in Nonarteritic Anterior Ischemic Optic Neuropathy: Their Pattern and Prevalence at Initial Examination. *Arch Ophthalmol.* 2005;123(11):1554. doi:10.1001/archophth.123.11.1554
- Gerling J, Meyer JH, Kommerell G. Visual field defects in optic neuritis and anterior ischemic optic neuropathy: distinctive features. *Graefes Arch Clin Exp Ophthalmol.* 1998;236(3):188-192. doi:10.1007/s004170050062
- Astorga-Carballo A, Serna-Ojeda JC, Camargo-Suarez MF. Chiasmal syndrome: Clinical characteristics in patients attending an ophthalmological center. *Saudi J Ophthalmol.* 2017;31(4):229-233. doi:10.1016/j.sjopt.2017.08.004
- Kedar S, Zhang X, Lynn MJ, Newman NJ, Biousse V. Congruency in Homonymous Hemianopia. *Am J Ophthalmol.* 2007;143(5):772-780. doi:10.1016/j.ajo.2007.01.048
- Pula JH, Yuen CA. Eyes and stroke: the visual aspects of cerebrovascular disease. *Stroke Vasc Neurol.* 2017;2(4):210-220. doi:10.1136/svn-2017-000079
- Jacobson DM. The Localizing Value of a Quadrantanopia. *Arch Neurol.* 1997;54(4):401-404. doi:10.1001/archneur.1997.00550160045014