


Diastomatomyelia- A Case Series

Uddalok Das¹ , Narayan Pandit² ^{1,2} Department of Radiodiagnosis, North Bengal Medical College, Sushrutnagar, Darjeeling, IndiaDate of submission: 10th October 2022Date of acceptance: 30th March 2023Date of publication: 15th July 2023

Abstract

Diastematomyelia also called a split cord syndrome is a rare clinical entity. A group of concealed spinal dysraphisms includes this unusual congenital spinal cord defect known as diastematomyelia. The condition is characterized by a sagittal split of the spinal cord, conus medullaris, or filum terminale. There is often a fibrous, bony, or cartilaginous septum identified by dividing the two cords. It is frequently associated with other congenital anomalies of the spine and the cord. Presentation is varied from asymptomatic to lower back pain, lower extremity weakness, and spinal cord dysfunction. Imaging plays a vital role in the diagnosis. We present a series of 2 cases of diastematomyelia along with imaging features. One of the patients is also a case of Jarcho Levine syndrome (JLS) making it the eighth case in world medical literature to report a case of JLS with diastematomyelia

Key words: Split cord, Diastematomyelia, Jarcho Levine syndrome, Congenital anomaly

Introduction

Diastematomyelia belongs to a group of complex dysraphic disorders¹. The term was first used in 1837 by Oliver in his treatise on diseases of the spinal cord published in Paris. "Diastema" means crack and "mielie" means spinal marrow. Before 1950 little was known about the disease and all the cases identified were postmortem². With the advent of cross-sectional imaging, the diagnosis of this condition has become more frequent. With Ultrasonography (USG) antenatal diagnosis of this condition is possible now. Rarely is it diagnosed in the later age groups. Approximately 80–90% of cases are in females, and it most frequently affects the dorsolumbar spine. A few examples of multilevel or cervical diastematomyelia are also reported in the literature³.

Jarcho-Levin syndrome (JLS) also called spondylothoracic dysostosis is a rare congenital disorder characterized by short stature with multiple abnormalities in the rib cage and vertebrae. Before this, there have been around seven cases reporting JLS with diastematomyelia⁴. This is the eighth case in world medical literature reporting a case of diastematomyelia with JLS

Case Series

Case 1

A 6-year-old girl was brought to the pediatrics outpatient department (OPD) with complaints of weakness in both lower limbs and bladder bowel incontinence over the last few months. Physical examination was essentially normal except for reduced power in both lower limbs and exaggerated deep tendon reflexes of lower limbs. The patient was referred to the department of Radiodiagnosis for Magnetic Resonance Imaging (MRI) of the brain and spinal cord. MRI of the brain was unremarkable. MRI of the spine revealed two separate hemicords from the D7 vertebral level. A thin bony bar was seen between the two hemicords. The right hemicord was larger than the left. Hydromyelia was seen from D2 to the D9 level. The lower end of the cord was tethered to soft tissues posteriorly at the L5 level (Figures 1 and 2). Multiple vertebral anomalies including hemivertebrae and spina bifida were present. The case was diagnosed as Type 1 diastematomyelia. The patient was referred to the apex center of pediatric surgery for better management.

CASE 2

An otherwise normal 9-month-old girl was brought to the pediatrics OPD with complaints of a subtle chest deformity since birth. The patient was sent to our department for a dorsolumbar spine X-ray. The X-ray

Access this article online

Website: <https://www.nepjol.info/index.php/NJN>DOI: <https://doi.org/10.3126/njn.v20i2.49039>

HOW TO CITE

Das U, Pandit N. Diastomatomyelia-A series of two cases. NJNS. 2023;20(2):71-74.



Address for correspondence:

Uddalok Das

North Bengal Medical College and Hospital, Sushruta Nagar, Pin – 734012, Dist – Darjeeling

E-mail: rikdas05@gmail.com

Copyright © 2023 Nepalese Society of Neurosurgeons (NESON)

ISSN: 1813-1948 (Print), 1813-1956 (Online)



This work is licensed under a Creative Commons Attribution-Non Commercial 4.0 International License.

revealed a few malformed ribs on the right fanning out in a crab-like fashion. D5, D6, and D7 hemivertebrae with spina bifida of D7 vertebrae. Absent rib on the right side at D6 and D9 levels (Figure 3). A provisional diagnosis of JLS was made. An MRI of the spine was done. MRI of the spine revealed two separate hemicords from the D12 to L2 level. A dilated right posterior spinal artery flow void was also seen at the level of bifurcation of the

cords. The artery measured 5.4mm in maximum diameter and was occupying an almost midline position (Figure 4). However, a contrast study could not be done as the child was extremely restless and the parents of the child refused to consent to the same. A final diagnosis of JLS with diastomatomyelia was made. The child was scheduled for a pediatric surgeon and neurologist opinion on the next visit but the parents did not turn up

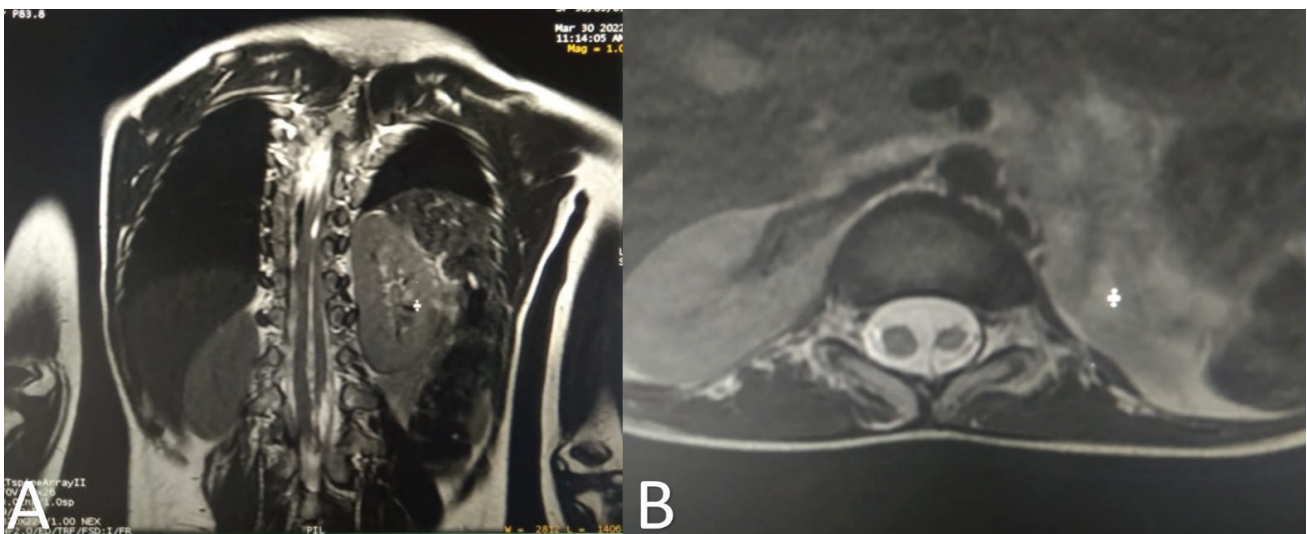


Figure 1 (A and B): Coronal and Axial T2 weighted images showing two separate hemicords with a thin intervening bony spur

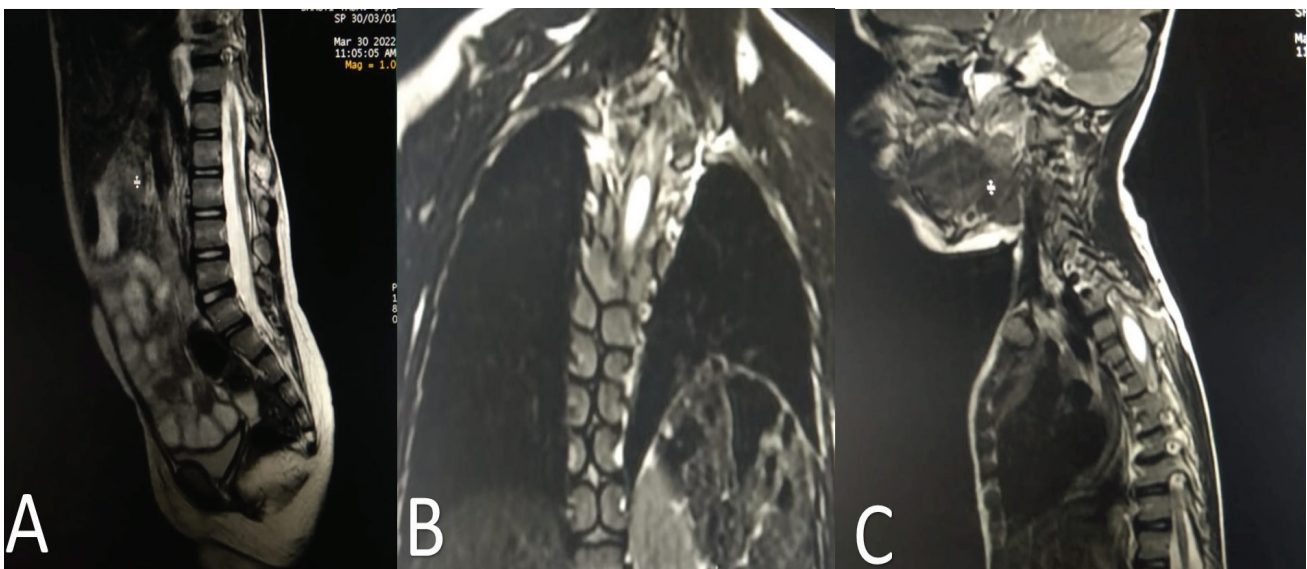


Figure 2 (A, B, and C): The lower end of the cord tethered to soft tissues posteriorly at L5. Multiple vertebral segmentation anomalies are present. Hydromyelia is seen from D2 to D9 level

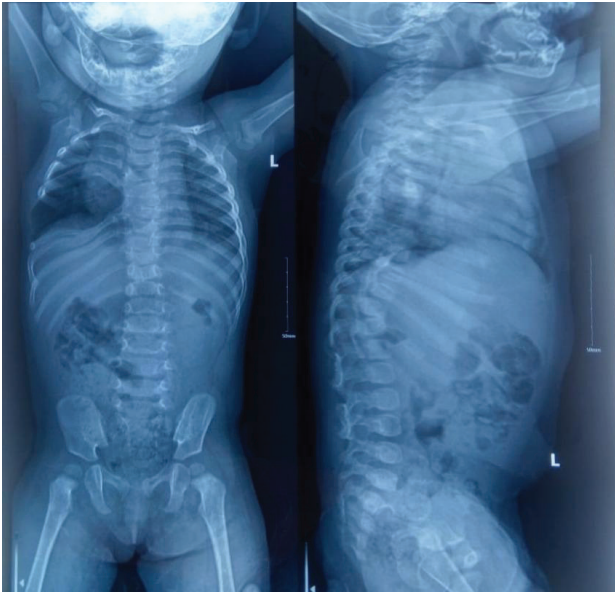


Figure 3: Multiple radiating crab-like ribs, hemivertebrae, absent ribs, and fused ribs

Discussion

Diastematomyelia belongs to the spectrum of complex spinal dysrharism states. It results from adhesions between ectoderm and endoderm, leading to the persistence of the neurenteric canal, which prevents fusion of the bilateral notochordal anlage in the midline. As a result each notochord subsequently induces the development of a hemineural plate⁵. The male-to-female ratio for this rare entity is 24:15. Diastematomyelia is most commonly seen between D9 and S1 levels⁶. Split cord malformations (SCM) can occasionally occur at different levels, but they are most frequent in the lower cord. The

majority of the patients exhibit symptoms, such as lower limb weakness, muscle atrophy, low back discomfort, deformed curvature of the back, and incontinence, which are indistinguishable from the symptoms produced by a tethered chord. Few patients may remain asymptomatic and the condition may be diagnosed incidentally on an MRI done for some other pathology. Patients with the mild type have little or no symptoms. It is clinically indistinguishable from other causes of the tethered spinal cord in absence of cutaneous stigmata of which the “fawn’s tail” hair patch is most common^{7,8}. Pang et al classified spinal cord malformations into two types. Pang type I SCM is characterized by a dual dural sac with two hemicords, one in each dural sac, and Pang type II by a single dural sac containing both hemicords. In Pang type I, an osseocartilaginous spur separates the two hemicords; which is rare in Pang type II. Pang type I split cords, especially those that have an unevenly oriented oblique septum separating the cord, are more likely to result in surgical morbidity than Pang type II split cords. Associated cord anomalies are milder in type II than in type I[]

Spondylothoracic dysostosis, often known as JLS is a rare congenital disorder characterized by short stature and numerous rib cage and vertebral anomalies including crab-like fanned-out ribs and vertebral segmentation anomalies. The thoracic cage is unable to accommodate the expanding lung because of the structural abnormalities of the ribcage. As a result, thoracic insufficiency, serious cardio-respiratory issues, and recurrent chest infections develop. Genetic diagnosis is costly and possible only in limited centers of the nation. In a resource-poor setting like our country, plain radiography may be used to clinch the diagnosis with adequate confidence⁹. To the best of our knowledge, seven cases of diastematomyelia in

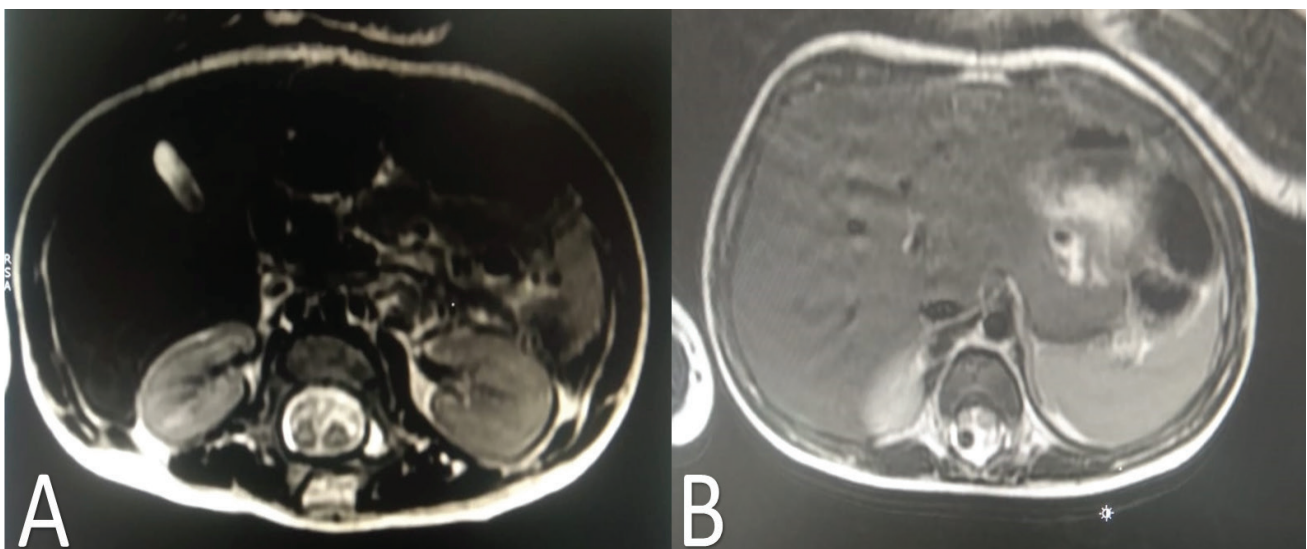


Figure 4 (A and B): Axial T2 weighted images showing two separate hemicords. A flow void is seen in the right posterolateral aspect of the cord likely representing an aneurysmally dilated right posterior spinal artery

JLS patients have been reported so far in world medical literature making this probably the eighth report.¹⁰

Conclusion

Diastematomyelia is a rare congenital disorder of the spinal cord and is often associated with other accompanying vertebral and spinal cord defects. The etiopathogenesis of the condition remains complex and uncertain. MRI is an invaluable tool for the characterization of the lesion and for demonstrating associated anomalies. The impact of this on the quality of life of the patients is enormous. Any patients presenting with multiple congenital anomalies of vertebrae on a radiograph should be evaluated with MRI to rule out this condition and other anomalies of the cord

References

1. Haaga, John R., and Daniel T. Boll, editors. CT and MRI of the Whole Body. Sixth edition, Elsevier, 2017
2. Pang D, Dias MS, Ahab-Barmada M. Split cord malformation: Part I: A unified theory of embryogenesis for double spinal cord malformations. Neurosurgery. 1992 Sep;31(3):451-80. doi: 10.1227/00006123-199209000-00010. PMID: 1407428.
3. Kulkarni M, Ruparel M, Redkar R. Fetal diastematomyelia: MR imaging: A case report. Indian J Radiol Imaging. 2009 Feb;19(1):78-80. doi: 10.4103/0971-3026.45351. PMID: 19774146; PMCID: PMC2747417. J Korean Soc Radiol. 2015 Jan;72(1):73-76. <https://doi.org/10.3348/jksr.2015.72.1.7>
4. J Korean Soc Radiol. 2015 Jan;72(1):73-76. <https://doi.org/10.3348/jksr.2015.72.1.73>
5. Byrd SE, Darling CF, McLone DG. Developmental disorders of the pediatric spine. Radiol Clin North Am. 1991 Jul;29(4):711-52. PMID: 2063002.
6. Narra, Ramakrishna & Kadiyala, Chaitanya & Gadde, Prathibha & Pasupuleti, Bhimeswara. (2020). Imaging findings in diastematomyelia: A rare type of spinal dysraphism. Indian Journal of Case Reports. 6. 715-718. 10.32677/IJCR.2020.v06.i12.014.
7. Scotti G, Musgrave MA, Harwood-Nash DC, Fitz CR, Chuang SH. Diastematomyelia in children: metrizamide and CT metrizamide myelography. AJR Am J Roentgenol. 1980 Dec;135(6):1225-32. doi: 10.2214/ajr.135.6.1225. PMID: 6779529.
8. Das U, Pandit N. COVID-19 in a case of Jarcho Levin syndrome. Majmaah J Heal Sci. 2022; 10(4): 127-132. doi:10.5455/mjhs.2022.04.011