


Radiological Comparison of the Biomechanical Characteristics of Short Segment Posterior Instrumentation (Moss-Miami System), with and without Transverse Connector in Unstable Thoracolumbar Fracture



Anand Doshi¹ , Prashant Khandelwal² , Sejal Mehta³ , Sudhir Sudumbrekar⁴ 

^{1,2,3,4}Department of Neurosurgery, Bharati Vidyapeeth (DU) Medical College and Hospital, Pune

Date of submission: 22nd July 2021

Date of acceptance: 21st January 2022

Date of publication: 15th March 2022

Abstract

Introduction: Wedge compression fracture was most common type of fracture (66.6 %) and first Lumbar vertebra (L1) was the most common fracture site (38 %). The choice of surgical approach and instrumentation depends on fracture type, injury level and degree of neural injury. This paper evaluated efficacy of transpedicular screw fixation by Moss Miami instrumentation with transverse connector for surgical treatment in traumatic unstable thoracolumbar fractures.

Materials and Method: Fifty-five cases were prospectively studied over three years. Comparison was done between two groups- Group 1 without transverse connector and Group 2 with transverse connector. Radiologically evaluation was done in both groups pre-operatively, tenth day, six weeks and six months interval. All X-rays were assessed by lateral and dynamic antero- posterior views for measuring kyphotic (Cobb's) angle and inter-rod angle.

Results: In both groups post-operative Mean Cobb's angle level were increased and remained same until 06 months. Variation in Group 2 with transverse connector was slightly higher in initial period (i.e.) after 10 days and then it remains minimal from 6 weeks to 6 months. But in Group 1 without transverse connector the change in angle variation was minimal which worsen over 6 weeks and it continues to remain worse at 6 months, suggestive of parallelogram effect.

Conclusion: Transverse connector does play role in preventing parallelogram effect of implants and provides additional stability to the construct. This is first study done in vivo which is done to study the role of transverse connector and evaluate any parallelogram effect in spinal instrumentation.

Key words: Transverse connector, Thoraco-lumbar fracture, parallelogram effect

Introduction

Fracture-dislocation of the spine is a serious injury that is prevalent in physically active individuals. The management and evaluation of this injury has changed tremendously over the last decade.

Boucher was the first to get credit for pedicle screw fixation of the spine in 1959. Significant advances by Magrel and Dick, Steffee, Luque, Cotrel and Dubousset and the others in biomechanical design and placement technique have led to a rapid increase in the use of implants in spinal fixation. In 1996, Odgers et al. was the first to publish pedicle screw insertion under image guidance.¹

Spinal stability is defined as the ability for the vertebrae to maintain their relationship and limit their relative displacements during physiologic postures and loads.² Unstable thoraco-lumbar spine injuries requires stabilization to obtain and maintain spinal stability, facilitate neurological recovery and relieve pain in incomplete neurological deficit as well as rehabilitation

Access this article online

Website: <https://www.nepjol.info/index.php/NJN>

DOI: <https://doi.org/10.3126/njn.v19i1.38548>

HOW TO CITE

Doshi A, Khandelwal P, Mehta S, Sudumbrekar S. Radiological Comparison of the Biomechanical Characteristics of Short Segment Posterior Instrumentation (Moss- Miami System), with and without Transverse Connector, in Unstable Thoraco-Lumbar Fracture. *NJNS*. 2022;19(1):31-7.



Address for correspondence:

Dr. Prashant Khandelwal

Department of Neurosurgery, Bharati Vidyapeeth (DU) Medical College and Hospital, Pune

E-mail: drpash72@gmail.com

Copyright © 2022 Nepalese Society of Neurosurgeons (NESON)

ISSN: 1813-1948 (Print), 1813-1956 (Online)



This work is licensed under a Creative Commons Attribution-Non Commercial 4.0 International License.

of the patient starting from mobilization to ambulation where possible.³ In the majority of comparison studies between surgical and non-surgical treatment, it appears that neurologic recovery is enhanced in surgically treated patients. The choice of surgical approach and instrumentation requires a thorough understanding of fracture type, injury level and degree of neural injury.⁴ Moss Miami posterior spinal instrumentation is a spinal instrumentation introduced, which is a hybrid system using pedicular screws and rods.

The use of transverse connector in this posterior stabilization has a controversial role. Krag MH et al. found that pedicle fixation techniques may fail during axial loading.⁵ This is in part due to a tendency towards the development of a parallelogram-like translational deformity. Toeing-in of the screws and the use of transverse connectors help to prevent this mechanism of construct failure.

The aim of our study is radiological comparison of the biomechanical characteristics of short segment posterior instrumentation (Moss- Miami System), with and without transverse connector, in unstable thoraco-lumbar fractures. Transverse connector have additional stabilization role in Moss Miami pedicle screw system, and it does help in preventing parallelogram effect.

Materials and Methods

A prospective observational study been carried out in our neurosurgical department over a period of three years from Dec 2016 to Dec 2019 after ethical committee approval.

The inclusion criteria were:

1. Traumatic insult to the thoracolumbar spine of less than five days duration
2. Without significant neurological deficit
3. Unstable fracture/subluxation or dislocation

Criteria for the instability of the thoracolumbar injuries during the study:

- a) Loss of vertebral body height by more than 50%
- b) Kyphotic deformity
- c) Involvement of two or more of the Denis' three columns.

Patient data included demographics, mode of injury, duration of trauma, and pre injury ambulatory status. The deformity, disability, distal neurovascular status and other associated injuries were recorded. The neurological status was assessed according to American Spinal Injury Association Score.

All laboratory tests and a thorough radiological investigation including CT scans were done to define the fracture morphology. All the surgeries were performed on routine basis by a single consultant. Other additional

surgical procedures example decompression, reduction of fracture, fracture dislocation, or dislocation etc were added to this operative procedure and carried out as per standard technique, when required.

Surgery was done under general anaesthesia through posterior midline approach. Standard Pedicle entry point and directions were followed. Intra-operative confirmation under c-arm guidance was carried out. Transverse connector was used in alternate patients; hence two Groups were formed. Comparison was done between the two groups- Group 1 without transverse connector and Group 2 with transverse connector. Radiologically evaluation was done in both groups pre-operatively, tenth day, six weeks and six months interval. All X-rays were assessed by lateral and dynamic antero- posterior views for measuring kyphotic (Cobb's) angle and inter-rod angle. Four X-ray shoots were taken- Antero-posterior view (Right bending, Left bending, Neutral) and Lateral view. The Difference between Neutral and Right bending angles calculated on X-ray were considered as 'Right bending angle difference'. Similarly difference between Neutral and Left bending angles calculated on X-ray were considered as 'Left bending angle difference'.

Traditional Cobb's beta angle: On the lateral X-ray view the angle is derived from the slope of selected vertebral end-plates, which also provides objective measurement of frontal plane spinal deformity. Perpendiculars were extended from lines drawn through superior endplate of one vertebra above the cranial implanted vertebrae and inferior endplate of one vertebra below the caudal implanted vertebrae. The resulting angle was measured from the intersection of the two perpendiculars.

Standardization of x-rays

Tube to plate distance kept at 100 cm

Exposure made on arrested expiration

X-ray machine: Konika Minolta AERO DR (Model-X 70)

Goniometry used for calculating angle of lateral bending- which was kept standard for all patients at 40 degrees. All statistical analysis were done using SPSS (Statistical package for social science) software program, version 18. The mean and standard deviations were computed for continuous variables. Percentages were used for categorical variables.

Results

Out of sixty-five patients with unstable thoraco-lumbar spinal fractures, ten patients were lost for subsequent follow up and were hence excluded from the study. Hence only fifty-five cases were analysed for final result. Most of the patients were in years of age group 36-45 years (24%). The mean age was 41 years (15-67 years).

Radiological Comparison of the Biomechanical Characteristics of Short Segment Posterior ...

Out of 55 total number of cases, 47 (85%) were males and 8 (15%) were females at the ratio of 5.9 males: 1 female.

70% of the patients were laborers, 15% students 10% were involved in household activities, & 5% other. Out of 55 patients 71 % (39 patients) sustained injury due to fall from height whereas 29 % (16 patients) sustained injury by Road traffic accidents. Wedge compression fractures (63.6 %) was the most common type of injury followed by Unstable burst fracture (30.9 %) and translational injuries (5.5 %).

L1vertebra was the most common level of injury. Out of 55 patients, 21 patients (38 %) had L1 vertebral fracture. Out of 55 total number of cases, 26 (47.3 %) had mild neurological involvement and 29 (52.7 %) had no neurological involvement.

Graph 1 and Graph 2 shows the variation is more stable from 10 days to 6 months in Group 2 as compared to Group 1. The variation in Group 2 was slightly higher in initial period (i.e.) after 10 days and then it remains minimal from 6 weeks to 6 months. But in Group 1 the change in angle variation was minimal which worsen over 6 weeks and it continues to remain worse at 6 months. This statistical analysis was carried out using Independent t test (p value < 0.001)

In Group 1 the mean Cobb's (beta) angle level increased up to 22 degrees after 10th post-operative day and remained same until 6 months. In Group 2 the mean Cobb's (beta) angle level increased up to 17.7 degrees

after 10th post-operative day and remained same until 6 months as shown in table 1 and Graph 3. Within the post-operative time period the mean Cobb's (beta) angle level were similar after 10 days to 6 months with an increase of maximum 3.3 degrees in Group 2 (with transverse connector) also mean Cobb's (beta) angles were similar with a decrease of 0.9 degrees. This statistical analysis was carried out paired t test (p value < 0.001).

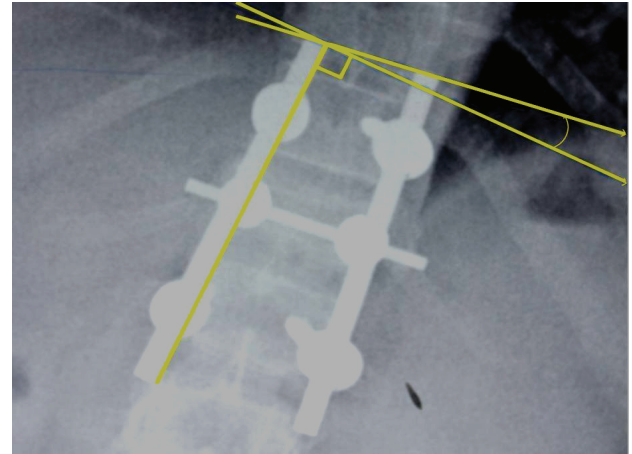
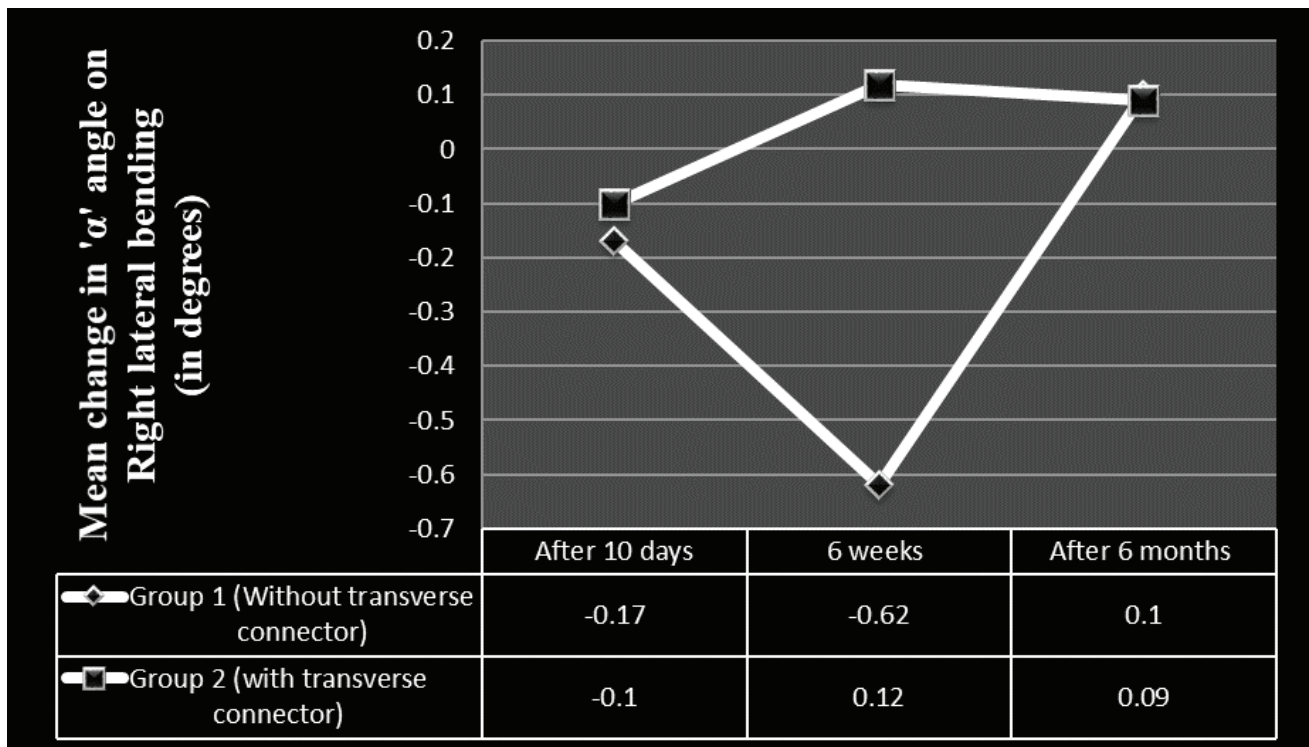
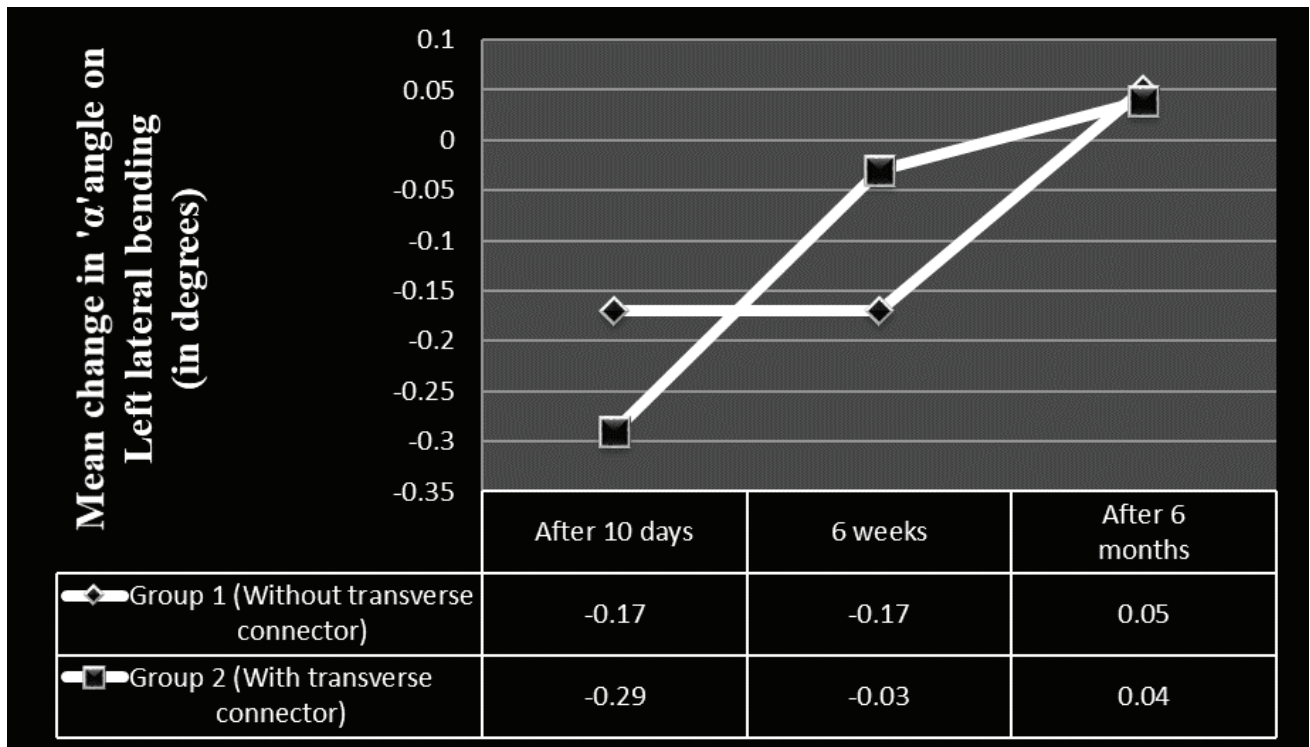


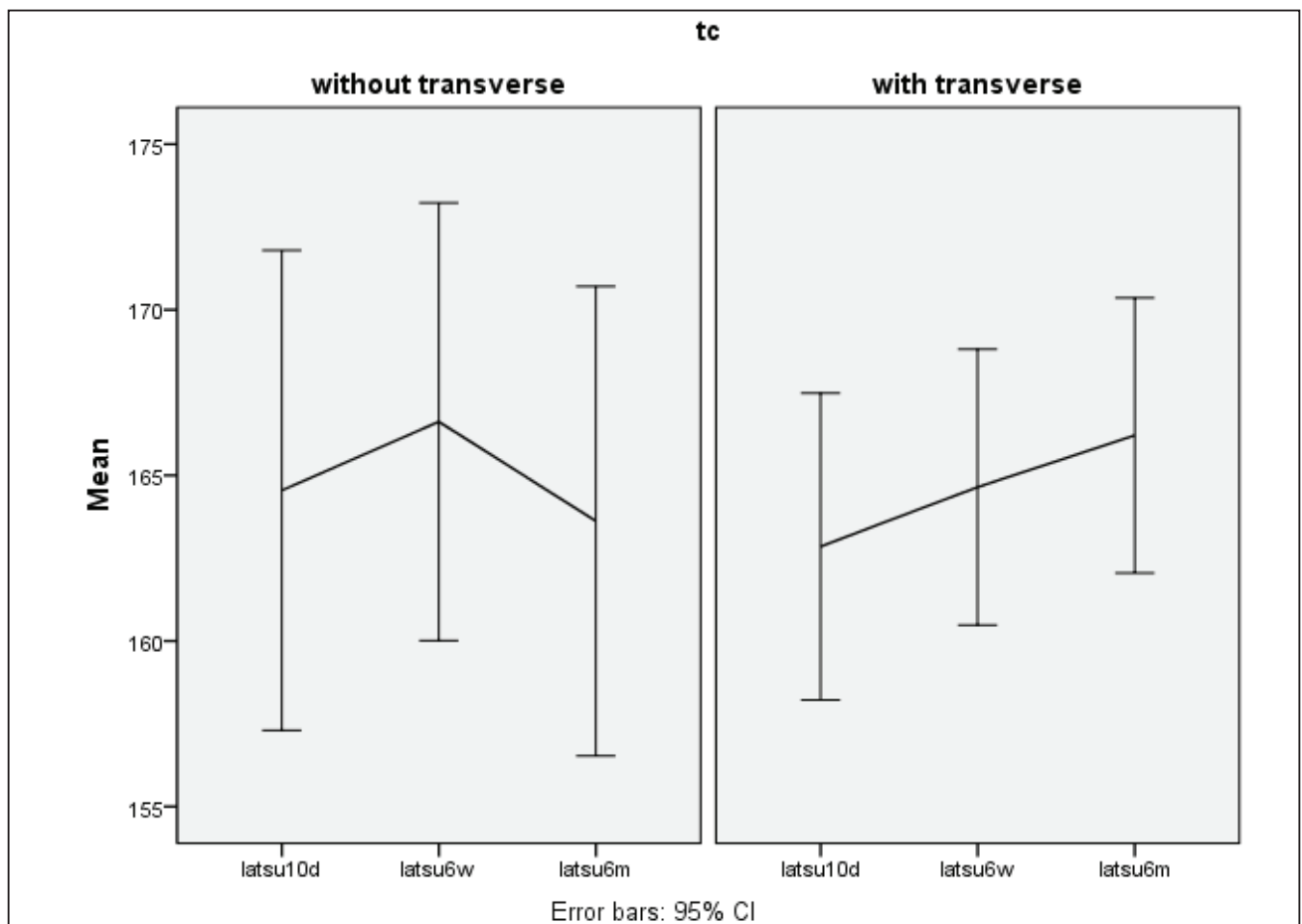
Figure 1: Radiograph of Dorso-Lumbar spine in Anteroposterior -Left lateral bending at sixth post-operative week showing measurement of the Left lateral bending angle.



Graph 1. Graphical representation showing trend in variation of alpha (α) angle after Right bending in group 1 and 2.



Graph 2. Graphical representation showing trend in variation of alpha (α) angle after Left bending in group 1 and 2.



Graph 3. Graphical representation showing change in Cobbs (Beta) angle during post-operative period in both Group 1 and Group 2 patients

Group	Cobbs (beta) angle pre-operatively in supine (pre_opkd)	Cobbs (beta) angle after 10th post-operative day in supine (latsu10d)	Cobbs (beta) angle at 6 weeks in supine (latsu6w)	Cobbs (beta) angle at 6 months in supine(latsu6m)
1	Mean	142.500	164.548	166.619
	N	21	21	21
	Std. Deviation	16.4187	15.9122	14.5146
2	Mean	145.191	162.853	164.647
	N	34	34	34
	Std. Deviation	14.9585	13.2828	11.9370
Total	Mean		163.500	165.400
	N		55	55
	Std. Deviation		14.2228	12.8857

Table 1: Correlation of two groups with respect to Mean and Standard deviation of Cobb's (Beta) angle in supine position at given time intervals

Discussion

The efficacy of transverse connector is controversial and conflicting reports has been published in the literature. There are concerns regarding the efficacy of these devices, as several other studies have failed to demonstrate any appreciable clinical benefits despite the significant additional cost of each supplementary transverse connector.⁶

Many surgeons all over the world have used transverse rod connectors to increase the axial and torsional stability of the instrumented spine. There were research studies done in vitro which evaluated increased torsional stability of the construct and common fatigue failure sites with use of transverse connector.^{7,8}

In cervical spine in vitro studies showed adding Transverse connector to C1 Lateral mass- C2 pars can effectively decrease the axial rotation and enhance the stability of C1-C2 segment.⁹

We used McAfee's system to classify the fractures after radiological evaluation. The most common fracture pattern in our study was wedge compression (63.6 %), as revealed in the CT scan. The second most common pattern was unstable burst fracture (30.9 %), followed by translational injuries (5.5 %). The CT reconstruction characteristically showed the mal-alignments. Unstable burst fractures and, in particular, translational injuries were associated with severe neurological involvement. Kim et al. also reported a high degree of neurological involvement in patients with posterior element involvement – i.e. burst fractures and rotational injuries.¹⁰ In the present study 38 % showed clustering of the spinal injuries at the first lumbar vertebra (L1) level and 47.3 % had mild neurological involvement. Other studies show clustering of thoraco-lumbar trauma around D12 and L1. Weyns et al. showed 60% injuries over D12- L1, Viale et al. 55% and Carl et al. 82% at D12-

L1 junction.^{11,12,13} During the surgery we did not observe any major intraoperative complications. However, Post-operatively six patients developed complications- one had bed sore and five developed urinary tract infection.

The improvements were observed in the radiological parameters (kyphotic deformity) measured pre and post-operatively. A good correction of kyphosis was achieved by surgery with 22 degree and 17.7 degree in Group 1 and Group2 respectively. None of the patients developed significant kyphotic collapse till six months follow-up. Kim et al shows the average preoperative kyphotic angle of all patients was 19.7 degree (+/-8.9), and corrected to 5.5 degree (+/-7.0) post-operatively, and progressed to 8.2 degree (+/-6.3) at the latest follow-up (14.6 months).¹⁴ Jin-Ho Hwang et al shows the mean preoperative, immediate postoperative and final kyphosis angles at the fracture site were respectively 20.8 degrees (+/- 6.4), 8.2 degrees (+/-4.8), and 15.2 degrees (+/- 6.0).¹⁵

Spinal rotation instability and its role in spinal fusions is difficult to measure. Numerous in vitro biomechanical studies have evaluated the use of transverse connector as adjuvants to posterior constructs. Dick et al analysed various designs of transverse connector in sawbones and Lynn et al explored the effect of adding Transverse connector to pedicle screw-rod constructs for thoracolumbar fractures in animal cadaveric models.^{16,17} Both studies concluded that transverse connector increased the torsional rigidity and rotational stiffness of constructs with transverse connector. But Lynn et al studied lateral bending also, which states that construct with one transverse connector was significantly stiffer than that without any transverse connector at 0.5 inch of displacement.¹⁷ Lim et al predicted improvement in both axial rotation and lateral bending when transverse connector is used. This study was also done in animal models in vitro.¹⁸

Our study states that transverse connector does help

in preventing parallelogram effect between the vertical rods especially while lateral bending and thus increases the stability of the implant.

Variation in Group 2 with transverse connector was slightly higher in initial period (i.e.) after 10 days and then it remains minimal from 6 weeks to 6 months. But in Group 1 without transverse connector the change in angle variation was minimal which worsen over 6 weeks and it continues to remain worse at 6 months, suggestive of parallelogram effect.

This is first study done in vivo which is done to study the role of transverse connector and evaluate any parallelogram effect in spinal instrumentation. We haven't studied torsional stability of instrumented spine as done in other studies.

Conclusion

Fractures and fracture dislocations of the spine are serious injuries and are occurring mostly among productive age group people. Therefore, their absence from the work can cost a lot to the patient, the patient's family and the nation as a whole. So early treatment and rehabilitation leading to early return to work can minimize the loss. The management and evaluation of these types of injuries have changed dramatically over the last decade due to improvement of imaging technologies and spinal instrumentation. The results showed that Moss Miami pedicle screw system with transverse connector provides stable, reliable, segmental construct, helps in immediate rehabilitation of patients. There was significant improvement in Kyphotic deformity after instrumentation. Transverse connector does play role in preventing parallelogram effect of implants and provides additional stability to the construct. We claim that this could be the first study done in vivo which is done to study the role of transverse connector and evaluate any parallelogram effect in spinal instrumentation.

Acknowledgement

We are thankful to XXXXXXXX and XXXXX for reviewing the article.

Funding: None

Conflict of interest: None

References

1. Walker CT, Kakarla UK, Chang SW, Sonntag VK. History and advances in spinal neurosurgery: JNSPG 75th anniversary invited review article. *Journal of Neurosurgery: Spine*. 2019;31(6):775-85. <https://doi.org/10.3171/2019.9.SPINE181362>
2. Leone A, Guglielmi G, Cassar-Pullicino VN, Bonomo L. Lumbar intervertebral instability: a review. *Radiology*. 2007;245(1):62-77. <https://doi.org/10.1148/radiol.2451051359>
3. Alhelal F. Design, development, manufacturing and biomechanical testing of Stand-alone cage for posterior lumbar interbody fusion.
4. Rajasekaran S, Kanna RM, Shetty AP. Management of thoracolumbar spine trauma. *Indian journal of orthopaedics*. 2015;49(1):72-82. <https://doi.org/10.4103/0019-5413.143914>
5. Krag MH, Weaver DL, Beynon BD, Haugh LD. Morphometry of the thoracic and lumbar spine related to transpedicular screw placement for surgical spinal fixation. *Spine*. 1988;13(1):27-32. <https://doi.org/10.1097/00007632-198801000-00007>
6. Wood KB, Wentorf FA, Ogilvie JW, Kim KT. Torsional rigidity of scoliosis constructs. *Spine*. 2000;25(15):1893-8. <https://doi.org/10.1097/00007632-200008010-00006>
7. Stambough JL, Sabri EH, Huston RL, Genaidy AM, Al-Khatib F, Serhan H. Effects of cross-linkage on fatigue life and failure modes of stainless steel posterior spinal constructs. *Journal of spinal disorders*. 1998;11(3):221-6. <https://doi.org/10.1097/00002517-199806000-00008>
8. Serhan H, Slivka M. Spinal implant transverse rod connectors: A delicate balance between stability and fatigue performance. In *Spinal Implants: Are We Evaluating Them Appropriately?* 2003 Jan. ASTM International.
9. Li T, Ma C, Du YQ, Qiao GY, Yu XG, Yin YH. The Role of Transverse Connectors in C1-C2 fixation for Atlantoaxial Instability: Is It Necessary? A Biomechanical Study. *World Neurosurgery*. 2020;140:e212-8. <https://doi.org/10.1016/j.wneu.2020.04.247>
10. Kim NH, Lee HM, Chun IM. Neurologic injury and recovery in patients with burst fracture of the thoracolumbar spine. *Spine*. 1999;24(3):290-3. <https://doi.org/10.1097/00007632-199902010-00020>
11. Weyns F, Rommens PM, Van Calenbergh F, Goffin J, Broos P, Plets C. Neurological outcome after surgery for thoracolumbar fractures. A retrospective study of 93 consecutive cases, treated with dorsal instrumentation. *Eur Spine J Off Publ Eur Spine Soc Eur Spinal Deform Soc Eur Sect Cerv Spine Res Soc*. 1994;3(5):276-81. <https://doi.org/10.1007/BF02226579>
12. Viale GL, Silvestro C, Francaviglia N, Carta F, Bragazzi R, Bernucci C, Maiello M. Transpedicular decompression and stabilization of burst fractures of the lumbar spine. *Surgical neurology*. 1993;40(2):104-11. [https://doi.org/10.1016/0090-3019\(93\)90119-L](https://doi.org/10.1016/0090-3019(93)90119-L)

13. Carl AL, Tromanhauser SG, Roger DJ. Pedicle screw instrumentation for thoracolumbar burst fractures and fracture-dislocations. *Spine*. 1992;17(8 Suppl):S317-24. <https://doi.org/10.1097/00007632-199208001-00018>
14. Kim KS, Oh SH, Huh JS, Noh JS, Chung BS. Dorsal short-segment fixation for unstable thoracolumbar junction fractures. *Journal of Korean Neurosurgical Society*. 2006;40(4):249-55. PMID:23826483
15. Hwang JH, Modi HN, Yang JH, Kim SJ, Lee SH. Short segment pedicle screw fixation for unstable T11-L2 fractures: with or without fusion? A three-year follow-up study. *Acta Orthop Belg*. 2009;75(6):822-7. PMID: 20166366
16. Dick JC, Zdeblick TA, Bartel BD, Kunz DN. Mechanical evaluation of cross-link designs in rigid pedicle screw systems. *Spine*. 1997;22(4):370-5. <https://doi.org/10.1097/00007632-199702150-00003>
17. Lynn G, Mukherjee DP, Kruse RN, Sadasivan KK, Albright JA. Mechanical stability of thoracolumbar pedicle screw fixation: the effect of crosslinks. *Spine*. 1997;22(14):1568-72. <https://doi.org/10.1097/00007632-199707150-00007>
18. Lim TH, Eck JC, An HS, Hong JH, Ahn JY, You JW. Biomechanics of transfixation in pedicle screw instrumentation. *Spine*. 1996;21(19):2224-9. <https://doi.org/10.1097/00007632-199610010-00009>