









# Anterior and middle skull base meningiomas: Experience from a sub-Saharan country of a series of 56 cases



Mohameth Faye MD<sup>1</sup> , Alioune Badara Thiam MD<sup>2</sup> , Louncény Fatoumata Barry MD<sup>3</sup> , El hadji Cheikh Ndiaye Sy MD<sup>4</sup> , Attoumane Fahad MD<sup>5</sup> , Maguette Mbaye MD<sup>6</sup> , Mbaye Thioub MD<sup>7</sup> , Momar Code Ba PhD<sup>8</sup> 

<sup>1,2,3,4,5,6,7,8</sup>Neurosurgery department, Fann Teaching Hospital, BP5035, Dakar, Senegal

Date of submission: 7<sup>th</sup> January 2021

Date of acceptance: 8<sup>th</sup> May 2021

Date of publication: 1<sup>st</sup> June 2021

## Abstract

**Introduction:** Skull base meningiomas represent 25% of all meningiomas. Mostly slow-growing, the challenge lies in their relationship with the circle of Willis and cranial nerves. The objective of our study was to evaluate the management of meningiomas of the anterior and middle cranial fossa in a sub-Saharan setting.

**Methods and Materials:** A series of 56 patients hospitalized for meningiomas of the anterior and middle cranial fossa were retrospectively reviewed and analyzed, from January 2012 to December 2018.

**Results:** Anterior and middle cranial fossa meningiomas represented 32.7 % of intracranial meningiomas in the department. The mean age was 50.5 years and the sex ratio were 0.3. Clinical manifestations were dominated by visual disorders (57.1%) and intracranial hypertension (26.8%). The mean tumor size was 54.3 mm. The pterional approach was used on 94.6% of patients. The quality of resection was SIMPSON grade II in 71.4% of cases. Postoperative mortality was 14.2%. The pathology was grade I in 91.1% of cases. Over a 3-year follow-up, complete recovery was noted in 67.8% of cases. Two cases had recurrence.

**Conclusion:** Meningiomas are the most common tumor of the anterior and middle cranial fossa in the institution. Microsurgical excision was the only treatment performed. Complete recovery without sequelae was observed in 67.8% of cases. The improvement in the instrumentation and neuro-intensive care helped to reduce mortality and morbidity, but efforts still need to be made, especially in the development of complementary treatments.

**Key words:** Anterior, Meningioma, Middle, Skull base.

## Introduction

Meningiomas, well known since the Harvey Cushing monograph, are extra-axial tumors arising from arachnoid cap cells.<sup>1</sup> They account for 15 to 30% of

intracranial tumors.<sup>2,3</sup> Skull base meningiomas represent 25% of all meningiomas and are classified according to their implantation on the dura mater.<sup>4,5</sup> To date, only a few studies report on the outcomes of skull base meningiomas in our region. In that perspective, we reviewed our data, to evaluate the feature and outcomes of surgical treatment of anterior and middle cranial fossa meningiomas in our institution.

## Methods and Materials

We conducted a retrospective and descriptive study, from January 2012 to December 2018. We analyzed the records of patients hospitalized for meningiomas of the anterior and middle cranial fossa at the neurosurgical department of Fann Teaching Hospital, in Dakar. Patient consents were obtained to use these data and the study was approved by the Fann Teaching Hospital Ethics Committee. We included all patients operated for meningiomas of the anterior or middle cranial fossa with a minimum of one-year postoperative follow-up. We excluded non-operated patients, patients with incomplete records, and those with less than one-year postoperative follow-up. A total of 56 patients were selected. We analyzed frequency, age, sex

### Access this article online

Website: <https://www.nepjol.info/index.php/NJN>

DOI: <https://doi.org/10.3126/njn.v18i2.34124>

### HOW TO CITE

Faye M, Thiam AB, Barry LF, Sy ECN, Fahad A, Mbaye M, Thioub M, Ba MC. Anterior and middle skull base meningiomas: Experience from a sub-Saharan country of a series of 56 cases. *NJNS*. 2021;18(2):30-5.



### Address for correspondence:

Dr. Louncény Fatoumata Barry  
5454 Dakar, Senegal.  
E-mail: [drlcbarry@gmail.com](mailto:drlcbarry@gmail.com)  
Phone: +221 781390566

Copyright © 2021 Nepalese Society of Neurosurgeons (NESON)

ISSN: 1813-1948 (Print), 1813-1956 (Online)



This work is licensed under a Creative Commons Attribution-Non Commercial 4.0 International License.

## Anterior and middle skull base meningiomas

ratio, symptomatology, size of the tumor, topography of the lesion, surgical approach, quality of resection (Simpson), histology, postoperative morbidity and mortality, and clinical course at one year. The data was analyzed using SPSS 21.0 software.

### Results

During the study period, 171 patients were operated for intracranial meningiomas, 56 of them had meningiomas of the anterior or middle cranial fossa (32.7%). The ages vary between 23 and 78 years and the mean age was 50.5 years. Forty-two out of 56 were women and the sex ratio were 0.3. The mean time before diagnosis was two years and ranged from two months to 13 years. Regarding ethnicity, all our patients were black ethnic group.

Clinical manifestations were dominated by visual disturbance observed on 32 cases (57.1%), followed by intracranial hypertension seen in 15 cases (26.8%). Table 1 summarizes the clinical manifestations.

	N	%
Intracranial hypertension	15	26,7
Obnubilation	7	12,5
Seizures	12	21,4
Behaviour disorders	5	8,9
Visual disturbances	32	57,1
Decreased visual acuity	14	25
Blindness	11	19,6
Diplopia	5	8,9
Foster Kennedy Syndrome	2	3,5
Olfactory disorders	9	16
Anosmia	7	12,5
Hyposmia	2	3,5

Table 1: Clinical presentation

A cerebral computed tomography (CT) scan was performed on each patient, while only 11 patients required a complementary MRI. We observed 15 cases of olfactory groove meningiomas, 26.8% (see figure 1), nine cases of planum sphenoidal meningiomas (16%), seven cases of tuberculum sellae meningiomas (12.5%), six cases of sphenoid-orbital meningiomas (10,7%), eleven cases of anterior clinoid meningiomas (19.6%), and eight cases of sphenoid wing meningiomas, 14.2% (see figure 2). The mean tumor size was 53,3 millimeters. In 5 cases (8.9%), there was compression of the optic chiasma and in 16 cases (28.5%), an entrapment of a portion of the polygon of Willis was covered.

The pterional approach was used in 53 patients and the bilateral subfrontal approach in 3 patients who had large olfactory groove meningioma. The quality of resection was classified as SIMPSON II in 40 cases (71.4%), SIMPSON III in 15 cases (26.7%), and SIMPSON IV in 1 case (1.7%). The pathology showed a predominance of WHO grade I in 51 patients (91.1%). Five patients had a grade II meningioma (9.9%).

Postoperative mortality was 14.2% (eight patients). Infection (four cases of pneumopathy and one case of meningitis) and vascular injury (two cases of carotid ischemia and one case of sylvian ischemia) were the main cause of death.

We had two cases of cutaneous infections and one case of empyema which was evacuated. One patient had a meningocele which resolved in one week. The evolution within three years of follow-up was marked by a complete recovery without sequelae in 38 patients (67.8%). We noted the persistence of preoperative cranial nerve neuropathy in 18 patients: Blindness in 08 cases, third cranial nerve palsy in one case, and anosmia in 9 cases.

Recurrence was noted in two cases, it was atypical meningioma (WHO grade II). No additional treatment was performed.

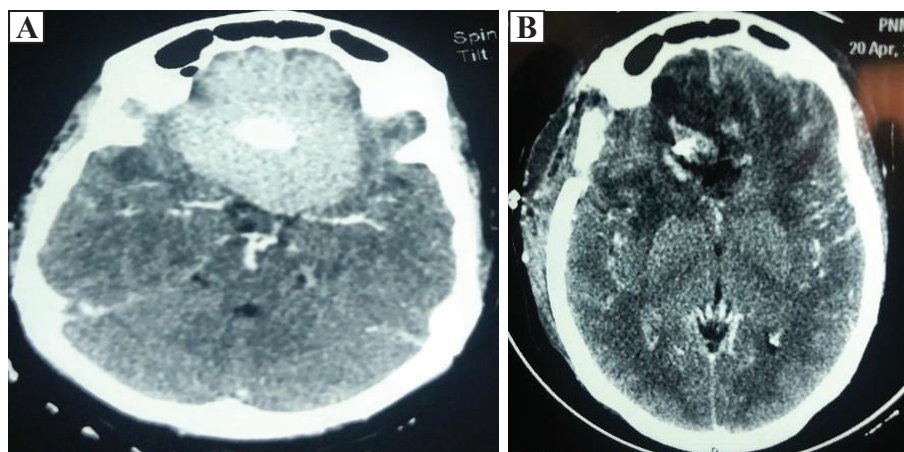


Figure 1: Olfactory groove meningioma (A: preoperative CT scan; B: postoperative CT scan)

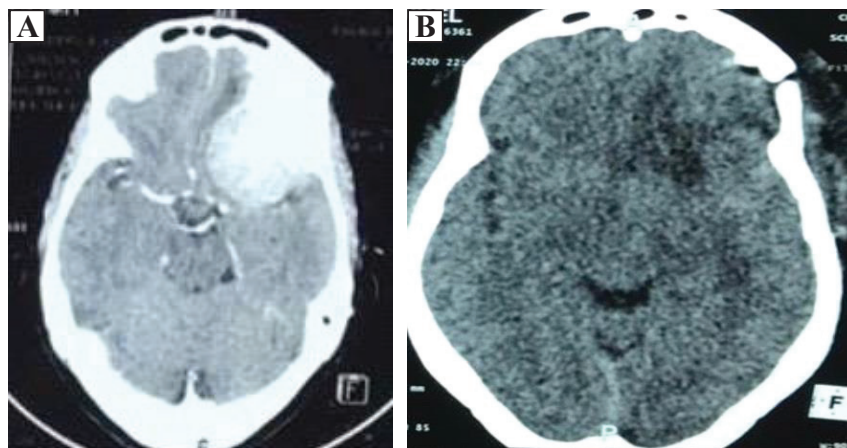


Figure 2: Sphenoid wing meningioma (A: preoperative CT scan; B: postoperative CT scan)

### Discussion

Meningiomas are benign tumors in 75 to 95% of cases. They are, mainly, observed in women with a sex ratio of two:one.<sup>6-8</sup> Similarly, women predominance is clearly observed in our series with 42 women out of 56 patients. The incidence of meningioma increases in adults with a peak in the fifth decade.<sup>2,5,6</sup> Which agrees with the mean age of 50.5 years in this study. Some authors reported a higher incidence in Black population than in Hispanic and Caucasian populations.<sup>9-10</sup>

The incidence of skull base meningiomas varies in the literature. Thiam et al.<sup>10</sup> have reported 35% of skull base meningiomas cases in their study, while Mansour et al.<sup>11</sup> have reported 32% of cases, and 27.1% of cases have been reported by Chan et al.<sup>4</sup> We've found 32.7% for anterior and middle skull base meningioma in our series.

The time before diagnosis was long in our series, the mean time was 24 months. This is due to the paucity of the symptomatology at the beginning which does not motivate consultations in rural areas. It is, also, imputable to the lack of specialists in some remote areas. Badiane et al.<sup>12</sup>, in a series of 79 cases, the mean time before diagnosis was 15 months. Mansour et al.<sup>11</sup> also found a long delay before diagnosis. This is largely the case in sub-Saharan countries.

Meningiomas are, generally, slow-growing and benign tumors. Their clinical expression varies according to the topography and the size of the lesion.<sup>5</sup> The symptomatology is 57.1% dominated by visual disorders in our study. However, it may vary between 70 and 75% as reported in other studies.<sup>13-15</sup> In our case, seven patients (12,5%) have experienced a loss of consciousness due to an acute increase of intracranial pressure, this is a rare feature in anterior and middle skull base meningiomas. It denotes the late diagnosis of these slow-growing lesions. Foster Kennedy syndrome, characterized by homolateral

optic atrophy and contralateral papillary edema, was seen in 24% of cases in the Cushing series,<sup>1</sup> it is rarely reported in modern series.<sup>16-19</sup>

Regarding the topography, olfactory meningiomas were the most frequent in our study and represented 26.8% of the series. It represents 15.79% of meningiomas of the skull base according to Aguiar et al.<sup>20</sup> Meningiomas of the jugum sphenoidal accounted for 16% of cases in our series. Cases of meningiomas of the tuberculum sellae are scarce in our study. In the literature, they represent 4% to 10% of intracranial meningiomas.<sup>15,21,22</sup> Sphenoorbital meningiomas represented 10.7% of our series; it constitutes 9% of intracranial meningiomas in the literature.<sup>23,24</sup> Sphenoid wing meningiomas accounted for 25% of cases in our series and similar epidemiology is reported in the literature.<sup>25</sup> In our series, we did not find any en-plaque meningiomas. These were mainly mass meningiomas.

Surgery was the main treatment for all our patients. No pre-operative embolization was indicated. A pterional craniotomy was performed in 53 patients. It gave access to the anterior and middle fossa and allowed early visualization of the vasculature and to widely expose these lesions without having to resort to orbito-zygoma removal. It is our preferred approach. A bilateral subfrontal approach was performed in 3 giant olfactory groove meningiomas, it allowed early devascularization of the tumor and safe dissection on the lateral and superior pole of the lesion.

In all surgeries, the treatment objective was to achieve a gross total resection with preservation of neurological function. We achieved a SIMPSON grade II resection in 71.4% of cases. We could not achieve gross total resection when the tumor was adherent to the vasculature and when there was cavernous sinus invasion. Chan et al. had 35% of gross total resection in their series.<sup>4</sup> There is a direct correlation between progression-free survival and the extent of resection. However, in the skull base, SIMPSON

grade I is rarely achieved, even with modern microsurgical techniques. It is largely due to the relationship with the cranial nerves, the vasculature, and the risk of CSF leak.<sup>26-31</sup> In our series, complete resection was associated with a vascular injury in three cases (two cases of total carotid ischemia and one case of total sylvian ischemia), requiring emergency decompressive craniectomy.

Postoperative mortality was 14.2% in our series, which agrees with other studies<sup>4,32-36</sup> that report a variation between zero and 18.5%. Death was secondary to infection in five cases (one case of meningitis and four cases of pulmonary infection). Despite the advances in neuro-intensive care, we still have in our region large morbidity and mortality due to infection. We had three patients who died because of increased intracranial pressure due to vascular injury despite an emergency decompressive craniotomy.

Regarding the anatomic-pathological results, 91.1% of meningiomas were WHO grade I, and 9.9% were WHO grade II. Mortazavi et al. reported in their series 88.8% of grade I cases and 11% grade II.<sup>37</sup> They did not find grade III meningioma cases; they are seldom found in the skull base.

In the last follow-up, the evolution was marked by complete clinical remission in 67.8% of patients. As sequels, we noted 14.8% blindness (8 cases), 1.7% paralysis of the third cranial nerve (1 case) and 16% anosmia (9 cases). Recurrence was noted in two cases of atypical meningioma (WHO grade II). However, because of the short period of follow-up, we cannot appreciate objectively the recurrence rate of the series. The average time before recurrence is four years in the literature; the main prognostic factors are the extent of resection and histopathology. Nevertheless, recurrence may occur after 15 or even 20 years, despite a SIMPSON grade I resection.<sup>38</sup> Mahmood et al. described relapse rates at 10 years of two percent after complete removal and 64% after incomplete removal. For malignant meningiomas, they described a recurrence rate of 75%, 10 years after complete removal, and 75%, one year after incomplete removal.<sup>38,39</sup> The location of the meningioma has also been described as a risk factor of recurrences such as sphenoid wing and the orbital meningiomas.<sup>28</sup>

Regarding adjuvant treatment, none of our patients had radiotherapy or chemotherapy.

## Conclusion

Incidence of anterior and middle cranial fossa meningiomas in our institution was 32.7% of all meningiomas. The symptomatology is dominated by visual disturbance. Surgical excision was the only treatment performed. We noted a complete recovery without sequelae of 67.8%. Long-term follow-up is

needed to assess the recurrence rate of this slow-growing tumor. Improvement is needed in neuro-intensive care and early diagnosis.

**Conflict of Interest:** None

**Source(s) of support:** None

## References

1. Cushing H, Eisenhardt L. Meningiomas, their classification, regional behavior, life history and surgical results. Springfield. 1938;1-785.<https://doi.org/10.1002/bjs.18002610438>
2. Laurent R, Alejandro M, Claire H, Abderrahmane H, Xavier M. Surgery of intracranial meningiomas after 80 years. Med Press. 2007;36:197-202.<https://doi.org/10.1016/j.lpm.2006.11.009>
3. Duntze PJ, Metellus CF, Litre C, Eap E, Theret P, et al. Management of WHO grade II and III meningiomas: A retrospective monocentric study of a surgical series of 36 cases. Neurochirurgie. 2012;58:275-81.<https://doi.org/10.1016/j.neuchi.2012.01.006>
4. ChanChee K, Regunath K, Saffari H, Zamzuri I, Jafri AM. Incidence, clinico-radiological features and outcome of skull base versus non-skull base meningiomas treated in Kuala Lumpur General Hospital: A five-year experience. Malays J Med Sci. 2018;25(3): 88–102.<https://doi.org/10.21315/mjms2018.25.3.9>
5. Brahimi Y, Antoni D, Srour R, Proust F, Cebula H, Labani A. Meningiomas of the base of the skull: clinical efficacy and tolerance, radiological efficacy and tumor kinetics after radiotherapy. Cancer/Radiotherapy. 2018;22:264-86.<https://doi.org/10.1016/j.canrad.2018.11.005>
6. Bondy M, LeeLigon B. Epidemiology and etiology of intracranial meningiomas: a review. J Neuro oncol 1996;29:197-205.<https://doi.org/10.1007/BF00165649>.
7. Nakasu S, Fukami T, Nakajima M, Watanabe K, Ichikawa M, Matsuda M. Growth pattern changes of meningiomas: long term analysis. Neurosurgery 2005;56(5):946-55.<https://doi.org/10.1227/01.NEU.0000157958.20215.7F>.
8. Wong R, Wong A, Vick N, Farhat H. Natural history of multiple meningiomas. Surg Neurol Int 2013; 4 (1):71.<https://doi.org/10.4103/2152-7806.112617>.
9. Dolecek TA, Propp JM, Stroup NE, Kruchko C. CB TRUS statistical report: primary brain and central nervous system tumors diagnosed in the United States in 2005–2009. Neurooncology 2012; 14 (Suppl. 5): v1–49.<https://doi.org/10.1093/neuonc/nos218>.
10. Thiam AB, Kessely YC, Mbaye T, Mbaye M, Faye M, Sy ECN. Our experience of intracranial meningioma

- in Dakar: about 50 cases. *Pan African Medical Journal*. 2015;20 :379.<https://doi.org/10.11604/pamj.2015.20.379.6070>
11. Mansour A, Bairi S, Ziani A, Bouaziz M. Intracranial Meningioma: experience of Algerian service about 220 cases. *Service de Neurosurgery department, CHU Annaba, Neurochirurgie* 2012; 58: 447.<https://doi.org/10.1016/j.neuchi.2012.10.126>.
  12. Badiane SB, Sakho Y, BA MC, Gueye EM, Ndiaye MM, Gueye M. Intracranial Meningioma. Dakar's experience about 79 cases. *Neurochirurgie* 1999; 45: 134-138.
  13. Chicani CF, Miller NR. Visual outcome in surgically treated suprasellar meningiomas. *J Neuro ophthalmol* 2003;23(1):3–10.<https://doi.org/10.1097/00041327-200303000-00002>.
  14. Pallini R, Fernandez E, Lauretti L, Doglietto F, D'Alessandris QG, Montano N, Capo G, Meglio M, Maira G. Olfactory groove meningioma: report of 99 cases surgically treated at the Catholic University School of Medicine, Rome. *World Neurosurg*. 2015 Feb; 83(2):219-31.<https://doi.org/10.1016/j.wneu.2014.11.001>.
  15. Goel A, Muzumdar D, Desai KI. Tuberculum sellae meningioma: a report on management based on a surgical experience with 70 patients. *Neurosurgery* 2002; 51:1358–63.<https://doi.org/10.1227/01.NEU.0000309111.78968.BC>.
  16. Welge-Luessen A, Temmel A, Quint C, Moll B, Wolf S, Hummel T. Olfactory function in patients with olfactory groove meningioma. *J Neurol Neurosurg Psychiatry* 2001;70(2):218–221.<https://dx.doi.org/10.1136%2Fjnp.70.2.218>.
  17. Gazzeri R, Galarza M, Gazzeri G. Giant olfactory groove meningioma: ophthalmological and cognitive outcome after bifrontal microsurgical approach. *Acta Neurochir (Wien)* 2008;150 (11):1117–1125.<https://doi.org/10.1007/s00701-008-0142-z>.
  18. Mendenhall WM, Friedman WA, Amdur RJ, Foote KD. Management of benign skull base meningiomas: a review. *Skull Base*, 2004. 14(1):53–60.<https://dx.doi.org/10.1055%2Fs-2004-821364>.
  19. Souto AA, Chimelli L, Takyá CM, Souza JM, Fonseca AL, Silva LF. Brain edema in meningiomas: radiological and histological factors. *Arq Neuropsiquiatr* 2002; 60:807–817.
  20. Aguiar PH, Tahara A, Almeida AN. Olfactory groove meningiomas: approaches and complications. *J Clin Neurosci* 2009; 16(9):1168–1173.<https://doi.org/10.1016/j.jocn.2008.12.013>.
  21. Bassiouni H, Asgari S, Stolke D. Tuberculum sellae meningiomas: Functional outcome in a consecutive series treated microsurgically. *Surgical Neurology* 2006;66 (1): 37-44.<https://doi.org/10.1016/j.surneu.2005.11.059>.
  22. Jallo GI, Benjamin V. Tuberculum sellae meningiomas: microsurgical anatomy and surgical technique. *Neurosurgery* 2002; 51: 1432- 40.<https://doi.org/10.1227/01.neu.0000309119.55205.af>.
  23. Ringel F, Cedzich C, Schramm J. Microsurgical technique and results of a series of 63 sphenoidal meningiomas. *Neurosurgery* 2007;60(4, suppl 2):214–221.<https://doi.org/10.1227/01.neu.0000255415.47937.1a>.
  24. MacCarty CS, Piepgras DG, Ebersold MJ. Meningeal tumors of the brain. In: Youmans Jr, ed. *Neurological Surgery*. 2nd ed. Philadelphia, PA: WB Saunders; 1982;2936–2966.
  25. Jacobs DH, McFarlane MJ, Holmes FF. Female patients with meningioma of the sphenoid Ridge and additional primary neoplasms of the breast and genital tract;1987; *Cancer* 60: 3080.
  26. Nanda A, Thakur JD, Sonig A, Missios S. Microsurgical resectability, outcomes, and tumor control in meningiomas occupying the cavernous sinus. *J Neurosurg* 2016; 125:378–92.<https://doi.org/10.3171/2015.3.jns142494>.
  27. Couldwell WT, MacDonald JD, Tausky P. Complete resection of the cavernous sinus—indications and techniques. *World Neurosurg* 2014; 82:1264-70. <https://doi.org/10.1016/j.wneu.2013.08.026>.
  28. Simpson D. The recurrence of intracranial meningiomas after surgical treatment. *JNeuroNeurosurgPsychiatry*1957; 20:22–39.
  29. Li D, Tang J, Ren C, Wu Z, Zhang L-W, Zhang JT. Surgical management of medium and large petroclival meningiomas: a single institution's experience of 199caseswithlong-termfollow-up. *Acta Neurochir (Wien)* 2016; 158:409– 25.<https://doi.org/10.1007/s00701-015-2671-6>.
  30. Pichierri A, Santoro A, Raco A, Paolini S, Cantore G, Delfini R. Cavernous sinus meningiomas: retrospective analysis and proposal of a treatment algorithm. *Neurosurgery* 2009; 64:1090–101.<https://doi.org/10.1227/01.neu.0000346023.52541.0a>.
  31. Sen C, Hague K. Meningiomas involving the cavernous sinus: histological factors affecting the degree of resection. *J Neurosurg* 1997; 87: 535–43. <https://doi.org/10.3171/jns.1997.87.4.0535>.
  32. Honig S, Trantakis C, Frerich B, Sterke I, Kortmann RD, Meixens berger J. Meningiomas involving the sphenoid wing outcome after microsurgical treatment—a clinical review of 73 cases. *Cen Eur Neurosurg*. 2010;71(4):189–198.<https://doi.org/10.1055/s-0030-1261945>.
  33. Wu Z, Hao S, Zhang J, Zhang L, Jia G, Tang J. Foramen magnum meningiomas: experiences in 114 patients at a single institute over 15 years. *Surg Neurol*. 2009; 72:376–382.<https://doi.org/10.1016/j.surneu.2009.05.006>.

34. Nakamura M, Roser F, Struck M, Vorkapic P, Samii M. Tuberculum sellae meningiomas: clinical outcome considering different surgical approaches. *Neurosurgery* 2006;59(5):1019–1028. <https://doi.org/10.1227/01.neu.0000245600.92322.06>.
35. Nakamura M, Struck M, Roser F, Vorkapic P, Samii M. Olfactory groove meningiomas: clinical outcome and recurrence rates after tumor removal through the frontolateral and bifrontal approach. *Neurosurgery*. 2007; 60:844–852. <https://doi.org/10.1227/01.neu.0000255453.20602.80>.
36. Spektor S, Valarezo J, Fliss DM, Gil Z, Cohen J, Goldman J. Olfactory groove meningiomas from neurosurgical and ear, nose, and throat perspectives: approaches, techniques, and outcomes. *Neurosurgery*. 2005;57(4):268–280. <https://doi.org/10.1227/01.neu.0000176409.70668.eb>.
37. Mortazavi MM, Brito da Silva H, Ferreira M Jr, Barber JK, Pridgeon JS, Sekhar LN. Planum Sphenoidale and Tuberculum Sellae Meningiomas: Operative Nuances of a Modern Surgical Technique with Outcome and Proposal of a New Classification System. *World Neurosurg*. 2016; 86:270-86. <https://doi.org/10.1016/j.wneu.2015.09.043>.
38. Mahmood A, Caccamo DV, Tomecek FJ, Malik GM. Atypical and malignant meningioma: a clinicopathological review. *Neurosurgery*. 1993; 33:955-63. <https://doi.org/10.1227/00006123-199312000-0000>.
39. Condra KS, Buatti JM, Mendenhall WM, Friedman WA, Marcus RB, Rhoton AL. Benign meningiomas: Primary treatment selection affects survival. *International journal of Radiation oncology, biology, and physics* 1997; 39:427. [https://doi.org/10.1016/s0360-3016\(97\)00317-9](https://doi.org/10.1016/s0360-3016(97)00317-9).