

# Juvenile variant ossifying fibroma of sinonasal region


Susan Pradhan *MBBS*<sup>1</sup>, Suman Phuyal *MS*<sup>2</sup>, Dipendra Kumar Shrestha *MCh*<sup>3</sup>, Sushil Krishna Shilpakar *MS*<sup>4</sup>

<sup>1,2,3,4</sup>Department of Neurosurgery, Tribhuvan University Teaching Hospital, Nepal

Date of submission: 28<sup>th</sup> April 2020

Date of acceptance: 7<sup>th</sup> August 2020

Date of publication: 12<sup>th</sup> August 2020



## Abstract

Juvenile variant ossifying fibroma of sinonasal region is an extremely rare benign fibro-osseous lesion which is locally aggressive. A 21-year-old male presented with significant proptosis of right eye with stony-hard lump in the middle upper aspect of the right orbit and base of the nose. CT scan of head revealed a non-enhancing expansile lesion in right ethmoidal cells consistent with chronic ethmoidal mucocele. However Magnetic Resonance Imaging of brain revealed enhancing lesion in right ethmoid and frontal sinus extending up to anterior cranial fossa. He underwent right frontal craniotomy with surgical excision of tumor wherein cystic brown tumor of frontal and ethmoidal sinus was found. The procedure was supplemented with endoscopic transnasal approach. Histopathology report suggested an ossifying fibroma. This case highlights the importance of clinical, imaging and histopathological features of ossifying fibroma occurring in the sinonasal tract for better diagnosis and treatment through a multidisciplinary approach.

**Key words:** Juvenile variant ossifying fibroma, Proptosis, Sinonasal

## Introduction

Ossifying fibroma is a rare benign well-differentiated fibro-osseous lesions, distinguishing itself from fibrous dysplasia with characteristic substitution of normal bone by a fibrous cellular stroma containing various amounts of foci of mineralization or ossification.<sup>1,2</sup> It is usually found in the craniofacial bones, with the mandible being the most common site, accounting for 75 - 89% of

the cases.<sup>3</sup> However, juvenile variant which is more locally aggressive and commonly occurring in the sinonasal tract is extremely rare.<sup>4</sup> We report a young adult with ossifying fibroma of right ethmoidal and frontal sinus, who was surgically managed via multidisciplinary approach.

## Case Report

A 21-year-old male college student presented to Neurosurgical Out-patient Clinic with swelling of the right eye for two years. It had insidious onset and was progressive in nature. He also complained of double vision and lacrimation in his right eye. In addition, he had frequent nasal congestion for one year with decreased perception of smell. At times, he noticed mild to moderate intermittent pain over the right side of his forehead and right eye. There was no history of seizure, trauma, loss of consciousness or any other comorbidities in the past.

On examination, Glasgow Coma Scale (GCS) was 15/15 with bilateral pupils, round and reactive to light. There was significant proptosis of right eye with stony-hard lump in the middle upper aspect of the right orbit and base of the nose. However, he was able to move his eyeballs in all directions.

CT scan of head revealed a non-enhancing expansile in the supraorbital region and involving the right ethmoidal cells, consisting of low-attenuated internal contents, protruding into the brain parenchyma superiorly. Moreover, the lesion caused significant compression of the right orbital cavity. Radiologically, it was reported to be

### Access this article online

Website: <https://www.nepjol.info/index.php/NJN>

DOI: <https://doi.org/10.3126/njn.v17i2.30551>

### HOW TO CITE

Pradhan S, Phuyal S, Shrestha DK, Shilpakar SK. Juvenile variant ossifying fibroma of sinonasal region. *NJNS*. 2020;17(2):77-81



<sup>1</sup>ORCID id: <https://orcid.org/0000-0003-4252-5465>

<sup>2</sup>ORCID id: <https://orcid.org/0000-0001-6635-8636>

<sup>3</sup>ORCID id: <https://orcid.org/0000-0002-5540-7989>

<sup>4</sup>ORCID id: <https://orcid.org/0000-0001-9222-4762>

### Address for correspondence:

Dr. Susan Pradhan,  
Department of Neurosurgery,  
Tribhuvan University Teaching Hospital,  
Maharjung, Kathmandu, Nepal  
Contact number: +977 9849024474  
E-mail: [drsusanpradhan@gmail.com](mailto:drsusanpradhan@gmail.com)

Copyright © 2020 Nepalese Society of Neurosurgeons (NESON)

ISSN: 1813-1948 (Print), 1813-1956 (Online)



This work is licensed under a Creative Commons Attribution-Non Commercial 4.0 International License.

consistent with a chronic ethmoidal mucocele. (**Figure 1**)

Magnetic Resonance Imaging (MRI) of brain demonstrated T1 low, T2 and FLAIR heterogeneously-hyperintense, enhancing lesion in right ethmoid and frontal sinuses, which extended up to anterior cranial fossa. The lesion was bulging into the extraconal compartment of the right orbit. (Figure 2)

Prior to neurosurgical visit, the patient had consulted Department of Ear, Nose, Throat (ENT). As a part of the preoperative surgical planning, combined Neurosurgery and ENT multidisciplinary approach was decided. With a clinico-radiological diagnosis of right supraorbital-ethmoidal mixed tumor with intracranial extension, combined surgery (initially, transcranial approach by Neurosurgical team, followed by endoscopic transnasal route) was planned.

The patient was kept supine with head in midline position and given endotracheal general anesthesia. Initially, the neurosurgical team performed a right frontal craniotomy for surgical excision of intracranial-orbital portion of the tumor. A curvilinear scalp incision extending from right tragus to widow's peak behind hairline was made. Using NSK neuro-electric drill, right frontal craniotomy was performed. Intraoperatively, cystic brown tumor of frontal and ethmoid sinuses was found to be extending up to right frontobasal region, compressing the right frontal lobe. The tumor was abutting superomedial wall of right orbit and thinned out the orbital wall on medial side. The inferior part was seen to extend into the nasal cavity and involved the ethmoid sinus. The right frontal sinus was deroofed; and the brownish tumor tissue was meticulously removed using curette and Bovie electrocautery. The expanded bony part of the tumor was carefully drilled off until the normal periorbita was encountered. After removal of macroscopically-visible tumor, both bony and soft, and

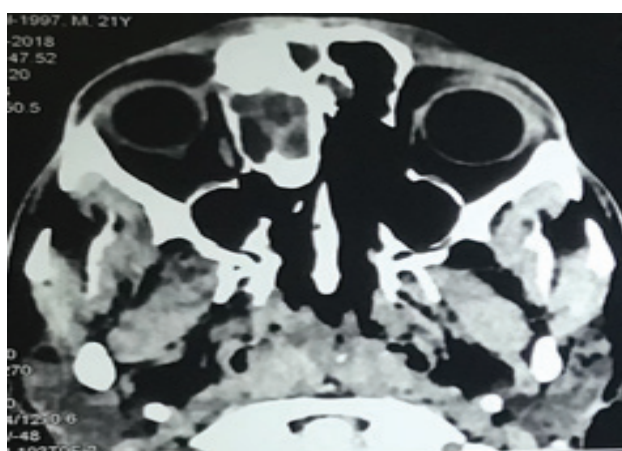thorough hemostasis, the frontal sinus area packed with surgical strips and compartmentalized using pericranial flap. No CSF leakage was noted. The bone flap was fixed with titanium mini plates and screws.

The transnasal endoscopic approach was performed by ENT team. The remaining inferior nasal and orbital part of the tumor was meticulously removed via an endoscope. After complete removal of the inferior part of tumor and strict hemostasis, a nasoseptal flap was raised and reflected to reconstruct right frontonasoorbital floor. The right nasal cavity was packed with paraffin-ribbon gauze, which was removed after two days.

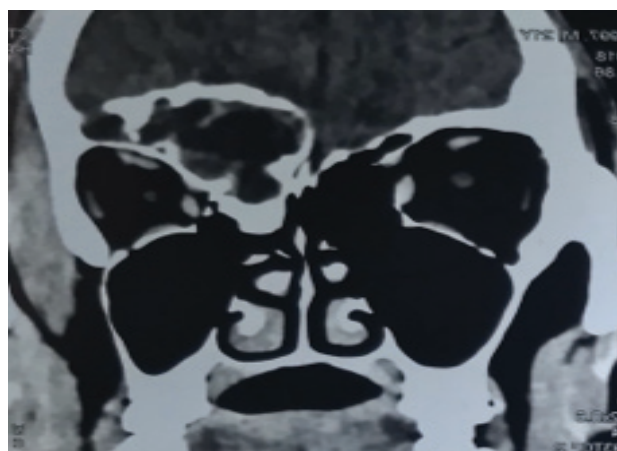
The postoperative course was uneventful. The patient was discharged on 3<sup>rd</sup> postoperative day (POD) ; and the staples were removed on POD#10 in the Neurosurgical Clinic. Postoperatively, the patient complained of vertical diplopia in his right eye. An impression of GS II by ENT consultant and was planned for HESS charting and a repeat diplopia charting. At the time of discharge, proptosis and lacrimation of the right eye had subsided along with improvement of smell perception and reduction in nasal obstruction. However, vertical diplopia was still persistent on discharge.

Histopathological examination reported tumor tissue composed of small immature bony trabeculae, rimmed by osteoblasts with fibroblastic cells in between. The findings were consistent with an ossifying fibroma of right ethmoid-frontal sinus. (Figure 3)

On three-month follow-up, the vertical diplopia had disappeared. Follow-up MRI of brain, orbit and PNS showed a small ill-defined enhancing mass in the right frontal and ethmoidal sinus with involvement of the roof and the middle wall of the right orbit, showing evidences of likely recurrence. (Figure 4) Presently, the patient is on regular follow up with wait and watch strategy.



1(A)



1(B)

**Figure 1:** CT head showing an expansile lesion in the supraorbital-ethmoid region. (A) axial and (B) coronal reconstruction views.

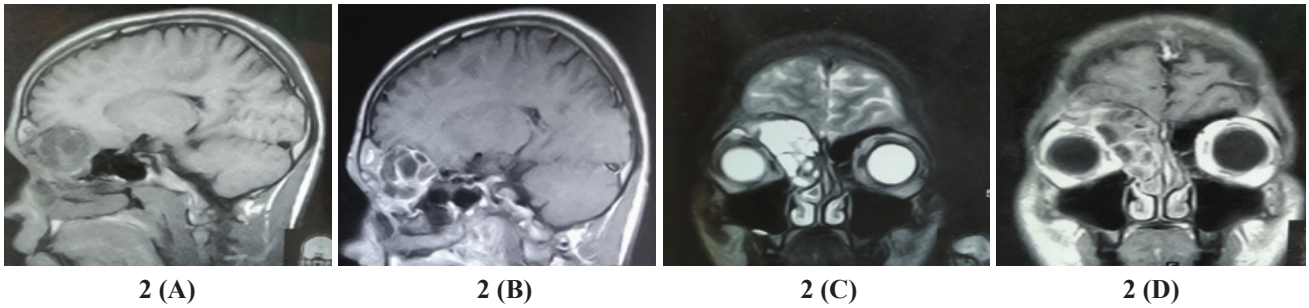


Figure 2: MRI of brain revealing heterogeneously-hyperintense, enhancing lesion in the right ethmoid and frontal sinuses (A) sagittal non-contrast (B) sagittal contrast (C) coronal T2 weighted and (D) coronal contrast sequences.

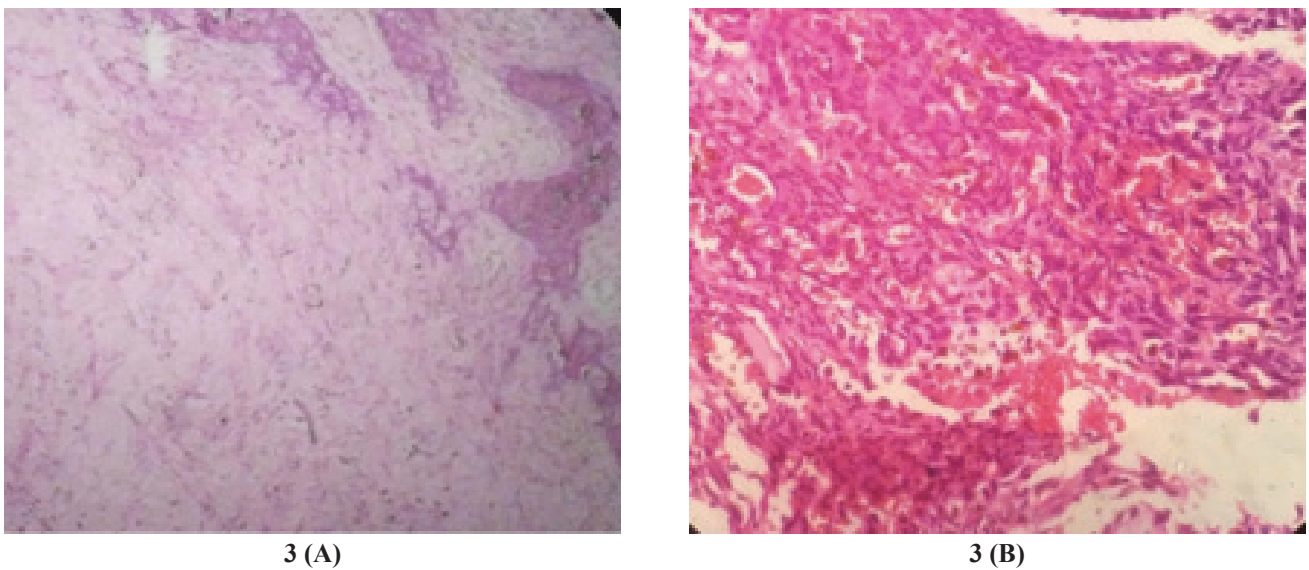


Figure 3: Histopathological specimen showing tumor tissue composed of small immature bony trabeculae, rimmed by osteoblasts with fibroblastic cells in between (A) low power and (B) high power magnification.

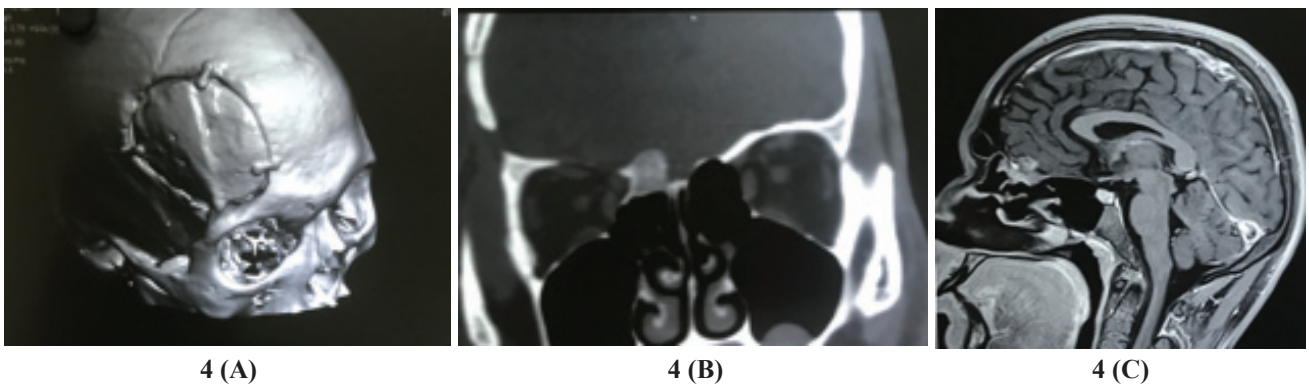


Figure 4: Postoperative neuro-images revealing small recurrence (A) CT head 3D reconstructs showing craniotomy bone flap and coronal bone reconstruct and (B) sagittal contrast MRI of brain.

### Discussion

Ossifying fibroma is an uncommon fibro-osseous tumor of benign nature with no tendency towards malignant change. It was first described by Menzel in 1872 and subsequently coined by Montgomery in 1927. Although

its etiology is unknown, odontogenic, developmental and traumatic origins have been suggested.<sup>4</sup>

It has a predilection for females (70%) between the second and fourth decades of life, with 58%, 23%, and 12% of ossifying fibromas occurring in whites, blacks, and Hispanics, respectively. Ossifying fibromas occur

predominantly in the mandible (77%), with a greater propensity for the molar regions, followed by the premolar regions. Our case was a young Asian male of second decade.

In the literature, a less common and more aggressive variant, juvenile ossifying fibroma, is discussed. It usually affects the paranasal sinuses and bones around the orbit. Frequent clinical features include proptosis or exophthalmos and nasal symptoms. This lesion may require more aggressive treatment, curette and removal of extended margins. Histopathologically, these lesions contain irregularly mineralized, cellular osteoid strands lined by plump osteoblasts. Juvenile ossifying fibromas have a reported recurrence rate between 38 - 50%. Clinically and histopathologically, our case was consistent with juvenile variant of ossifying fibroma.

Clinical presentation of these tumors is variable, depending on the site and rate of growth. It ranges from an asymptomatic bone lesion to symptoms due to mass effect of sinonasal lesions such as nasal obstruction, anosmia, hyposmia, headache or epistaxis. Ocular symptoms include visual loss, diplopia, proptosis and epiphora. Larger tumors may also lead to a painless swelling of the involved bone. While pain and paresthesia are rarely associated with an ossifying fibroma where the temporal bone is involved, the patient may complain of pain, pulsatile tinnitus, otorrhea with progressive hearing loss.<sup>5</sup> Our patient presented with nasal obstruction, diplopia, right eye proptosis and pain in the right side of the head which are consistent with the above-mentioned findings of sinonasal lesions.

Histologically, ossifying fibroma is usually well-circumscribed and expands and erodes the cortex of the involved bone. It represents a true benign neoplasm of bone with lamellar bone formation and osteoblastic rimming. Grossly an ossifying fibroma is most often grayish-white in color, dry, avascular, and either crumbly, cheesy or gritty. It has definite boundaries but is not truly encapsulated.<sup>3</sup>

Radiographic features vary from case to case basis. MRI is particularly useful for ruling out an intracranial or intraorbital extension.<sup>6</sup> In MRI, ossifying fibroma usually shows low to intermediate signal intensity on T1-weighted imaging: the signal in fibrous areas is intermediate, while that in osseous areas is hypointense. Contrast enhancement is heterogeneous and may be related to fibrous areas. On T2-weighted image, ossified areas appear with low signal while fibrous tissue exhibits a hypointense signal.<sup>7</sup>

Surgical removal of ossifying fibroma is difficult; and total resection is mandatory to avoid recurrences. These lesions are characterized by high vascularization and frequent adherence to the dura and periorbita.<sup>1</sup> Endoscopic resection of the tumor is the recommended therapeutic

approach. It holds high advantages from direct visualization of the lesion to decrease in external deformity and morbidity. Other approaches such as craniofacial (craniotomy, transfacial or transoral) ones could also be done.<sup>8</sup> In our case, the lesion was operated by multidisciplinary approach, craniotomy for resection of cranioorbital portion of the tumor combined with endoscopic approach transnasally by the ENT team for removal of nasal and ethmoidal part of the tumor and skull base reconstruction. Postoperative management must include repeated endoscopic examination and imaging specially in partially excised cases to detect recurrence and prevent long term morbidity.

## Conclusion

Our case occurring in the right ethmoidal and frontal sinus is an extremely rare juvenile variant. It is important to be aware of the clinical, imaging and histopathological features of such a rare lesion. Multidisciplinary combined ENT-Neurosurgery approach may be applied for radical resection. It seems this juvenile variant is locally more aggressive with tendency to recur in a short period even after radical surgery.

**Conflict of Interest:** None

**Source (s) of Support:** None

## References

1. Ciniglio Appiani M, Verillaud B, Bresson D, Sauvaget E, Blancal JP, Guichard JP, et al. Ossifying fibromas of the paranasal sinuses: diagnosis and management. *Acta Otorhinolaryngologica Italica* 2015; 35:355- 61. <https://doi.org/10.14639/0392-100X-533>
2. Mohsenifar Z, Nouhi S, Abbas FM, Farhadi S, Abedin B. Ossifying fibroma of the ethmoid sinus: Report of a rare case and review of literature. *Journal of Research in Medical Sciences* 2011;16:841-7. <http://www.ncbi.nlm.nih.gov/pubmed/22091316>
3. Baumann I, Zimmermann R, Dammann F, Maassen MM. Ossifying fibroma of the ethmoid involving the orbit and the skull base. *Otolaryngology-Head and Neck Surgery* 2005;133:158-9. <https://doi.org/10.1016/j.otohns.2004.09.121>
4. Charavarty S, Datta D, Boro E, Dutta B. Ossifying fibroma in the sinonasal tract: a rare case report. *Journal of clinical and diagnostic research: JCDR* 2014; 8: FD09-10. <https://doi.org/10.7860/JCDR/2014/8689.4743>
5. Lam SY, Ramli, N. M., Harikrishnan, D., Sia, S.

### Juvenile variant ossifying fibroma of sinonasal region

- F., & Pailoor, J. Ossifying fibroma of the occipital bone - a case report and literature review **European Journal of Radiology Extra** 2007;67:19-23. <https://doi.org/10.1016/j.ejrex.2008.04.021>
6. Ledderose GJ, Stelter K, Becker S, Leunig A. Paranasal ossifying fibroma: endoscopic resection or wait and scan? **European Archives of Oto-Rhino-Laryngology** 2011; 268:999-1004. <https://doi.org/10.1007/s00405-011-1503-4>
  7. Yang BT, Wang YZ, Wang XY, Wang ZC. Imaging study of ossifying fibroma with associated aneurysmal bone cyst in the paranasal sinus. **European Journal of Radiology** 2012;81:3450-5. <https://doi.org/10.1016/j.ejrad.2012.05.010>
  8. Alghonaim Y, Ala S, Arafat A. Aggressive ossifying fibroma of right ethmoidal sinus: A case report. **International Journal of Surgery Case Reports** 2018;53:513-6. <https://doi.org/10.1016/j.ijscr.2017.12.026>