

Alok Deo MS

Department of Neurosurgery

Dirghayu Guru Hospital

Kathmandu, Nepal

ORCID iD: <https://orcid.org/0000-0002-0555-3873>**Sameer Aryal MS**

Department of Neurosurgery

Dirghayu Guru Hospital

Kathmandu, Nepal

ORCID iD: <https://orcid.org/0000-0002-3863-5410>**Gopal Raman Sharma MS**

Department of Neurosurgery

Dirghayu Guru Hospital & Nepal Mediciti Hospital

Kathmandu, Nepal

ORCID iD: <https://orcid.org/0000-0003-3638-4993>**Address of correspondence:**

Dr. Alok Deo

Department of Neurosurgery

Dirghayu Guru Hospital

Kathmandu, Nepal

E-mail: dralokdeo@gmail.com

Contact number: +977 9851143048

Date of submission: 25th March 2020**Date of acceptance:** 8th April 2020DOI: <https://doi.org/10.3126/njn.v17i1.28365>**HOW TO CITE**

Deo A, Aryal S, Sharma GR. Open surgery of complex long segment (giant) glomus spinal AVM. NJNS. 2020;17(1):56-58

To access Nepal Journal of Neuroscience Archives,
scan QR code:



Open surgery of complex long segment (giant) glomus spinal arteriovenous malformation

Abstract

Spinal arteriovenous malformation occurring in the pediatric population (under 15 years) initially complain of pain as the first symptom which is often over looked. In almost all, diagnosis is delayed resulting in weakness. Angiogram provides correct diagnosis in all cases. Radical microsurgical excision tends to offer best long-term result.

Here we present a 7-year-old girl referred to us for lumbar puncture with provisional suspicion of meningitis. She had history of fever for two days and signs of meningism were present. On examination, she was stable and had complains of headache. Her previous history suggested she had continuous backache since childhood and had visited multiple centers previously for the problem. A detailed work up revealed a long segment spinal space occupying lesion. CT angiogram showed spinal arteriovenous malformation. Laminoplasty and open microsurgical excision of arteriovenous malformation was performed. Her hospital stay was uneventful and was discharged in stable condition. Early recognition, accurate diagnosis and prompt surgical treatment may result in significant improvement of neurological function.

Key words: Arteriovenous malformation, Embolization, Microsurgical excision, Spinal cord

Introduction

Spinal arteriovenous malformations (AVM) are rare vascular lesion located within the spinal canal accounting for 3-4% of all spinal cord occupying lesions and 20-30% of all spinal vascular malformations. If not treated promptly, it can lead to severe morbidity with progressive spinal cord symptoms. Presently, due to wide availability of MRA and CTA imaging, spinal vascular lesions are being more frequently detected.

Spinal arteriovenous malformation is commonly classified as Dural and Intradural AVM. Further, intradural AVM is sub classified as Glomus, Juvenile and Perimedullary arteriovenous fistula.¹ Dural arteriovenous fistula are the commonest (70% of all spinal vascular malformation)² and Glomus AVM are the rarest.

Case Report

A 7-year-old right-handed female weighing 15.5 kg presented to the Emergency Department with complaints of fever, neck stiffness and lower back pain. The pain was severe enough to hamper her daily activities. Her bowel and bladder habit were normal. On examination she had spontaneous eye opening, oriented and obeying command. Except for neck rigidity her cranial nerves examination and cerebellar sign were normal. Funduscopic examinations were also normal.

She had bilateral high arched feet with high stepping gait. Plantars were non-specific. Motor and sensory exams along with the rectal tone was normal. She was delivered via lower segment Caesarean section following full-term with no significant birth and development history.

MRI brain with screening of the whole spine (Figure 1) revealed normal brain scan with long segment spinal

space occupying lesion. CT angiogram of spine (Figure 2) showed a cluster of multiple dilated tortuous intradural extramedullary vessels in the spinal canal extending from D9 to L2, fed by anterior spinal artery, bilateral intercostal arteries and bilateral subcostal arteries. There were two draining veins at left L3-4 level. Fusiform aneurysm 3.3 cm long was noted in nidus at L1 and L2.

Laminoplasty and excision of AVM was performed. After reflection of dura three major feeders at D6, D9, L1 were clipped and two minor feeders were coagulated at L1 (Figure 3).

Her post-operative periods were uneventful. Repeat spinal angiography showed obliteration of AVM. Her bowel and bladder habit were normal and she was discharged without neurological deficit on the 14th post-operative day with thoraco-lumbar brace. At six months of follow-up patient was asymptomatic without any neurological deficit.



Figure 1a: Pre-operative MRI of whole spine (STIR sequence)

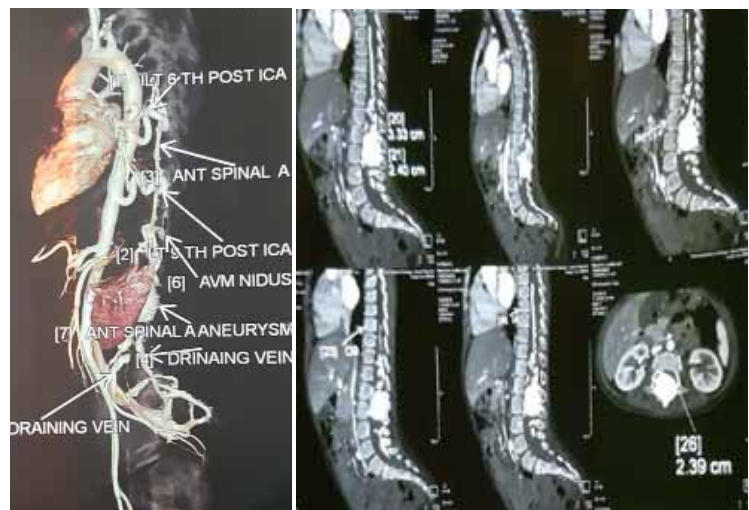


Figure 1b: Pre-operative CT Angiogram of spine: arrows show dilated tortuous intradural extramedullary vessels

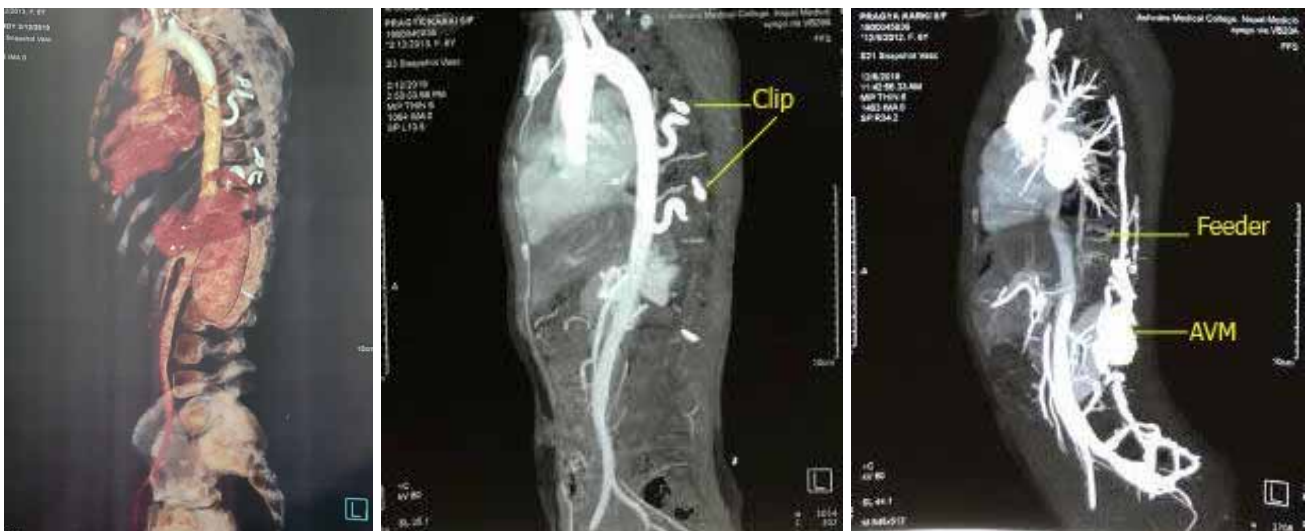

Figure 2: Post-operative CT Angiogram: vascular clips at D6, D9 and L1 level with complete obliteration of AVM and associated aneurysm

Discussion

Arteriovenous malformation (AVM) are defects in the vascular system consisting of tangles of abnormal vessels (nidus) in which the feeding arteries are directly connected to the venous network without interposition of capillary bed.

Radiographically, by location of vascular nidus two major classifications of spinal AVMs are done, Dural and Intradural. Further, intradural AVMs are sub classified into Glomus and Juvenile in which nidus lies partially or completely within spinal cord parenchyma, and direct intradural arteriovenous fistula may lie in the cord tissue or on the cord surface.

Several studies show incidence of dural AV fistula is greater than intradural AVM.³ Dural AVM are generally in older (>40 years) age group, has gradual onset of symptoms and symptoms worsen progressively whereas intradural AVMs are suspected in younger age groups (<30 years) with acute onset of symptoms and presence of subarachnoid hemorrhage or spinal bruit.

The pathophysiology of neurological deterioration may be different in patients with dural as compared to intradural AVMs. In the former group, it is due to increased venous pressure⁴ whereas the latter deteriorate due to rapid turbulent blood flow. With high flow lesion, intradural AVMs are associated with interpedicular widening, acute onset of symptoms following subarachnoid hemorrhage, spinal bruit, multiple feeding vessels and presence of aneurysm in nidus or feeding or draining vessels.⁵ Sufficient quantity of blood is diverted away from the cord due to arterial steal resulting in myelopathy.

The main objective of treatment is to interrupt the arteriovenous shunt either through invasive or non-invasive procedure without affecting normal spinal cord perfusion. Recommended treatment of spinal AVMs are surgical excision^{9,10}, glue embolization¹¹, balloon⁶ or combination of both.^{7,8} Even in the era of endovascular procedure, open surgical procedure for giant AVM is still valid in the developing countries where setup are less equipped or not available and are very expensive.

Conclusion

Early recognition, accurate diagnosis and prompt surgical treatment may result in significant improvement of neurological function.

References

1. Anson JA, Spetzler RF. Interventional neuroradiology for spinal pathology. **Clinical neurosurgery**. **1992**; 39:388-417. PMID: 1458752
2. Patsalides A, Santillan A, Knopman J, Tsiouris AJ, Riina HA, Gobin YP. Endovascular management of spinal dural arteriovenous fistulas. **J Neurointerv Surg**. **2011**; 3(1):80-4.
3. Symon L, Kuyama H, Kendall B. Dural arteriovenous malformations of the spine. Clinical features and surgical results in 55 cases. **J Neurosurg**. **1984**; 60:238-47. <https://doi.org/10.3171/jns.1984.60.2.0238>
4. Aminoff MJ, Barnard RO, Logue V. The pathophysiology of spinal vascular malformations. **J Neurol Sci**. **1974**; 23:255-63. [https://doi.org/10.1016/0022-510x\(74\)90229-9](https://doi.org/10.1016/0022-510x(74)90229-9)
5. Di Chiro G, Wener L. Angiography of the spinal cord. A review of contemporary techniques and applications. **J Neurosurg**. **1973**; 39:1-29. <https://doi.org/10.3171/jns.1973.39.1.0001>
6. Barrow DL, Colohan ART, Dawson R. Intradural perimedullary arterio-venous fistulas (type IV spinal cord arteriovenous malformations). **J Neurosurg**. **1994**; 81:221-9. <https://doi.org/10.3171/jns.1994.81.2.0221>
7. Gueguen B, Merland JJ, Riche MC, et al. Vascular malformations of the spinal cord: Intrathecal perimedullary arteriovenous fistulas fed by medullary arteries. **Neurology**. **1987**; 37:969-79. <https://doi.org/10.1212/wnl.37.6.969>
8. Halbach VV, Higashida RT, Domd CF, et al. Treatment of giant intra-dural (perimedullary) arteriovenous fistulas. **Neurosurgery**. **1993**; 33:972-80.
9. Anson JA, Spetzler RF. Classification of spinal arteriovenous malformations and implications for treatment. **Barrow Neurol Inst Q**. **1992**; 8:2-8.
10. Beargstand A, Höök O, Lidvall H. Vascular malformation of the spinal cord. **Acta Neurol Scand**. **1964**; 40:169-83. <https://doi.org/10.1111/j.1600-0404.1964.tb01142.x>
11. Arnoud O, Bille F, Pouget J, et al. Epidural arteriovenous fistula with perimedullary venous drainage: case report. **Neuroradiology**. **1994**; 36:490-1.