

**Dr. Binod Bhattarai**

College of Medical Sciences

Chitwan, Nepal

ORCID iD: <https://orcid.org/0000-0003-2036-3805>**Dr. Shashi Bhushan Sah**

College of Medical Sciences

Chitwan, Nepal

ORCID iD: <https://orcid.org/0000-0002-0026-3260>**Address for correspondence:**

Dr. Binod Bhattarai,

College of Medical Sciences

Chitwan, Nepal

E-mail: [neurobinod@gmail.com](mailto:neurobinod@gmail.com)

Contact number: +977 9855050147

**Date of submission:** 7<sup>th</sup> November 2019**Date of acceptance:** 12<sup>th</sup> December 2019DOI: <https://doi.org/10.3126/njn.v16i3.27340>**HOW TO CITE**

Bhattarai B, Shah SB. A Retrospective Observational Analysis on the Outcome of Microlumbar Discectomy among 70 Consecutive Cases in the Tertiary Care Spine Center in Nepal. *NJNS* 2019;16(3):34-39

To access Nepal Journal of Neuroscience Archives, scan QR code:



**B**ackache resulting from sciatica has been toiling us ever since we adapted to upright posturing. Its ubiquitous link with us is also evident from the fact that it has been mentioned in the paper 'Edwin Smith Surgical Papyrus' in as early as 1550 BC.<sup>1</sup>

Historical perspectives mention Hubert von Luschka, during his cadaveric studies, mistakenly assuming them to be a cartilaginous tumor. The credit for the first laminectomy with discectomy in a case of severe sciatica

## A Retrospective Observational Analysis on the Outcome of Microlumbar Discectomy among 70 Consecutive Cases in the Tertiary Care Spine Center in Nepal

Lumbar disc disease is a commonly encountered spine problem. There have been various modalities of treatment that have evolved over the years. The objective of our study is to analyze safety, efficacy, and complications following Micro-lumbar discectomy.

All the cases admitted in our spine clinic with symptomatic lumbar disc and who underwent Micro-lumbar discectomy between February 2013 to February 2018 were included in our study. Seventy cases were operated during this period. Total operative time, immediate and long term outcome with regards to pain and neurological deficits were tabulated and analyzed for each patient. Furthermore, short and long term complications including wound infection, discitis, instability and recurrence at the same level were also studied and compared with similar studies from the literature.

None of our cases had complications related to wound infection, instability or post-operative discitis. Immediate relief from the radicular pain experienced in the pre-operative period was seen in all patients (Visual analog scale) though benign tingling sensation persisted in a few of them that improved in a short span of time. Recurrence was seen in only one case.

Micro-lumbar discectomy is a minimally invasive spine procedure conferring high benefits to the patients. While compared to other methods of intervention, it has a low risk of complications as well as chances of disc recurrences.

**Key words:** Discectomy, Lumbar disc, Microlumbar, Outcome, Radiculopathy

## Outcome analysis of microlumbar discectomy

in a patient diagnosed with Cauda equina syndrome goes to Fedor Krause. However, he also wrongly interpreted it to be enchondroma. Walter E. Dandy was the first to postulate the genesis that these masses were of discal origin and that they were capable of migrating and causing sciatica following compression of the adjacent nerve roots.<sup>2</sup>

Grafton Love paved the pathway to the introduction of a microdiscectomy technique following his “key hole” laminotomy approach. Yasargil and Caspar introduced the use of an operating microscope further accrediting to its minimal invasiveness.<sup>3,4</sup>

The added advantage of better postoperative outcome owing to less tissue damage and perineural and epidural fibrosis was demonstrated in the subsequent study.<sup>5</sup> Epidural fibrosis/ perineural fibrosis is a nightmare to any managing physician and a major bane for the affected patient.<sup>6,7</sup>

The recent appraisals to the open procedure include the utilization of minimal surgical corridor and operating under high magnification loupes and headlights.<sup>8</sup>

Evolving through the trans-dural approach and then laminectomy, Microlumbar discectomy has now been considered the standard surgical practice for managing them. The rising incidence in failed back surgery syndromes might have played a pivotal role in attributing to this transition towards minimal approach thereby creating minimal instability. Indeed, most of the post-operative morbidities these patients were facing were subsequent to traumatizing surgical approaches as well as anatomical instability.

Endoscopic micro-discectomy is another valid minimally invasive alternative.<sup>9,10</sup> However, the requirement of different instrument sets and steep learning curve adds up as a major hindrance for its frequent usage on a regular basis in a global front. There are other minimally invasive methods of managing symptomatic lumbar disc diseases such as laser discectomy, thermal therapy, percutaneous discectomy, nucleoplasty, and chemonucleolysis.<sup>11-16</sup> However, contrary to other methods, application of minimal incision, reduced assess trauma to paraspinal muscles and minimal retraction of crucial neural structures in a well illuminated and magnified view has boosted for its application in the global front.

The big disadvantage of this procedure can be the inherent difficulty to retrieve and sometimes completely missing the disc out.<sup>17, 18</sup> Operating on a wrong level because of its minimal approach is also a concern especially while on high-level discs.<sup>19</sup>

We conducted this study in our tertiary spinal care center, which lies outside the capital city, and thereafter assessed the efficacy and clinical outcomes of this

procedure in the patients with symptomatic lumbar disc herniation.

## Methods and Materials

The study is a retrospective analytical descriptive study at the College of Medical Sciences, Bharatpur, Nepal. A total of 70 cases of symptomatic lumbar disc that underwent MLD in our institution from February 2013 to February 2018 were evaluated in our study. Written consent was obtained from all the patients who were included in this study. Ethical clearance was obtained from the Institutional Review Committee. All the symptomatic patients with single level lower lumbar (below L3) disc herniation not responding to medical management were included in this study.

Patients who needed laminectomy for disc removal and patients with symptomatic lumbar canal stenosis as evident by the presence of bilateral Extensor Digitorum Brevis (EDB) wasting in clinical examination and equivocal findings in radio-imaging<sup>20</sup> were excluded from the study.

Patients were verbally interviewed regarding radicular pain following full recovery from general anesthesia as per the visual analog scale (VAS)<sup>21</sup>. Following their discharges, patients were followed for a period of at least six months. The outcome indices were monitored utilizing the Prolo Functional and Economic Scale<sup>22, 23</sup>.

## Surgical steps

Following general anesthesia, the patients were placed in a prone position on a Wilson frame or pillows ensuring free abdomen and good cotton padding on pressure regions. The intraoperative level of the disc was first confirmed by C- arm images. Semicircular incision of just a thumb width with the dome facing the affected side was given. Thoracolumbar Fascia was then incised in a similar manner until the midline and retracted away with 2-0 Vicryl. This was followed by muscle dissection and peeling its attachments at the spinous process and the lamina. Subperiosteal dissection of the adjacent lamina was performed. A Muller’s Microlumbar discectomy retractor was then applied. The inferior part of the lamina was then drilled out by a diamond drill No. 2 & 3 along with Karrison rongeurs under the operating microscope. The ligamentum flavum was then separated off the lamina. The ligamentum flavum was incised with a No. 11 blade and bitten off its attachment at lamina. Limited undercutting of medial facet to ensure the bony decompression overlying the affected nerve root was performed. The nerve root was visualized and minimally retracted. An extruded disc fragment was then removed. The sequestered disc fragment was also removed. Steroid (80 mg Methylprednisolone) was irrigated over the dura

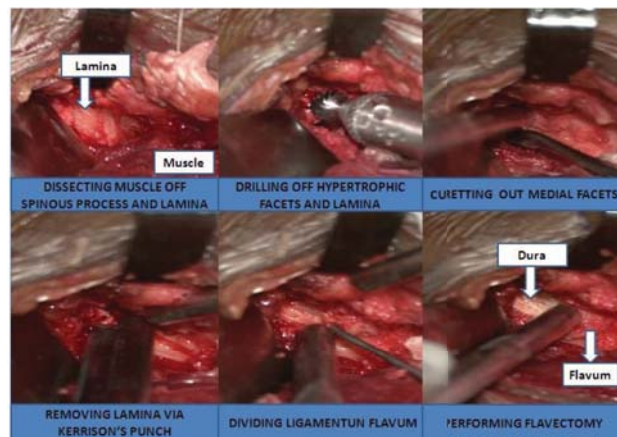


Figure 1. Surgical steps demonstrating exposure for micro lumbar discectomy

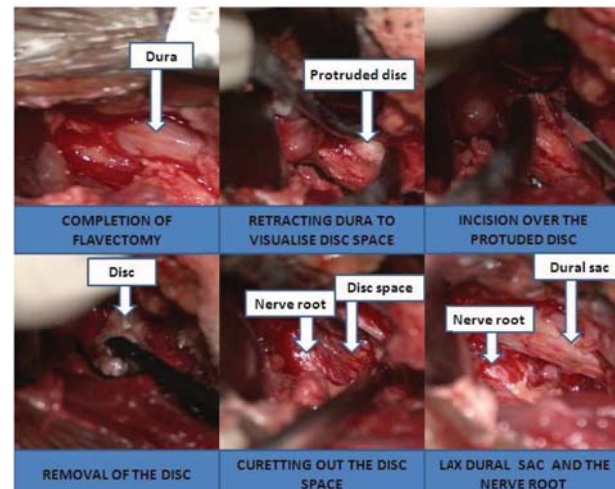


Figure 2. Surgical steps demonstrating removal of extruded disc material

and nerve root prior to the closure, without placement of any drain.

Intra-operative blood loss was estimated using the same principle as mentioned in gauze visual analog method.<sup>24</sup>

The surgical steps have been summarized in Figure 1 and Figure 2.

### Results

A total of 70 cases were included in our study comprising of 44 males and 26 females. Their ages ranged from 17-78 years with a mean age of 39. In 42 cases, they had L4-5 disc, 27 cases had L5-S1 disc and 1 case had L3-4 disc. Radicular pain involving the L5 dermatome was the most common initial presentation. All these cases were investigated with an MRI of the lumbo-sacral spine. There were 47 cases of extruded discs and 23 contained discs. Median operative time was averaging 50 minutes. The estimated blood loss (visual inspection of the soaked gauze pieces) was around 10 ml.

All patients, except 4, experienced immediate relief from their radicular symptoms following the procedure. There were no inadvertent clinical deficits observed. The patients were immediately mobilized. Most of them were discharged on the second day of surgery. First, follow up was done in the second week and then every month for the next 6 months. The clinical assessments were performed utilizing the Prolo Functional and Economic Scale. 57 patients were completely asymptomatic and back to their normal activities at six months.

We had two inadvertent intra-operative dural tears. Minor wound infection occurred in 4 cases which healed with dressing and course of antibiotics. Vague discomfort

at the back was seen in 5 cases but it didn't limit their activities of daily life. Recurrent same level disc herniation occurred in two patients within 3 weeks of index surgery. One though symptomatic, denied undergoing repeat surgery and also lost to subsequent follow-up. Another one was re-operated and subsequently improved.

Prolo functional and economic rating scale	Grade 1	Grade 2	Grade 3	Grade 4	Grade 5
	0	0	3	10	57
	0%	0%	4.3%	14.3%	81.4%

Table 1: Prolo Functional and Economic Rating Scale Status

### Discussion

Lumbar disc disease accounts for major subsets of authorized leave from work.<sup>25</sup> Also, it accounts for the longest sick leave for doctor prescribed sick leaves.<sup>26</sup> The advantage of surgery in patients with persistent symptomatic pain is that it provides instant relief from the radicular pain.<sup>28</sup> Therefore, it is one of the commonest spinal interventions to be undertaken.<sup>29,30</sup> Long term results of most of the procedures chosen for the management of the disc is almost equivocal with all of them having excellent results in roughly 80% of the cases.<sup>31</sup> Micro and open lumbar discectomy both are gold standard therapeutic options.<sup>32,33</sup> Almost all of the recent studies have shown favorable results for discectomy in adolescent patients.

There is some prevailing debate regarding the role of fusion following radical discectomy. Dewing reported good

surgical outcomes in young and active patients without arthrodesis.<sup>34</sup> Most of them returned to unrestricted active military duty having high satisfaction with their outcome.

Another burning issue is the aggressive curettage Vs sequestrectomy alone in managing them.<sup>36, 37, 38</sup> Fragmentectomy alone had 11.1% recurrence rate at an average 87 months of follow up in one study.<sup>38, 39</sup>

Both groups resulted in equivocal clinical improvement as per the visual analog scale (VAS) score in terms of radicular symptoms. Reherniation in the microdiscectomy group was reported among 2.3% to 11.8% patients whereas seen in 2% to 12.5% cases in sequestrectomy groups.<sup>40</sup> Some authors even advised for Annular repair in preventing a recurrence.<sup>41</sup> The major disadvantage of the aggressive approach is the higher incidence of subsequent Modic changes in the adjacent levels.<sup>42</sup> Sequestrectomy alone approach is now a standard procedure.<sup>43, 44, 45</sup> There is a higher overall satisfaction but the added risk high recurrence persists (18% vs. 9%).<sup>46</sup> The removal of only extruded disc fragments showed a recurrence rate of 5.5 to 9%.<sup>47, 48</sup> The more aggressive discectomy with curettage of the disc space to remove the entire disc material also had a comparable recurrence of 3%.<sup>49</sup> Paradoxically, there was a high incidence of discitis and postoperative persisting backache. In our study, we had a recurrence rate of only 2%. The recurrence of radicular symptoms due to reherniation can occur in up to 30% of patients.<sup>50, 51</sup> Disc space subsidence after aggressive discectomy can confer significant axial loading on the stressed facet joints producing persistent pain.<sup>52, 53</sup> Sequestrectomy alone thereby decreases the incidence of failed back syndrome.<sup>54</sup>

Pain relief is another main concern any surgeries with persistent pain. Immediate pain relief was seen in 98.33% in Devkota et al series, 97.5% in PS Ramani series, 96% in Yash Gulati series and 90% in CJ Koebbe et al series.<sup>55, 56, 57, 58</sup> In this study immediate radicular pain relief was seen in 96% of cases comparable to other studies.

There are some limitations to this procedure. The most common risk is that of incidental durotomy.<sup>59</sup> There is the integral need of an operating microscope along with the facility for intra-operative C-arm images which may be major issues in resource-deprived circumstances.<sup>59</sup> The issues of radiation hazards and the learning curve for the procedure are other prevailing issues.

### Conclusions

Microlumbar discectomy is a safe and efficient procedure in managing symptomatic lumbar disc disease. It is minimally invasive, less time consuming and devoid of major complications. It has evolved to become the gold standard method for managing symptomatic lumbar disc.

### References

1. Breasted JH. Edwin Smith Surgical Papyrus, in Facsimile and Hieroglyphic Transliteration and with Translation and Commentary. Chicago: University of Chicago Oriental Publications; 1930.
2. Dandy WE. Loose Cartilage from the Intervertebral Disc Stimulating Tumor of the Spinal Cord. **Arch Surg.**1918;68:5-11.
3. Yasargil MG. Microsurgical discectomy: a conservative surgical approach to the Virgin herniated lumbar disc. **Adv Neurosurg.** 1977;4:81. DOI: 10.1007/978-3-642-66578-3\_16
4. Caspar W. A new surgical procedure for lumbar disc herniation causing less tissue damage through a microsurgical approach. **Adv Neurosurg.** 1977;4:74-80. DOI: 10.1007/978-3-642-66578-3\_15
5. Williams RW. Micro-lumbar discectomy: a conservative surgical approach to the Virgin herniated lumbar disc. **Spine.** 1978;3:175-82. DOI: 10.1097/00007632-197806000-00015
6. Ross JS, Robertson JT, et al. Association between peridural scar and recurrent radicular pain after lumbar discectomy: magnetic resonance evaluation. **Neurosurgery.** 1996;38:855-63. DOI: 10.1227/00006123-199604000-00053
7. Fritsch EW, Heisel J, Rupp S. The failed back surgical syndrome. Reasons, intraoperative findings, and long-term results: a report of 182 operative treatments. **Spine.** 1996; 21:626-63. DOI: 10.1097/00007632-199603010-00017
8. Spengler DM. Lumbar discectomy. Results with limited disc excision and selective foraminotomy. **Spine.** 1982;7:604-7. DOI: 10.1097/00007632-198211000-00015
9. Foley KT, Smith MM. Microendoscopic discectomy. **Techn Neurosurg.** 1997;3:301-7.
10. Hussein M, Abdeldayem A, Mattar MM. Surgical technique and effectiveness of microendoscopic discectomy for large uncontained lumbar disc herniations: a prospective, randomized, controlled study with 8 years of follow-up. **Eur Spine J.** 2014;23:1992-9. DOI: 10.1007/s00586-014-3296-9
11. Choy DS, Case RB, Fielding W, Hughes J, Liebler W, Ascher P. Percutaneous laser nucleolysis of lumbar disc. **N Engl J Med.** 1987;317:771-2. DOI: 10.1056/NEJM198709173171217
12. Saal JS, Saal JA. Management of chronic discogenic low back pain with a thermal intradiscal catheter: A preliminary study. **Spine.** 2000;25:382-8. DOI: 10.1097/00007632-200002010-00021

13. Onik G, Helms CA, Ginsberg L, Hoaglund FT, Morris J. Percutaneous lumbar discectomy using a new aspiration probe. **AJNR Am J Neuroradiol.** **1985;6:**290-3. DOI: 10.1097/00004424-198509000-00097
14. Smith L. Enzyme dissolution of the nucleus pulposus in humans. **JAMA.** **1964;187:**137-40. DOI: 10.1001/jama.1964.03060150061016
15. Choy DS, Case RB, Fielding W, Hughes J, Liebler W, Ascher P. Percutaneous laser nucleolysis of lumbar disc. **N Engl J Med.** **1987;317:**771-2. DOI: 10.1056/NEJM198709173171217
16. Schreiber A, Suezawa Y. Transdiscoscopic percutaneous nucleotomy in disc herniation. **Orthop Rev.** **1986;15:**35-8.
17. Schmidek HH, Sweet WH: Operative neurosurgical techniques. 1st ed., Grune and Stratton, New York, 1982.
18. Fager CA. Lumbar discectomies; a contrary opinion. **Clin Neurosurg.** **1986;33:**419-56.
19. Hsiang J. Wrong-level surgery: A unique problem in spine surgery. **Surgical Neurology International.** **2011;2:**47. DOI: 10.4103/2152-7806.79769.
20. Munakomi S, Kumar B. Wasting of Extensor Digitorum Brevis as a Decisive Preoperative Clinical Indicator of Lumbar Canal Stenosis: A Single-center Prospective Cohort Study. **Annals of Medical and Health Sciences Research.** **2016;6(5):**296-300. DOI: 10.4103/amhsr.amhsr\_392\_15
21. Baek GS, Kim YS, Lee MC, Song JW, Kim SK, Kim IH. Fragmentectomy versus Conventional Microdiscectomy in Single-Level Lumbar Disc Herniations : Comparison of Clinical Results and Recurrence Rates. **J Korean Neurosurg Soc.** **2012 Sep; 52(3):**210-4. DOI: 10.3340/jkns.2012.52.3.210
22. Barth M, Weiss C, Thomé C. Two-year outcome after lumbar microdiscectomy versus microscopic sequestrectomy: part 1: evaluation of clinical outcome. **Spine.** **2008 Feb; 33(3):**265-72. DOI: 10.1097/BRS.0b013e318162018c
23. Thomé C, Börm W, Meyer F. Degenerative lumbar spinal stenosis: current strategies in diagnosis and treatment. **Dtsch Arztebl Int.** **2008 May; 105(20):**373-9.
24. Ali Algadiem E, Aleisa AA, Alsubaie HI, Buhlaiqah NR, Algadeeb JB, Alsneini HA. Blood Loss Estimation Using Gauze Visual Analogue. **Trauma Monthly.** **2016;21(2):**e34131. DOI: 10.5812/traumamon.34131
25. Cypress BK. Characteristics of physician visits for back symptoms: A National Perspective. **Am J Public Health.** **1983;73:**389-95. DOI: 10.2105/AJPH.73.4.389
26. Hubertsson J, Englund M, Hallgärde U, Lidwall U, Löfvendahl S, Petersson IF. Sick leave patterns in common musculoskeletal disorders - a study of doctor prescribed sick leave. **BMC Musculoskeletal Disorders.** **2014;15:**176. DOI: 10.1186/1471-2474-15-176
27. Guo HR, Tanaka S, Halperin WE, Cameron LL. Back pain prevalence in US industry and estimates of lost workdays. **American Journal of Public Health.** **1999;89(7):**1029-35. DOI: 10.2105/AJPH.89.7.1029
28. Henrik Weber. Lumbar Disc Herniation: A controlled, Prospective Study with Ten Years of Observation. **Spine.** **1983;8(2):**131-40. DOI: 10.1097/00007632-198303000-00003
29. Gray DT, Deyo RA, Kreuter W, Mirza SK, Heagerty PJ, et al. Population-based trends in volumes and rates of ambulatory lumbar spine surgery. **Spine.** **1976;31:**1957-63. DOI: 10.1097/01.brs.0000229148.63418.c1
30. Maroon JC. Current concepts in minimally invasive discectomy. **Neurosurgery.** **2002;51:**S137-45. DOI: 10.1097/00006123-200211002-00019
31. Dohrmann GJ, Mansour N. Long-Term Results of Various Operations for Lumbar Disc Herniation: Analysis of over 39,000 Patients. **Med Princ Pract.** **2015;24:**285-90. DOI: 10.1159/000375499
32. McCulloch JA. That issue on lumbar disc herniations: macro-and microdiscectomy. **Spine.** **1996;21:**45S-56S. DOI: 10.1097/00007632-199612151-00005
33. Gibson JN, Waddell G. Surgical interventions for lumbar disc prolapse: update Cochrane review. **Spine.** **2007; 32:**1735-47. DOI: 10.1097/BRS.0b013e3180bc2431
34. Dewing CB, Provencher MT, Riffenburgh RH, Kerr S, Manos RE. The outcomes of lumbar microdiscectomy in a young, active population: correlation by herniation type and level. **Spine.** **2008;33:**33-8. DOI: 10.1097/BRS.0b013e31815e3a42
35. O'Connell JE. Protrusions of the lumbar intervertebral discs, a clinical review based on five hundred cases treated by excision of the protrusion. **J Bone Joint Surg Br.** **1951;33-B:**8-30. DOI: 10.1302/0301-620X.33B1.8
36. Williams RW. Microlumbar Discectomy: A Conservative Surgical Approach To The Virgin Herniated Lumbar Disc. **Spine.** **1978;3:**175-82. DOI: 10.1097/00007632-197806000-00015
37. Soliman J, Harvey A, Howes G, Seibly J, Dossey J, Nardone E. Limited microdiscectomy for lumbar

### Outcome analysis of microlumbar discectomy

- disc herniation: a retrospective long-term outcome analysis. **J Spinal Disord Tech.** **2014**;**27**:E8-E13. DOI: 10.1097/BSD.0b013e31828da8f1
38. Spengler DM. Lumbar discectomy: Results with limited disc excision and selective foraminotomy. **Spine.** **1982**;**7**:604-7. DOI: 10.1097/00007632-198211000-00015
39. Ran J, Hu Y, Zheng Z, Zhu T, Zheng H, Jing Y, et al. Comparison of Discectomy versus Sequestrectomy in Lumbar Disc Herniation: A Meta-Analysis of Comparative Studies. **PLoS One.** **2015**;**10**(3):e0121816. DOI: 10.1371/journal.pone.0121816
40. Fakouri B, Shetty NR, White TCH. Is Sequestrectomy a Viable Alternative to Microdiscectomy? A Systematic Review of the Literature. **Clinical Orthopaedics and Related Research.** **2015**;**473**(6):1957-62. DOI: 10.1007/s11999-014-3904-3
41. Bailey A, Araghi A, Blumenthal S, Huffmon GV. Prospective, multicenter, randomized, controlled study of annular repair in lumbar discectomy: two-year follow-up. **Spine.** **2015**;**38**: 1161-9. DOI: 10.1097/BRS.0b013e31828b2e2f
42. Barth M, Diepers M, Weiss C, Thome C. Two-year outcome after lumbar microdiscectomy versus microscopic sequestrectomy: part 2: radiographic evaluation and correlation with clinical outcome. **Spine.** **2008**;**33**:273-9. DOI: 10.1097/BRS.0b013e31816201a6
43. Spengler DM, Ouellette EA, Battié M, Zeh J. Elective discectomy for herniation of a lumbar disc: Additional experience with an objective method. **J Bone Joint Surg Am.** **1990 Feb**; **72**(2):230-7. DOI: 10.2106/00004623-199072020-00010
44. Williams RW. Microlumbar discectomy: a conservative surgical approach to the virgin herniated lumbar disc. **Spine.** **1978 Jun**;**3**(2):175-82. DOI: 10.1097/00007632-197806000-00015
45. Yasargil MG. Microsurgical operation of herniated lumbar disc. **Adv Neurosurg.** **1977**;**4**:81. DOI: 10.1007/978-3-642-66578-3\_16
46. Carragee EJ, Spinnickie AO, Alamin TF, Paragioudakis S. A prospective controlled study of limited versus subtotal posterior discectomy: short-term outcomes in patients with herniated lumbar intervertebral discs and large posterior anular defect. **Spine.** **2006 Mar**;**31**(6):653-7. DOI: 10.1097/01.brs.0000203714.76250.68
47. Williams RW. Microlumbar discectomy. A conservative surgical approach to the virgin herniated lumbar disc. **Spine.** **1978**;**3**(2): 175-82. DOI: 10.1097/00007632-197806000-00015
48. Williams RW. Microlumbar discectomy - A 12-year statistical review. **Spine.** **1986**;**11**(8): 851-2. DOI: 10.1097/00007632-198610000-00023
49. Wilson DH, Harbaugh R. Lumbar discectomy: a comparative study of microsurgical and standard technique. **Lumbar disc disease.** **1982**:147-56
50. Connolly ES. Surgery for recurrent lumbar disc herniation. **Clin Neurosurg.** **1992**;**39**:211-6.
51. Eismont FJ, Currier B. Surgical management of lumbar intervertebral-disc disease. **J Bone Joint Surg Am.** **1989**;**71**:1266-71. DOI: 10.2106/00004623-198971080-00024
52. Kirkaldy-Willis WH, Wedge JH, Yong-Hing K, Reilly J. Pathology and pathogenesis of lumbar spondylosis and stenosis. **Spine.** **1978**;**3**:319-28. DOI: 10.1097/00007632-197812000-00004
53. Mochida J, Nishimura K, Nomura T, Toh E, Chiba M. The importance of preserving disc structure in surgical approaches to lumbar disc herniation. **Spine.** **1996**;**21**:1556-63. DOI: 10.1097/00007632-199607010-00014
54. Jaikumar S, Kim DH, Kam AC. History of minimally invasive spine surgery. **Neurosurgery.** **2002 Nov**;**51**(5 Suppl):S1-14. DOI: 10.1097/00006123-200211002-00003
55. Devkota UP, Lohani S, Joshi RM. Minimally invasive open lumbar discectomy: An alternative to microlumbar discectomy. **Kathmandu Univ Med J (KUMJ).** **2009 Jul-Sep**;**7**(27):204-8. DOI: 10.3126/kumj.v7i3.2724
56. Ramani PS, Chagla AS: Microlumbar discectomy 'state of art' treatment for prolapsed lumbar intervertebral disc. **Neurology India.** **44**:102-7.
57. Yash Gulati. Lumbar microdiscectomy. **Apollo Medicine.** **2004 Sep**;**1**. DOI: 10.1016/S0976-0016(12)60037-4
58. Koebbe CJ, Maroon JC, Abla A, El-Kadi H, Bost J. Lumbar microdiscectomy: A historical perspective and current technical considerations. **Neurosurg Focus.** **2002**;**13**:E3. DOI: 10.3171/foc.2002.13.2.4
59. Dasenbrock HH, Juraschek SP, Schultz LR, et al. The efficacy of minimally invasive discectomy compared with open discectomy: a meta-analysis of prospective randomized controlled trials. **Journal of neurosurgery Spine.** **2012**;**16**(5):452-62. DOI: 10.3171/2012.1.SPINE11404