

**Dr. Shailesh Maharjan MS**

Lecturer, Department of Surgery  
Nepal Medical College  
Attarkhel, Jorpati, Nepal  
ORCID iD: <https://orcid.org/0000-0002-3669-0790>

**Dr. Amit Thapa MS, MCh, IFAANS**

Professor, Department of Neurological Surgery  
Kathmandu Medical College Teaching Hospital  
(KMCTH)  
Sinamangal, Kathmandu, Nepal  
ORCID iD: <https://orcid.org/0000-0003-1896-3115>

**Dr. Bikram Shakya MS, MCh**

Department of Neurological Surgery  
Kathmandu Medical College Teaching Hospital  
(KMCTH)  
Sinamangal, Kathmandu, Nepal  
ORCID iD: <https://orcid.org/0000-0002-9338-0510>

**Dr. Bidur KC MS, MCh**

Associate Professor  
Department of Neurological Surgery  
Kathmandu Medical College Teaching Hospital  
(KMCTH)  
Sinamangal, Kathmandu, Nepal  
ORCID iD: <https://orcid.org/0000-0003-3691-8764>

**Address for correspondence:**

Dr. Shailesh Maharjan MS  
Lecturer, Department of Surgery  
Nepal Medical College  
Attarkhel, Jorpati, Nepal  
ORCID iD: <https://orcid.org/0000-0002-3669-0790>

**Date of submission:** 3<sup>rd</sup> November 2019

**Date of acceptance:** 12<sup>th</sup> December 2019

DOI: <https://doi.org/10.3126/njn.v16i3.27337>

**HOW TO CITE**

Maharjan S, Thapa A, Shakya B, KC B. Is Pre-operative Clipping of Scalp Hair Necessary for Craniotomies?. NJNS 2019;16(3):15-21

To access Nepal Journal of Neuroscience Archives, scan QR code:



## Is Pre-operative Clipping of Scalp Hair Necessary for Craniotomies?

Pre-operative clipping of scalp hair has been practiced before craniotomies to decrease surgical site infections. In developing countries like ours, due to poor hygiene this may look genuine. However, with regular pre-operative part preparation practices we have tried avoiding clipping of hair in routine craniotomies.

This study retrospectively studied patients undergoing craniotomies during the last four years at Kathmandu Medical College Teaching Hospital and compared two groups of patients; pre-operative part preparation practices group who did not have pre-operative hair clipped and the other group who had pre-operative hair clipped. Only patients who could be studied for over two weeks were included in the study. Patients with pre-existing scalp injuries were excluded. Endpoints studied were post-operative surgical site infections and need for debridement and re-suturing.

Of the total 726 patients studied, 246 underwent craniotomies with pre-operative part preparation practices and 480 had their hair clipped. Of the pre-operative part preparation practices group, three had surgical site infection as compared to eight who had their hair clipped ( $p=0.641$ ). The infection led to debridement and re-suturing in two patients of pre-operative part preparation practices and four in hair clipped group ( $p=0.946$ ). These two groups were comparable for age ( $p=0.210$ ), however, there was statistically significant differences in gender ( $p=0.001$ ), type of lesion ( $p=0.000$ ), pneumocephalus ( $p=0.000$ ), skull base fracture ( $p=0.000$ ) and use of peri-operative antibiotics ( $p=0.000$ ). However, all the above mentioned significant parameters did not have any statistical significant relation with surgical site infection {gender ( $p=0.255$ ), type of lesion ( $p=0.264$ ),

Despite modern surgical advances, surgical site infections (SSI) has remained one of the unrelenting problems for both the patients and surgeons<sup>1</sup>. Shaving or clipping of entire scalp hair has been conventionally practiced by most of the neurosurgeons in an attempt to reduce the complications of infections, better exposure and ease of bandage application<sup>2</sup>. Although this may seem to be logical in developing countries like Nepal, where personal hygiene is very poor, there is no convincing evidence in literature that it actually helps to achieve these goals<sup>3</sup>.

This practice of shaving entire scalp hair is often being challenged by many contemporary surgeons in recent times. Some researchers have actually documented the reduced rates of SSIs in patients whose scalp hair is preserved<sup>4</sup>. Shaving the head changes the normal flora in the wound area, removes the natural protective effects that hair offers, all of which increases the risk of infections<sup>5</sup>. Various studies have confirmed that shaving with razors cause microscopic cuts to skin which creates a portal for pathogens and predispose to post-operative wound infection<sup>6</sup>. Although clippers cut hair close to the patient's skin, they can still cause micro abrasions and increase the risk of surgical site infection. The use of depilatories, as an alternate, has had reported significant side effects. Besides the cosmetic effects of bald scalp is distasteful for most of the patients<sup>7</sup>. Many patients find it embarrassing to return to society with bald scalp and naturally prefer to keep their scalp full of hair to enhance self-image during the post-operative period<sup>8</sup>.

At our centre, we have adopted a regular pre-operative part preparation practices (PPP) in elective cases to clean the parts before surgery avoiding the need of hair shaving. This study aims to compare the surgical site infection rate among the craniotomy patients with preservation of scalp hair and with conventional practice of preoperative clipping of hair.

pneumocephalus ( $p=0.787$ ), skull base fracture ( $p=0.584$ ) and use of peri-operative antibiotics ( $p=0.100$ ).

Pre-operative clipping of hair does not avoid surgical site infections. Protocol based part preparation practices of scalp and post-operative head hygiene are important to avoid the surgical site infections.

**Key words:** Craniotomy, Pre-operative hair clipping, Surgical site infection

### Methods and Materials

The retrospective study involved 726 patients who underwent craniotomies during a period of four years (1<sup>st</sup> January 2015 to 31<sup>st</sup> December 2018) at Kathmandu Medical College Teaching Hospital (KMCTH), Sinamangal, Kathmandu. The patients were divided into two groups: 1) the Hair clipped (HC) group and 2) the Pre-operative part preparation (PPP) group. The HC group consisted of emergency craniotomy patients who had their entire scalp hair clipped for the surgery and the PPP group consisted of consenting patients who underwent elective craniotomy with their scalp hair preserved during the surgery. The reason behind this selection was the lack of time during emergency surgeries to prepare the parts.

In the PPP group, all patients were instructed to wash their scalp hair with chlorhexidine shampoo a day before and on the day of surgery (Figure 1).

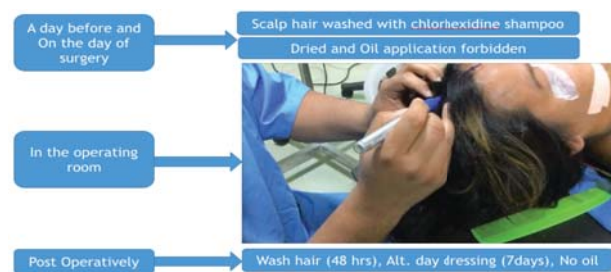

Figure 1: Preoperative Part Preparation (PPP) method

In the operating room, after planning and marking the incision, the scalp hair was partitioned with regular comb and fixed away from the marked site with sterile rubber bands in multiple clumps. Minimal clipping of hair was done with electric hair clipper at the intended incision site only and a water soluble jelly was used to prevent the hair from falling to the incision site. The area was then painted with 10% povidone iodine (Betadine®) solution and

### Is pre-operative scalp hair clipping necessary?

covered with a gauze piece soaked in betadine® solution. Sterile draping was done to expose only the incision site; first with linen drape and finally with a commercial drape (Video 1: <https://youtu.be/Y36co1aEMIE> ). The incisions were made and the edges of the incision were secured in such a way that the hair could not fall into the surgical site. At the end of the surgery, the incision was closed in two layers; galea with absorbable polyglycolic acid (Vicryl) suture in continuous manner and skin with staples after ensuring no hair was trapped in the incision site. Subcutaneous drain was often placed at the time of closure which was removed after 48 hours.

In the HC group, entire scalp hair was clipped with an electric hair clipper before marking the incision site. Painting, draping and incision closure were done in the same manner as PPP group. Intravenous injection of Cefazolin 1 gram was given in all cases prior to incision and prophylactic antibiotic was continued post-operatively only in patients with skull base fracture and pneumocephalus. Post-operatively alternate day dressings were done in both groups and staples were removed on the 10<sup>th</sup> post-operative day.

Patients with pre-existing scalp injuries, burr hole craniotomies, cranioplasties and VP shunt operations were excluded from the study. All the patients were followed up for at least two weeks for the study. End points of the study was the presence of infection which was indicated by the presence of at least one of the following; pus, pain,

tenderness, swelling, redness or a positive culture from a swab of the discharges<sup>9</sup>.

The data was recorded in a standard performa (Figure 2). Statistical analyses were performed with the help of Statistical Package for the Social Sciences (version 21, SPSS Inc., IBM, Chicago, IL, USA). The differences between the cohorts were analyzed in a univariate manner: continuous variables were tested using the Student's t-test for normally distributed data and the Mann–Whitney U-test for non-normally distributed data. Associations between categorical variables were analyzed using the Chi-square test ( $\chi^2$  test) or Fisher's exact test, as appropriate. The predictors of SSI were evaluated using multivariate binary logistic regression analysis. Variables were expressed as mean  $\pm$  standard deviation or percentage of patients, as appropriate. Differences with a p-value of 0.05 or less were regarded as statistically significant.

### Results

A total of 726 patients were enrolled in this study who underwent craniotomies at our centre. 246 underwent craniotomies with PPP and 480 had their hair clipped (HC). Male predominance (61.9%) was noted in both HC group (131 versus 115) and PPP group (319 versus 161). The mean age of the patients was  $40.9 \pm 21$  years (3 months to 89 years). Skull base fracture and pneumocephalus were observed in 19 (2.6%) and 51(7%) patients respectively

S.N	Characteristics	Hair Preserved (PPP) (N=246)	Hair Clipped (HC) (N=480)	p -value	
1	Mean Age (n=726)	42.367 $\pm$ 20.68	40.298 $\pm$ 21.217	0.210	
2	Sex	Male (n=450)	131	319	0.001
		Female (n=276)	115	161	
3	Type of Lesion	Tumor	130	14	0.000
		Vascular	66	140	
		Infective	9	6	
		Congenital	10	0	
		Trauma	31	320	
4	Pneumocephalus (n=51)	2	49	0.000	
5	Skull base fracture (n=19)	1	18	0.000	
6	Peri-operative antibiotics (n=66)	3	63	0.000	

Table 1: Characteristics of Cohorts

while 66 (9.1%) patients had received peri-operative antibiotics. Most of the craniotomies were performed for trauma (48.35%) followed by vascular lesions (28.37%).

Both HC and PPP groups were comparable for age (p=0.210), however male were more in proportion in HC group (p=0.001), with tumour being predominant pathology among PPP group as compared to trauma in HC group (p=0.000). Besides pneumocephalus, skull base fracture and use of peri-operative antibiotics (ceftriaxone) was statistically more in HC group (p=0.000, 0.000 & 0.000 consecutively) (Table 1).

**Surgical Site Infections (SSI)**

There were a total of 11 (1.5%) post-operative SSIs, of which three (1.2%) were from the PPP group and eight (1.7%) from the HC group (p= 0.641). Five of them were males and six were females. 72.73% of the SSIs were observed in patients with trauma.

To evaluate the effects of factors like gender, type of lesion, pneumocephalus, skull base fracture and use of peri-operative antibiotics which were significantly different between the two groups, association with SSI was analysed using multivariate binary logistic regression analysis. However, all the above mentioned parameters did not have any statistical significant relation with SSI (p=0.255, 0.264, 0.787, 0.584 and 0.100 respectively) (Table 2).

The infection led to debridement and re-suturing in two patients of PPP and four in HC group (p=0.946) (Table 3).

The common organisms isolated in SSIs were staphylococcus aureus followed by Klebsiella pneumonia, streptococcus pyogenes and enterococcus species (Figure 2).

S.N.	Characteristics		SSI	p-value
1	Male		5	0.255
	Female		6	
2	Pneumocephalus (n=51)	Present	1	0.787
		Absent	10	
3	Skull Base Fracture (n=19)	Present	0	0.584
		Absent	11	
4	Perioperative Antibiotics (n=66)	Used	1	0.100
		Not used	10	
5	Type of Lesion	Tumor	3	0.264
		Vascular	0	
		Infective	0	
		Congenital	0	
		Trauma	8	

Table 2: Patients characteristics of SSI (n=11)

SN	Characteristics	Hair Clipped (HC) (n=480)	Hair Preserved (PPP) (n=246)	
1	Surgical Site Infections (SSI)	8 (1.67%)	3 (1.22%)	0.641
2	Surgical management	4	2	0.946

Table 3: Management of SSIs (n=11)

### Is pre-operative scalp hair clipping necessary?

respectively<sup>13</sup>. In a retrospective article of Hwang et al with 93 patients, none of the patients undergoing head surgeries had wound infection<sup>14</sup>(Table 4).

Due to poor personal hygiene and difficulty in maintaining cleanliness in the post-operative period, shaving of hair had been a standard practice in Nepal. In our study, the infection rate in neurosurgical patients was 1.52% which was comparable to a Japanese study by Tokimura et al but slightly higher than the attainable standard (1% or less)<sup>12,15</sup>. At our centre, HC and PPP group had SSI rate of 1.67% and 1.22% respectively which showed no statistical advantage of pre-operative hair clipping over hair preservation to prevent SSIs. Similar non superiority of hair clipping to prevent infections have been reported by Tokimura et al. and Ratanalert S et al. in their studies<sup>12,13</sup>. Even the Cochrane review, which included thirteen randomised controlled trials, was unable to demonstrate any benefit of removing hair before cranial surgeries<sup>16</sup>.

In some circumstances, lack of hair may enhance psychological trauma and delay in rehabilitation, especially in female patients<sup>17</sup>. Patients perceive bald bandaged scalp as a marker of bad state of health and the sight of which is cosmetically agonising<sup>18</sup>. The patients react very positively and feel better when they have a psychological benefit of undisturbed body image while looking themselves into the mirror with their hair and the scar hidden inside. The positive morale help the patients to resume their normal daily activities and previous occupations. However, scalp hair has to be prepared cautiously before the surgery and the patients are encouraged to get bath after the surgery. Dressing, particularly in children is clumsier if done in soiled hair. Hence, hair needs to be washed and dried before wound-dressing.

Though the parameters which were found to be significantly different between the two groups were not

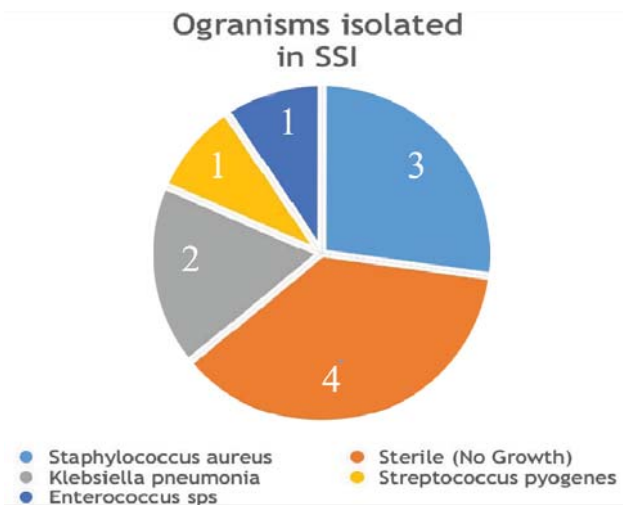


Figure 2: Organisms Isolated in SSI

### Discussion

Shaving scalp hair has been considered an important ritual in surgical texts not only to avoid wound infections but also to provide good exposure during surgery. In 1992, KR Winston published a pioneering article reporting that removal of hair does not lower the risk of surgical wound infection but may increase the risk. In his report of 312 cranial procedures, he showed a SSI rate to be only 0.3% in patients whose scalp hair was preserved<sup>10</sup>. Taha MM et al reported SSI rate of 3.47% in their two years prospective study with 1181 neurosurgical patients at their centre in Egypt. They found Staphylococcus aureus as the commonest organism to cause SSI<sup>11</sup>. A study in Japan by Tokimura et al reported SSI rate of 1.1% in patients with hair preserved<sup>12</sup>. Ratanalert S et al reported infection rate of 5.88% and 3.37% for the patients in HC and PPP group

Author	Sample Size n	SSI (Overall)	SSI (Hair Preserved)	SSI (Hair Clipped)
Winston KR (1992) <sup>10</sup>	312		0.3%	
Ratanalert S et.al (1999) <sup>13</sup>	225	4.89%	3.37%	5.88%
Tokimura et.al (2009) <sup>12</sup>	632		1.1%	
Hwang et.al (2012) <sup>14</sup>	93		0%	
Our Study	726	1.52%	1.22%	1.67%

Table 4: Literature review of occurrence of SSIs with and without Hair Clipping

found to be statistically significantly associated with SSI, we suggest performing these types of study as large prospective randomised multi-centric trial in Nepal to study the replicability and feasibility of such protocols. In this study, the first to be reported in published literature from Nepal, we have shown that clipping of hair is not essential to avoid wound infection however preparation of scalp is vital.

### Conclusion

Pre-operative clipping of hair does not avoid SSI. Protocol based part preparation practices of scalp and post-operative head hygiene are important to avoid SSIs.

### Abbreviations

HC: preoperative hair clipped; PPP: pre-operative part preparation practices; SSI: surgical site infections

### Acknowledgments

The authors acknowledge the contribution of nurses and doctors of the Department of Neurosurgery at KMCTH.

### Authors' contributions

AT was the chief surgeon, provided the basic concepts to this work and wrote the manuscript in its present form; SM collected the data, performed analysis and wrote the preliminary format; BKC and BS contributed to the management of patients and critically reviewed the manuscript. All authors read and approved the final manuscript.

### Funding

No funding was received to conduct this research work and prepare the manuscript.

### Availability of data and materials

The datasets used and patient information during the current study are available from the corresponding author on request by the Editor-in-Chief of this journal.

### Consent for publication

Written informed consent was obtained from the patients for the publication of this article and accompanying images. A copy of the written consent is available for review by the Editor-in-Chief of this journal on request.

### Competing interests

The authors declare that they have no competing interests.

Video Description: Description of Preoperative Part Preparation (PPP) method to preserving scalp hair before craniotomy (<https://youtu.be/Y36co1aEMIE>)

### References

1. Olson M, O'Connor M, Schwartz ML. A 5-Year Prospective Study of 20,193 Wounds at the Minneapolis VA Medical Center. **Ann. Surg.** **1984;199(3):**253-9. DOI: 10.1097/0000658-198403000-00001
2. Broekman MLD, Beijnum JV, Peul WC, Regli L. Neurosurgery and shaving: what's the evidence? **J Neurosurg.** **2011; 115:**670–8. DOI: 10.3171/2011.5.JNS102003
3. Bhatti MI, Leach PA. The incidence of infection for adults undergoing supra-tentorial Craniotomy for tumours without hair removal. **British Journal of Neurosurgery.** **2013; 27(2):** 218–20. DOI: 10.3109/02688697.2012.743968
4. Adele AO, Olowookere KG. Nonshaved cranial surgery in black Africans: a short-term prospective preliminary study. **Surgical Neurology.** **2008;69:**69-72. DOI: 10.1016/j.surneu.2007.02.046
5. Bekar A, Korfalo E, Dogan S, Yolmazlar S, Basekan Z, Aksoy K. The effect of Hair on Infection after Cranial Surgery. **Acta Neurochirurgica.** **2001;143:**533-7. DOI: 10.1007/s007010170057
6. Adisa AO, Lawal OO, Adejuyigbe O. Evaluation of two methods of preoperative hair removal and their relationship to postoperative wound infection. **J Infect Dev Ctries.** **2011; 5(10):**717-22. DOI: 10.3855/jidc.1527
7. Simona V, Sara P, Filippo F, Barbara S, Giacomo P, Lorenzo G. Cranial Neurosurgery without Hair Removal and Shampoo Care: Retrospective Analysis of 450 Cases. **Pediatr Ther.** **2016;6 (2):**282-5. DOI: 10.4172/2161-0665.1000282
8. Dellen JRV. Barber surgeon, or surgeon barber? **World neurosurgery.** **2012.77(2):**293-5. DOI: 10.1016/j.wneu.2011.02.043
9. Mangram AJ, Horan TC, Pearson ML, Silver LC, Jarvis WR. Guidelines for prevention of surgical site infection: Hospital Infection Control Advisory Committee. **American Journal of Infection Control.** **1999;27(2):**97-134.
10. Winston KR. Hair and neurosurgery. **Neurosurgery.** **1992;31:**320-8. DOI: 10.1227/00006123-199208000-00018
11. Taha MM, Abouhashem S, Abdel-Rahman AY. Neurosurgical Wound Infection at a University Hospital in Egypt; Prospective Study of 1181 Patients or 2 Years. **Turkish Neurosurgery.** **2014;24(1):**8-12. DOI: 10.5137/1019-5149.jtn.6464-12.1
12. Tokimura H, Tajitsu K, Tsuchiya M, Yamahata H, Taniguchi A, Takayama K et.al. Cranial surgery

- without head shaving. **Journal of Cranio-Maxillofacial Surgery.** 2009;37:477-80. DOI: 10.1016/j.jcms.2009.06.003
13. Ratanalert S, Saehaeng S, Sripairojkul B, Liewchanpattana K, Phuenpathom N. Nonshaved cranial neurosurgery. **Surg Neurol.** 1999;51:458–63. DOI: 10.1016/s0090-3019(98)00132-3
  14. Hwang SC, Kim SK, Park KW, Im SB, Shin WH, Kim BT. Outpatient-based scalp surgery without shaving and allowing use of shampoo. **World Neurosurg.** 2012; 77:391-3. DOI: 10.1016/j.wneu.2010.12.052
  15. Haines SJ. Comment on investigations of the bacteriological factors in clean neurosurgical wounds. **Neurosurgery.** 1994;34(3):417-21. DOI: 10.1227/00006123-199403000-00005
  16. Tanner J, Norrie P, Melen K. Preoperative hair removal to reduce surgical site infection (review). **Cochrane Database Systematic Reviews.** 2011;11:1-49. DOI: 10.1002/14651858.CD004122.pub4
  17. Oh WO, Yeom I, Kim DS, Park EK, Shim KW. Effect of Unshaven Hair with Absorbable Sutures and Early Postoperative Shampoo on Cranial Surgery Site Infection. **Pediatr Neurosurg.** 2018; 53(1):18-23. DOI: 10.1159/000481437
  18. Kose G, Tastan S, Kutlay M, Bedir O. The effects of different types of hair shaving on the body image and surgical site infection in elective cranial surgery. **Journal of Clinical Nursing.** 2015; 25:1876–85. DOI: 10.1111/jocn.13149