

Pankaj Raj Nepal

FCPS Neurosurgery

B&C Medical College Teaching Hospital,

Address for correspondence:

Pankaj Raj Nepal, FCPS Neurosurgery

Deputy Director and Head of Department,

Department of Neurosurgery

B&C Medical College Teaching Hospital,

Birtamode, Jhapa.

Phone No: +977-9801098106

Email: drprnepal@yahoo.com

Date submitted : 01 August 2019

Date accepted : 31 August 2019

Early Experience of Microsurgical Clipping of Ruptured Intracranial Aneurysms.

To see the outcome in patients following microsurgical clipping of ruptured intracranial aneurysms and analyze the results. It is a prospective analytical study where demographic data of the patient, initial World Federation of Neurosurgical Societies (WFNS) grade, Fischer's grade, duration of ictus, intraoperative rupture, incidence of clinical vasospasm and Modified Rankin Scale (MRS) at three months were collected and analysis was done using SPSS-20.

There were total 19 cases of microsurgical clipping, with mean age 55.4yrs, where 52.4% were females. Average duration of Ictus was 24.5 hours. Most common WFNS grade on presentation was grade II (42%) and Fischer's CT grade was IV (58%). Commonest site of aneurysm was ACom (53%) and were 15.8% intraoperative rupture. Ventriculo-peritoneal (VP) shunt and severe clinical vasospasm both were seen in 10.5%. Overall mortality was 11% and MRS 1 and 2 were obtained in 10% and 58% respectively. Good initial WFNS, internal carotid aneurysm, absence of hydrocephalus and absence of clinical vasospasm were significantly associated with better MRS at three months. Factors associated with better outcome were good initial WFNS, internal carotid aneurysm, absence of hydrocephalus and absence of clinical vasospasm.

Key words: Aneurysms, Modified Rankin Scale, Microsurgical clipping, vasospasm, hydrocephalus.

Ruptured intracerebral aneurysms account for high morbidity and mortality all around the world, where only one third seems to go back to their functional life and another one third live a life of dependence.^{1,2,12,18,19,21} There are various surgical strategies for the management of those aneurysms, which can be broadly divided into endovascular management and microsurgical clipping.^{8,9,20}

Mortality of aneurysm following microsurgical clipping is as high as 26% in various series.^{1,5,6,14} Mortality in the aneurysm surgery is mainly due to vasospasm, which is approximately 13.5%.^{5,6,10,11} Hydrocephalus following subarachnoid hemorrhage who needs ventriculoperitoneal shunt is around 10% in different series.^{3,16}

With the objective to evaluate the outcome in patients following microsurgical clipping of ruptured intracranial aneurysms and analyze their results this study was performed.

Methods and Materials:

Study design: Prospective analytical study. Sampling technique: Non-probability consecutive sampling. Sample size: 19 cases. Site of study: B and C Medical College and Teaching hospital, Birtamode, Jhapa, Nepal. Duration of Study: One Year (13th Feb, 2018 to 12 Feb, 2019)

Data collection and analysis:

All the cases of the ruptured intracerebral aneurysms who underwent microsurgical clipping by the author were collected prospectively. Demographic data of the patients, age, gender, initial World Federation of Neurological Societies (WFNS) grade (Table 1), Fisher's grade (Table 2), duration of ictus, location of aneurysm, intraoperative rupture, hydrocephalus (HCP) needing Ventriculoperitoneal (VP) shunt, clinical vasospasm and Modified Rankin Scale (MRS) (Table 3) at three months were collected in a preformed proforma.

Grade	Findings
I	GCS 15, no motor deficit
II	GCS 13-14, no motor deficit
III	GCS 13-14, motor deficit
IV	GCS 7-12 +/- motor deficit
V	GCS 3-6, motor deficit present or absent

Table 1: WFNS Grading for Subarachnoid Hemorrhage

Grade	CT Findings
1	No hemorrhage evident
2	Diffuse or vertical layer subarachnoid hemorrhage <1 mm thick
3	Localized clot and/ or vertical layer of subarachnoid hemorrhage >= 1mm thick
4	Intracerebral or intraventricular clot, with or without a diffuse subarachnoid hemorrhage

Table 2: Fisher's scale of SAH

Score	Description
0	No symptoms at all
1	No significant disability despite symptoms; able to carry out all usual duties and activities
2	Slight disability; unable to carry out all previous activities, but able to look after own affairs without assistance
3	Moderate disability; requiring some help, but able to walk without assistance
4	Moderately severe disability; unable to walk without assistance and unable to attend to own bodily needs without assistance
5	Severe disability; bedridden, incontinent and requiring constant nursing care and attention
6	Dead

Table 3: Modified Rankin Scale (MRS)

Continuous variables like age and duration of ictus were shown as mean and standard deviation (SD). Categorical data like gender, initial WFNS grade, Fisher's grade, location of aneurysms, HCP who needed VP shunt, clinical vasospasm, and MRS at three months were presented as percentage. Fisher's Exact test was used to see the association between different categorical data and MRS at three months. In the same way, One Way ANOVA test was used to analyze the association between duration of ictus and MRS at three months.

Results:

There were total of 19 cases that underwent microsurgical clipping during the study duration. The mean age of presentation was 55.4 (SD 13.06) years, where there were 52.4% females and 47.4% males. Average duration of Ictus of aneurysm rupture was 24.5 (SD 14.24) hours. Most common WFNS on presentation was grade II (42%) (Figure 1) and Fischer CT grade was IV (58%) (Figure 2). Commonest aneurysm by location was ACom (53%) (Figure 3), among them anterior and inferior pointing were 40% each followed by 20% being superior pointing. There was 15.8% intraoperative rupture of aneurysm during aneurysm dissection. Around 10.5% of patient developed hydrocephalus during the follow up of three months who required VP shunt and 10.5% patient developed severe clinical vasospasm. Overall mortality was 11% with moderate severe disability 11%. MRS 1 was obtained in 10% and MRS 2 in 58% (Figure 4).

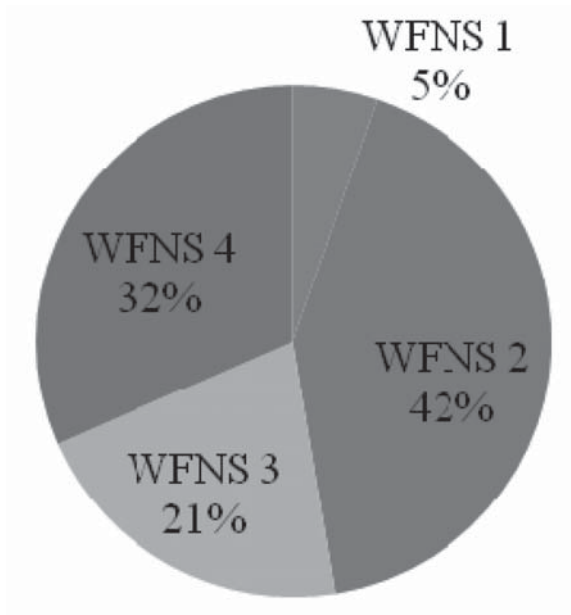


Figure 1: WFNS grading on presentation

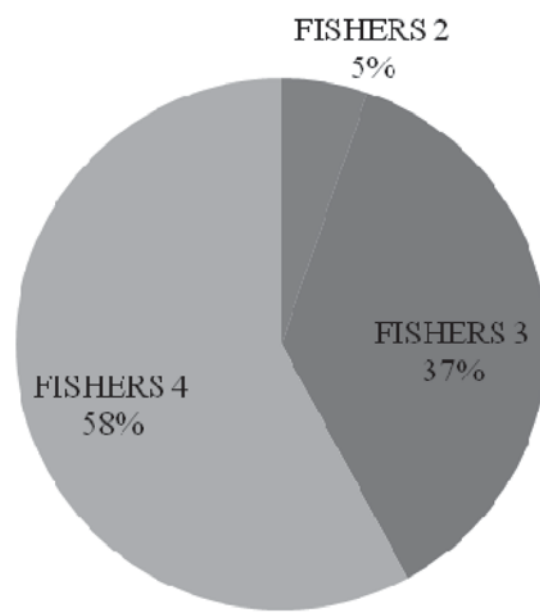


Figure 2: Fisher's grade on presentation

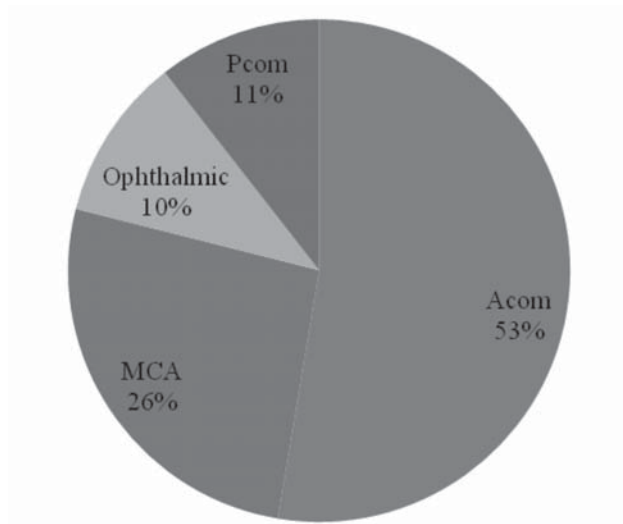


Figure 3: Location of Aneurysms

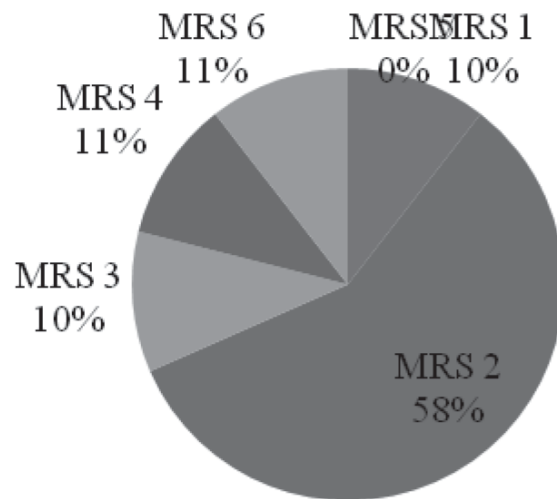


Figure 4: MRS at three months

Age and gender didn't have significant association with MRS at three months. WFNS grading of subarachnoid hemorrhage(SAH) seems to have significant association with MRS, where higher the grade poorer was the outcome and vice versa. Fisher's grade of SAH at the time of presentation didn't had significant association with outcome of patients in terms of MRS. However, location of aneurysm was significantly associated with MRS at three months; the presence of Pcom aneurysms was significantly

associated with favorable outcome. Similarly, presence of hydrocephalus requiring VP shunt and clinical vasospasm had significant association with MRS. Hydrocephalus requiring VP shunt didn't increased mortality; rather, had significant association with unfavorable outcome. However, presence of clinical vasospasm was significantly associated with mortality within three months (Table 4).Duration of ictus was not significantly associated with the MRS at three months (Table 5).

Microsurgical Clipping of Intracranial Aneurysm

		MRS at 3months					P Value
		1	2	3	4	6	
Age	30-39	0	2	0	0	0	.763
	40-49	0	3	1	0	1	
	50-59	0	3	0	1	1	
	60-69	1	2	0	0	0	
	70-79	1	1	0	1	0	
	80-89	0	0	1	0	0	
Gender	Female	1	6	0	1	2	.646
	Male	1	5	2	1	0	
Initial WFNS grading of SAH	1	1	0	0	0	0	.012*
	2	1	7	0	0	0	
	3	0	3	1	0	0	
	4	0	1	1	2	2	
Fisher's grade of SAH	2	1	0	0	0	0	.096
	3	1	6	0	0	0	
	4	0	5	2	2	2	
Location of Aneurysms	Acom	0	7	0	2	1	.045*
	MCA	0	2	2	0	1	
	Ophthalmic	2	0	0	0	0	
	PCOM	0	2	0	0	0	
VP shunt following HCP	no	2	11	2	0	2	.023*
	yes	0	0	0	2	0	
Clinical Vasospasm	no	2	11	2	2	0	.023*
	yes	0	0	0	0	2	

Table 4: Analysis of different categories with the MRS at three months.

	N	Mean	SD	95% CI for Mean		P value
				Lower	Upper	
1	2	18.50	4.950	-25.97	62.97	
2	11	31.00	12.602	22.53	39.47	
3	2	8.00	5.657	-42.82	58.82	.076
4	2	27.50	20.506	-156.74	211.74	
6	2	9.00	2.828	-16.41	34.41	

Table 5: One way ANOVA test between duration of ictus and MRS at 3 months.

Discussion:

Various studies had shown poor outcome with advancing age; however, this study with mean age of 55.4 years showed no significant association of age with the outcome at three months.^{5,6} In previous literatures, they had shown no significant association of gender with the outcome of patients, and this was similar in our study as well, despite of slight female predominance.^{5,6,18,19} The large international cooperative study had shown good condition at the time of admission is associated with better outcome with overall mortality of around 26%, similarly, in this study, better WFNS grading at the time of admission was significantly associated with better MRS at three months, compared to those who had poor WFNS grade at admission with overall mortality of 11%.^{5,6,15}

Minimal clot distribution in CT scan had been associated with favorable outcome in the previous literature; however, in this study the association was not significant and might be due to small sample size of Fisher's grade 1 and 2 at presentation.^{5,6,7,12,13}

In this study, all the cases were of anterior circulating aneurysms; though, some literatures grouped Pcom aneurysm in posterior circulation.⁴ The presence of ophthalmic and Pcom aneurysms were significantly associated with favorable outcome at three months and this might be largely due to less cerebral dissection during surgery. Similar results were obtained in previous studies where better outcome was seen with MCA aneurysm and internal carotid aneurysm, when they were compared with vertebrobasilar or other anterior circulating aneurysms.^{5,6,7}

Presence of clinical vasospasm was significantly associated with higher mortality in our study. There was 10.5% vasospasm developed during post operative course was similar to other studies.^{10,11,14} Presence of hydrocephalus was also associated with poor outcome in our studies, and was similar with many other studies from the past.^{3,14}

Conclusion:

As a young neurosurgeon in an early career working at far eastern part of Nepal, where facilities are very limited and transporting patients are with great risks, we are able to produce similar outcome in the microsurgical clipping of aneurysm when compared to the results of better centers around the world. In this study factors associated with better outcome were seen with good initial WFNS, internal carotid aneurysm, absence of hydrocephalus and clinical vasospasm.

Acknowledgement: I highly appreciate the microsurgical teaching of Late.Prof. Upendra P. Devkota, without which I don't think I could have produced this result.

References:

1. Devkota UP, Aryal KR. Result of surgery for ruptured intracranial aneurysms in Nepal. **Br J Neurosurg** 15(1): 13-6, 2001
2. Fox J. Intracranial Aneurysms. **New York: Springer-Verlag**;1983.
3. Graff-Radford NR, Torner J, Adams HP Jr, Kassell NF. Factors associated with hydrocephalus after subarachnoid hemorrhage. A report of the Cooperative Aneurysm Study. **Arch Neurol** 46:744 – 752, 1989
4. International Study of Unruptured Intracranial Aneurysms Investigators. Unruptured intracranial aneurysms—risk of rupture and risks of surgical intervention. **N Engl J Med** 339(24):1725-1733, 1998
5. Kassell NF, Torner JC, Haley EC Jr, Jane JA, Adams HP, Kongable GL. The International Cooperative Study on the Timing of Aneurysm Surgery. Part 1: overall management results. **J Neurosurg** 73:18 – 36, 1990
6. Kassell NF, Torner JC, Jane JA, Haley EC Jr, Adams HP. The International Cooperative Study on the Timing of Aneurysm Surgery. Part 2: surgical results. **J Neurosurg** 73:37 – 47, 1990
7. Kassell NF, Torner JC. The International Cooperative Study on Timing of Aneurysm Surgery – an update. **Stroke** 15:566 – 570, 1984
8. Molyneux A, Kerr R. International Subarachnoid Aneurysm Trial (ISAT) Collaborative Group, Stratton I, Sandercock P, Clarke M, Shrimpton J, Holman R. International Subarachnoid Aneurysm Trial (ISAT) of neurosurgical clipping versus endovascular coiling in 2143 patients with ruptured intracranial aneurysms: a randomized trial. **J Stroke Cerebrovasc Dis** 11:304 – 314, 2002
9. Molyneux A, Kerr R; International Subarachnoid Aneurysm Trial (ISAT) Collaborative Group, Stratton I, Sandercock P, Clarke M, Shrimpton J, Holman R. International Subarachnoid Aneurysm Trial (ISAT) of neurosurgical clipping versus endovascular coiling in 2143 patients with ruptured intracranial aneurysms: a randomized trial. **J Stroke Cerebrovasc Dis** 11:304 – 314, 2002
10. Pearl JD, Macdonald RL. Vasospasm after aneurysmal subarachnoid hemorrhage: need for further study. **Acta Neurochir Suppl** 105:207-210, 2008

Microsurgical Clipping of Intracranial Aneurysm

11. Pluta RM, Hansen-Schwartz J, Dreier J, et al. Cerebral vasospasm following subarachnoid hemorrhage: time for a new world of thought. **Neurol Res** **31(2)**:151-158, 2009
12. Provenzale JM, Hacin-Bey L. CT evaluation of subarachnoid hemorrhage: a practical review for the radiologist interpreting emergency room studies. **EmergRadiol** **16(6)**:441-451, 2009
13. Rajbhandari B, Sharma MR, Shilpakar SK, Sedhain G, Pradhanang A, Shrestha RK, Kafle P, Shrestha DK, Koirala PR. Prediction of aneurysm location based on pattern of bleed on CT scan. **Journal of Society of Surgeons of Nepal** **21(1)**: 21-28, 2018
14. Roka YB, Shrestha M, Puri PR, Adhikari HB. Surgery for Intracerebral Aneurysms in Eastern Nepal: A New Beginning. **Nepal Journal of Neuroscience** **9**:5-9, 2012
15. Sharma GR, Kausal P, Jha R, Khadka N, Adhikari DR, Bista P, Sultania PK. Outcome of Microsurgical Clipping of Intracranial Aneurysms in Bir Hospital. **Nepal Journal of Neuroscience** **8(2)**: 137-142, 2011
16. Sheehan JP, Polin RS, Sheehan JM, et al. Factors associated with hydrocephalus after aneurysmal subarachnoid hemorrhage. **Neurosurgery** **45(5)**:1120-1127:discussion 1127-1128, 1999
17. Shrestha P, Singh AM, Dhungana I. Cerebral Aneurysm Surgery in B & B hospital: An Experience of Last One Year. **BBMed** **1**: 23-28, 2017
18. Weir B. Unruptured intracranial aneurysms: a review. **J Neurosurg** **96(1)**:3-42, 2002
19. Wiebers DO, Whisnant JP, Huston 3rd J, et al. Unruptured intracranial aneurysms: natural history, clinical outcome, and risks of surgical and endovascular treatment. **Lancet** **362(9378)**:103-110, 2003
20. Wolstenholme J, Rivero-Arias O, Gray A, Molyneux AJ, Kerr RS, Yarnold JA, Sneade M; International Subarachnoid Aneurysm Trial (ISAT) Collaborative Group. Treatment pathways, resource use, and costs of endovascular coiling versus surgical clipping after a SAH. **Stroke** **39**:111 – 119, 2008
21. Woo D, Khoury J, Haverbusch MM, et al. Smoking and family history and risk of aneurysmal subarachnoid hemorrhage. **Neurology** **72(1)**:69-72, 2009