

Case Reports

Puspa Raj Koirala

MBBS, MS, Second Year MCh Neurosurgical Resident,
Institute of Medicine, Tribhuvan University Teaching
Hospital, Kathmandu, Nepal

Binod Rajbhandari

MBBS, MS, Third-Year MCh Neurosurgical Resident,
Institute of Medicine, Tribhuvan University Teaching
Hospital, Kathmandu, Nepal

Gopal Sedain

MS, MCh Neurosurgery, Assistant Professor, Department
of Neurosurgery, Tribhuvan University Teaching
Hospital, Kathmandu, Nepal

Sushil Krishna Shilpakar

MS Neurosurgery, Professor, Head of Department,
Department of Neurosurgery, Tribhuvan University
Teaching Hospital, Kathmandu, Nepal

Address for correspondence:

Puspa Raj Koirala
Department of Neurosurgery, TU Teaching Hospital,
Maharajgunj, Kathmandu, Nepal.
E-mail address: pussparajkoirala@gmail.com

Date submitted: 30/7/2018

Date accepted: 20/8/2018

Spinal Extradural Arachnoid Cyst: A Case Report

Spinal extradural arachnoid cyst is a rare cause of spinal cord compression resulting in spinal myelopathy. We report a case of 12-year-old boy diagnosed with extradural thoracolumbar spinal arachnoid cyst presenting with back and leg pain, progressive left leg weakness, mild muscular atrophy and difficulty in walking. The boy presented with progressive weakness of distal left lower limb and intermittent claudication. MRI-scan revealed an extramedullary non-enhancing fluid signal intensity lesion with cord compression. The patient underwent zip laminectomy from T9 - L2 level using electric drill and total excision of the extradural cyst, microsurgical repair of the dural defect, followed by laminoplasty, using ethibond sutures was done. Intraoperative finding revealed an elongated 10 cm long cystic lesion with finger-like projections extending in the extradural space from T9 - L2 level, causing significant compression and displacement of the cord. The cyst was in communication with intradural subarachnoid space with a small ovoid-shaped arachnoid opening at T12 level on the left side adjacent to T11 nerve root. The postoperative course was uneventful and patient was discharged on postoperative day seven. Neurologically, the patient showed some improvement. On one-month follow-up, there was remarkable improvement in movement of the lower limbs. He was able to walk independently without limping gait; however, he still had mild weakness in his left leg (4+/5).

Keywords: spinal arachnoid cyst, laminoplasty.

Spinal arachnoid cyst is a non-cancerous sac filled with cerebro-spinal fluid (CSF) that is formed due to abnormal separation of arachnoid layer. It is an uncommon pathology and, furthermore, is a rare cause of spinal myelopathy secondary to cord compression. These cysts most commonly occur in the middle to lower

thoracic spine but also have been reported in the lumbar, lumbosacral, and thoracolumbar regions. It is believed that extradural arachnoid cysts develop from outpouching of arachnoid herniating through a small dural defect to form an arachnoid hernia or diverticula; and then the progressive enlargement of this cyst can result in symptomatic cord



compression. The presenting clinical symptoms may vary, including from back/leg pain, paresthesia, neurogenic intermittent claudication, bowel/bladder dysfunction, to variable degree of spasticity and weakness. The cysts have a pedicle in communication with the spinal subarachnoid space and, because of their origin, contain CSF. MRI is said to be the diagnostic procedure of choice and can demonstrate the nature of cyst, size, and the anatomic relationship with the spinal cord.

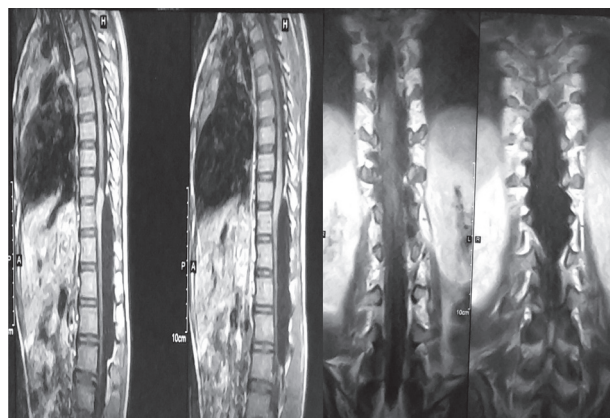
The etiology and pathogenesis of spinal extradural arachnoid cysts are still unclear. Although they most probably have a congenital origin, some may be acquired due to trauma, iatrogenic damage, hemorrhage, meningeal infection, or inflammation.¹

Here, we report a rare case of 10-cm long spinal extradural arachnoid cyst in thoracolumbar spine successfully treated with surgical obliteration of the communicating dural defect and complete excision of the cyst via laminoplasty.

Case Report

Clinical History

A 12-year-old boy presented to Neurosurgical Out-Patient Clinic at Tribhuvan University Teaching Hospital, Kathmandu, Nepal, with chief complaint of back and left leg pain and weakness of distal left leg and difficulty in walking for five months. The left leg weakness was gradually progressive in nature. There was mild muscle atrophy in distal lower extremities, particularly on the left leg. He had difficulty in walking by himself for more than few minutes at a time, so-called neurogenic intermittent claudication. There was no obvious history of trauma, fever or coagulopathy. Past history of the patient revealed



no significant underlying illnesses or congenital syndromes like Down syndrome, metabolic deficiency disorders or neurofibromatosis. He was a healthy and active school boy. His bowel and bladder habits were normal without incontinence. On neurological examination, motor power was 5/5 in his right leg; and in his left leg, dorsiflexion of left foot was 2/5, extensor hallucis longus (EHL) was also 2/5 and plantar flexion was 3/5. Sensation was intact. There was mild muscular atrophy in distal part of his legs, left being more prominent than the right leg with increased tone of both lower limbs. He was able to walk with support with a left limping gait. Hyperreflexia was noted in both legs and it was more prominent on the left leg with positive Babinski reflexes on both legs.

Preoperative photograph showing left distal leg weakness (foot drop) and mild muscular wasting on both legs.

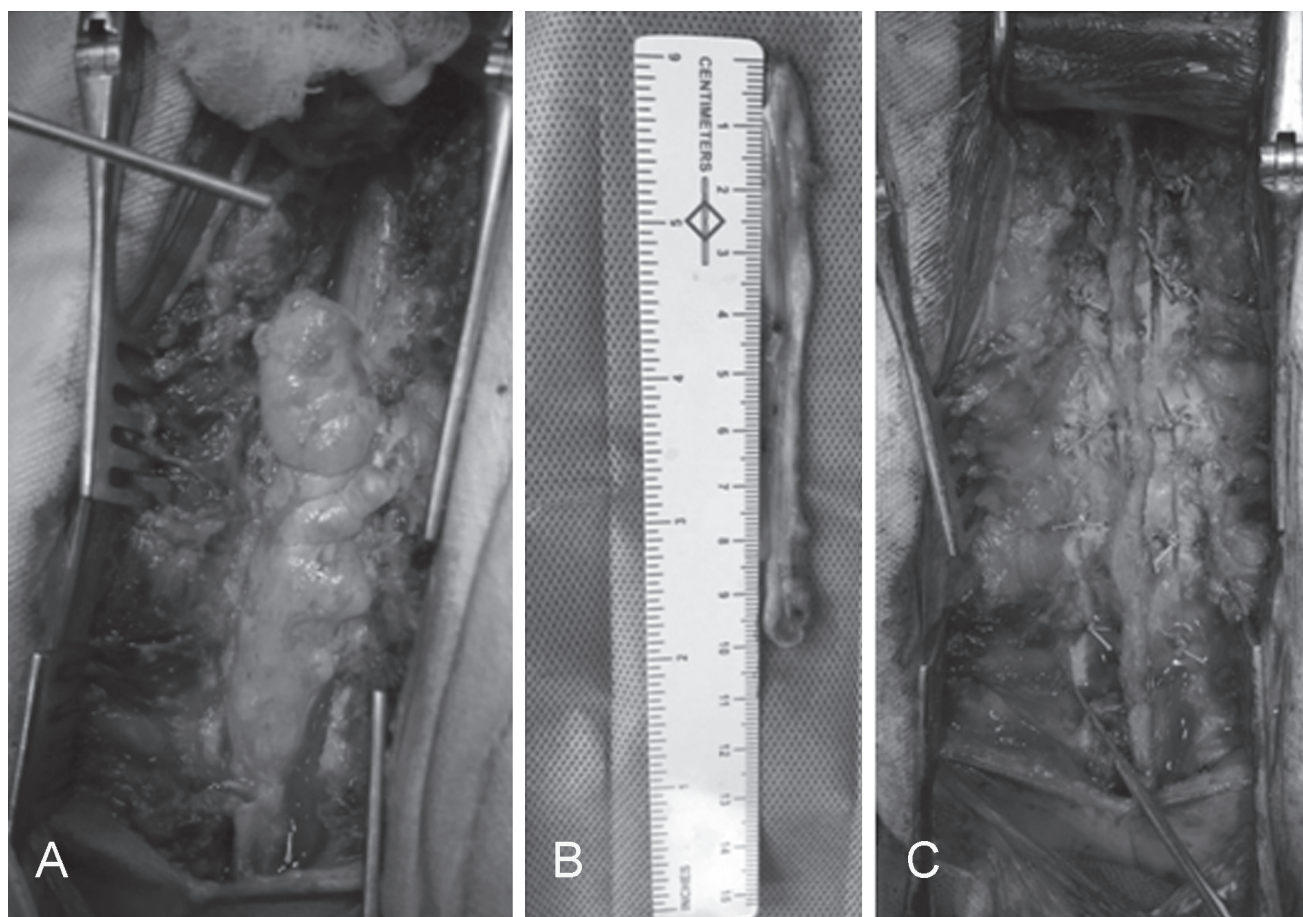
Radiological Imaging

MRI of Thoracolumbar spine revealed long segment, fluid signal intensity extramedullary lesion in the posterior aspect of central spinal canal with diffused compression of spinal cord, extending from T9 to L2 vertebral body level (**Fig 1A-D**). The lesion demonstrated no enhancement in contrast images.

MRI of T-L spine: showing long segment, CSF-signal intensity extramedullary cystic lesion in the posterior aspect of central spinal canal with diffused compression of spinal cord, extending from T9 to L2 vertebral body level (A) Non-contrast T1-weighted image in Sagittal sequence (B) Contrast image demonstrating no enhancement of the lesion (C, D) Coronal sequences.

Intraoperative Findings

The arachnoid cyst was exposed by multiple laminectomies from T9 –L2. The Large-sized arachnoid cyst located dorsal to spinal cord. It was 10 cm long cyst with finger-like projections on either side, extending from T9 to L2 vertebral level, causing significant compression posteriorly and on the left side, displacing of the cord to



the right anterior region . On exposure, there was 4 mm-sized ovoid-shaped dural defect in left dorsolateral aspect adjacent to T11 nerve root. The cyst was in communication with intradural subarachnoid space and contained clear cerebro-spinal fluid with few rootlets of left T11 nerve root protruding into the cyst through the small opening.

Surgical Treatment

Once the diagnosis was made, the patient underwent multiple laminectomy “zip surgery” extending from T9 to L2 spine level. Using Stryker electric neuro drill craniotome with burr, small laminotomies were made at L2-3 level, one on each side. Using 2 mm 45 Kerrison punch, the laminotomies were extended and the cal sac was exposed. Multiple level laminectomies in one piece with intact Supra/interspinous ligaments extending from L2 to T9 level was made using Electric neuro drill with footplate to make continuous longitudinal cuts on either side of the lamina. The supraspinous and intraspinal ligaments including ligamentum flavum were incised at L2-3 level. Then, the entire length of laminae and spinous processes of L2 to T9 was reflected upward and temporarily transfixed to skin using 2-0 silk suture. The elongated arachnoid cyst was seen extending from T9 to L2 on the dorsal aspect, displacing the spinal cord to the right and anteriorly.

The large extradural arachnoid cyst with the finger-like projections on either side was meticulously dissected off the dura mater from T9 level caudad and from L2 level cephalad until 4-mm ovoid-shaped dural attachment. The dural defect was noted on the left side just adjacent to the left T11 nerve root. The dural defect was dissected circumferentially. A small dural opening was made using number 15 scalpel blade; and a small micropattie was inserted through the dural opening pushing the protruding rootlets anteriorly into the intradural subarachnoid space. Using continuous 4-0 Vicryl suture, microsurgical repair of the defect was achieved . Following the repair of the defect, Valsalva manoeuvre was performed to check for any CSF leakage through the defect.

After copious irrigation and meticulous hemostasis, along the entire length of the laminae and spinous processes from T9 to L2 drill holes were made on the lamina and facet on either sides at every spinal level, number 1 Ethibond suture was then passed through the holes; and the sutures were snugly tightened to fix the laminae and spinous processes in its original position. The incision was finally closed in layers, including muscle/fascia, subcutaneous layer and skin. No drain was placed. Postoperatively, the patient was placed on TLSO brace.

Intraoperative Photographs: (A) after multiple laminectomies, elongated extradural arachnoid cyst with finger-like projections dorsal to the cord extending from D9 to L2 level, (B) 10 cm long excised specimen and (C) laminoplasty suturing on both sides with ethibond sutures.

Postoperative Course

The postoperative course was uneventful. The patient was allowed to ambulate on postoperative day (POD) 2 with TLSO brace. He was discharged on POD 7. The incision was well-healed and the staples were removed on POD 10. Histopathological examination of the cyst wall was consistent with findings of arachnoid cyst. Neurologically, the patient showed some improvement, particularly in significant reduction of spasticity in both lower extremities. Babinski sign became absent on both sides. On one-month follow-up, there was remarkable improvement in movement of the lower limbs. He was able to walk independently without limping gait; however, he still had mild weakness in his left distal leg (4+/5), with partial foot drop. Currently, the patient is still receiving physiotherapy including active and resistive exercises and gait training.

Discussion

Arachnoid cysts may be located intracranially or in the spine. Intracranial arachnoid cysts are commonly seen in middle fossa and account for approximately 1% of intracranial space-occupying lesions. Spinal arachnoid cysts, whether intradural or extradural, are an uncommon cause of myelopathy secondary to spinal cord compression.²⁻⁴

In regards to age distribution, spinal arachnoid cysts can present at any age; however, thoracic spinal arachnoid cysts predominantly present during adolescence. In regards to sex predilection, no gender predominance is apparent for intradural arachnoid cysts; however, extradural arachnoid cysts are more common in male patients. Spinal arachnoid cysts may be related to inflammation from hemorrhage or infection, trauma or a certain syndromes (such as Down syndrome, Mucopolysaccharidosis, Schizencephaly and Neurofibromatosis).

The exact pathophysiological mechanism for spinal arachnoid cyst formation is not yet clear. At least five theories have been postulated, particularly in adults, which includes (a) congenital; (b) arachnoid adhesions secondary to an inflammatory process caused by virus, spirochetes, or bacteria; (c) arachnoiditis secondary to subarachnoid hemorrhage, contrast media, spinal anesthetics, meningitis; (d) traumatic injuries to the vertebral column, lumbar punctures used in diagnostic procedures, or anesthetic

and intradural surgery; and (e) idiopathic.⁵⁻⁷ It has been documented earlier that asymptomatic congenital cysts could be enlarged due to trauma and become symptomatic. (8,9) CSF pulsation, osmotic gradient and valve-like mechanism between the subarachnoid space and cyst, and the valve-like mechanism may play an important role in the formation and the enlargement of the cyst.

On the basis of when the arachnoid cysts occurs, it can be classified into two types of arachnoid spinal cysts: primary (congenital) and secondary (acquired). Primary arachnoid cysts are present at birth; whereas, secondary arachnoid cysts develop later in life. Primary cysts are more common, and men are more likely to develop the cyst than woman. The exact cause of primary cysts is unknown. Secondary cysts are caused by trauma, hemorrhage, meningitis, tumors, surgery or lumbar puncture.^{10, 11}

Most cases of spinal arachnoid cysts are idiopathic, and those of traumatic origin are especially rare. In all cases, however the disease results from the herniation of the arachnoid through a defective or fragile dura mater (12-14) Spinal arachnoid cysts are relatively uncommon and may be either intradural (type III meningeal cyst) or extradural (type IA meningeal cyst). In our case, there is no history of trauma, surgical procedure or any congenital syndromes, making it most likely to be idiopathic in etiology. In addition, the arachnoid cyst belongs to type IA on the basis of where the lesion is within the spinal canal.

In regards to the location, most of primary intradural spinal arachnoid cysts are located dorsal to the cord. They occur mostly at thoracic spine level (80%), followed by cervical (15%) and lumbar spine (5%). On the other hand, secondary spinal arachnoid cysts can be located anywhere, depending on where the insult has occurred. In the present case, there is history of trauma, infection or associated disease implying that it should be congenital or primary. Furthermore, the cyst is very large with finger-like projection, extending from T9 to L2 spine level.

The clinical manifestations produced by spinal arachnoid cyst depend on its size and location. Most of the cysts are asymptomatic and are discovered incidentally. Though most of these cysts are asymptomatic especially when small to start with, once it enlarges it can compress the spinal cord and exiting nerve roots, causing pain, weakness or paresthesia in the extremities. These symptoms may be exacerbated by postural changes and the Valsalva maneuver. Common clinical symptoms include back and leg pain, tingling in the arms or legs, muscle spasms/weakness, walking difficulty, and bowel/bladder incontinence. Large arachnoid cysts, particularly in the lumbar region, can cause caudal equine syndrome (bowel/bladder incontinence), neurogenic claudication

(cramping pain on walking) and radiculopathy (sharp radiating pain to the extremities). In our patient, he presented with back and left leg pain with weakness of distal leg prominently left leg, intermittent claudication and difficulty in walking; but no sensory symptoms or bowel/bladder incontinence.

Image testing is required to properly diagnose a spinal arachnoid cyst. Usually the cyst can be detected with an MRI scan that is also useful to rule out any other conditions. In regards radiological Imaging, MRI is the choice of investigation. In MRI-scan, as the cysts follow the intensity of CSF and their walls are generally not visible, they may not be identified unless the cord is displaced. On T1-weighted images, the cyst is of CSF intensity and similar in T2 weighted images. However, in T2-weighted images, it may even be brighter than CSF, since there is no signal loss from pulsation/flow. On contrast images, there is contrast enhancement and on phase-contrast imaging, there is decreased CSF flow within the cyst. Diffusion-weighted images (DWI) show no restriction of diffusion. In the present case, MRI scan revealed a non-enhancing elongated segmental fluid signal cystic lesion in the posterior aspect of spinal canal causing diffuse cord compression from T9 to L2 level. However, it was difficult to localize whether it was extradural or intramural on the scans.

In case of intradural arachnoid cysts, a number of differential diagnoses like herniated ventral cord, epidermis/dermoid cyst or hydatid cyst/ neurocysticercosis should be considered. Rarely, extradural arachnoid cysts may be confused with synovial/ganglion cyst or cysts arising from ligamentum flavum or intervertebral disc.

Generally, selection of surgical procedure is based on factors such as the cyst type, size and location. Incidental asymptomatic cysts can be managed conservatively; whereas symptomatic cysts need to be treated with surgical excision. If the arachnoid cyst is small and has not caused any compression symptoms, it may not need emergent treatment and rather can be monitored over time for changes. If the cyst is large and problematic, surgery is the treatment of choice. An important aspect of surgical management of extradural arachnoid cysts should include proper closure of the arachnoid defect, if present, which could become a source of CSF leak.

Rarely, the cyst cannot be excised due to severe adhesions. In such cases, drainage via cyst genes traction or shunting with insertion of a tube from the cyst to abdominal cavity (cystoperitoneal shunt) may be performed. In our case, multiple-level laminectomy was performed using electric drill by making burr holes and cutting on lamina on both sides and incising intra and supraspinous ligament in the inferior level only to lift the

long segment of laminectomized portion. The extradural cyst was completely dissected off the dura mater. The small dural defect was meticulously repaired. To prevent possibility of spinal instability due to the younger age of the patient and the involvement of multiple consecutive vertebral levels, it was decided to undergo laminoplasty by drilling small holes on either side of lamina and facet and tightening with ethibond sutures.

The cyst results from the herniation of the arachnoid through a defective or fragile dura mater. The prognosis of surgical treatment depends on the irreversible insult to cord due to compression, untreated duration with compressive symptoms or presence of other associated pathologies.

Surgical excision or decompression is needed when neurological deficits develop due to compression of cyst on spinal cord or corresponding exiting nerve root(s). Presence of preoperative myelomalacia and prolonged symptomatic clinical history may implicate poor surgical outcome. Complete surgical excision of cyst is commonly advocated as treatment of choice; but, however, this may not always be possible, especially in cases with intradural arachnoid cysts adherent to the cord or the nerve roots. In such cases, complete cyst removal may be hazardous and may require to sacrifice nerve roots resulting neurological deficits.

Conclusion

Spinal extradural arachnoid cyst is a rare pathology resulting in cord compression. The etiology, pathogenesis and treatment of the spinal extradural have yet to be well-established. During surgery, dural defect should be repaired meticulously. Neurological recovery seems to depend on the size of the cyst and the degree and duration of the spinal cord compression. In cases of spinal arachnoid cyst, particularly in younger age, with associated syndromes and with shorter clinical duration of symptoms tends to have neurological recovery. However, in delayed cases, surgery may be offered as an intervention with prophylactic purpose to prevent further neurological impairment, rather than a curative management. In this study, we report a very uncommon case of extradural thoracolumbar spinal arachnoid cyst, presenting with significant spinal myelopathic symptoms diagnosed with MRI-scanning. He was successfully operated via multiple laminectomies, complete cyst excision, microsurgical repair of the tiny dural defect, followed by laminoplasty using sutures.

References

1. Lolge S, Chawla A, Shah J et-al. MRI of spinal intradural arachnoid cyst formation following tuberculous meningitis. **Br J Radiol** 77 (920): 681-4, 2004

Koirala et al

2. Kikuta K, Hojo M, Gomi M, Hashimoto N, Nozaki K. Expansive duraplasty for the treatment of spinal extradural arachnoid cysts: case report. **J Neurosurg Spine** 4:251–255, 2006
3. Myles LM, Gupta N, Armstrong D, Rutka JT. Multiple extradural arachnoid cysts as a cause of spinal cord compression in a child. case report. **J Neurosurg** 91 :116–120, 1999
4. Marbacher S, Barth A, Arnold M, Seiler RW. Multiple spinal extradural meningeal cysts presenting as acute paraplegia. case report and review of the literature. **J Neurosurg Spine** 6: 465–472, 2007
5. Kazan S, Ozdemir O, Akyüz M, Tuncer R. Spinal intradural arachnoid cysts located anterior to the cervical spinal cord. Report of two cases and review of the literature. **J Neurosurg** 91:211–215 ,1999
6. Lee TT, Alameda GJ, Gromelski EB, Green BA. Outcome after surgical treatment of progressive posttraumatic cystic myelopathy. **J Neurosurg** 92 :149–154, 2000
7. Suryaningtyas W, Arifin M. Multiple spinal extradural arachnoid cysts occurring in a child. **J Neurosurg** 106 :158–161, 2007
8. Myles LM, Gupta N, Armstrong D, Rutka JT. Multiple extradural arachnoid cysts as a cause of spinal cord compression in a child. case report. **J Neurosurg** 91:116–120, 1999
9. Marbacher S, Barth A, Arnold M, Seiler RW. Multiple spinal extradural meningeal cysts presenting as acute paraplegia. case report and review of the literature. **J Neurosurg Spine** 6 465–472, 2007
10. Osborn AG. Diagnostic neuroradiology. Mosby Inc, 1994
11. Brant WE, Helms CA. Fundamentals of Diagnostic Radiology. Lippincott Williams & Wilkins, 2007
12. Liu JK, Cole CD, Kan P, Schmidt MH. Spinal extradural arachnoid cysts: clinical, radiological, and surgical features. **Neurosurg Focus** 22:E6, 2007
13. Lee TT, Alameda GJ, Gromelski EB, Green BA. Outcome after surgical treatment of progressive posttraumatic cystic myelopathy. **J Neurosurg** 92 :149–154 , 2000
14. Lee TT, Arias JM, Andrus HL, Quencer RM, Falcone SF, Green BA. Progressive posttraumatic myelomalacic myelopathy: treatment with untethering and expansive duraplasty. **J Neurosurg** 86:624–628, 1997