

**Case Reports****Prakash Kafle, MBBS, MS**

Department of Neurosurgery

Institute of Medicine

Tribhuvan University Teaching Hospital,

Kathmandu Nepal

**Sushil K Shilpakar, MS**

Department of Neurosurgery

Institute of Medicine

Tribhuvan University Teaching Hospital

**Mohan R Sharma, MS**

Department of Neurosurgery

Institute of Medicine

Tribhuvan University Teaching Hospital

**Gopal Sedain, MS, MCh**

Department of Neurosurgery

Institute of Medicine

Tribhuvan University Teaching Hospital

**Amit K Pradhanang, MS, Mch**

Department of Neurosurgery

Institute of Medicine

Tribhuvan University Teaching Hospital

**Ram K Ghimire, MBBS MS**

Department of Neurosurgery

Institute of Medicine

Tribhuvan University Teaching Hospital

**Binod Rajbhandari, MBBS, MS**

Department of Neurosurgery

Institute of Medicine

Tribhuvan University Teaching Hospital

Lhermitte-Duclos Disease

**Address for Correspondence:**

Prakash Kafle, MBBS, MS

Department of Neurosurgery

Institute of Medicine

Tribhuvan University Teaching Hospital

Kathmandu Nepal

**Email:** prakashkaflee@gmail.com**Received,** 13 February, 2017**Accepted,** 21, February, 2017

**L**hermitte- Duclos disease (LDD) or dysplastic cerebellar gangliocytoma is a rare disease of the cerebellum.<sup>1</sup> It is also known by various other names, like ganglioneuroma or purkinjioma granular cell hypertrophy of the cerebellum. Only few cases

# Lhermitte-Duclos Disease: A Case Report

---

Dysplastic gangliocytoma of the cerebellum or also known as Lhermitte-Duclos disease (LDD) is a rare disorder characterized by a slowly enlarging mass lesion in the cerebellum. It is associated with phacomatosis and an autosomal dominant neoplastic syndrome like Cowden's syndrome. Modern neuroimaging contributes to diagnosis and postoperative evaluation.

Here, we report a case of LDD in a young male patient.

**Key Words:** Cowden's syndrome, dysplastic Cerebellar Gangliocytoma, Lhermitte Duclos Disease

---

have been reported in the literature.<sup>1</sup> Lhermitte and Duclos combinedly first described dysplastic cerebellar gangliocytoma in 1920.<sup>6</sup> The pathophysiology of the disease is poorly understood.<sup>3</sup> It is a cerebellar mass with features of both malformation and low grade neoplasm

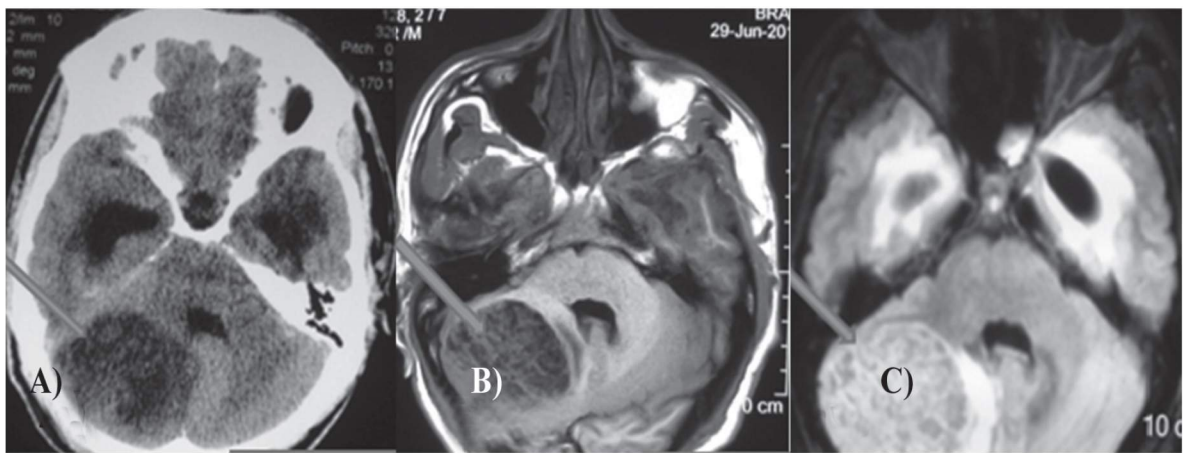


Figure 1: A) Non-Contrast Computed tomography (CT) showing right cerebellar mass (Arrow head), B) T1-weighted MRI and C) MRI FLAIR sequence

having propensity to recur after surgery. It may be focal or diffuse. LDD is associated with phacomatosis and, in 40 % of cases it is associated with Cowden's syndrome, an autosomal dominant neoplastic syndrome characterized by mucocutaneous lesions, systemic hamartomas and malignant neoplastic lesions of the breast, thyroid, genitourinary and gastrointestinal tracts.<sup>9</sup> Generally, MRI with Diffusion and Spectroscopy helps in diagnosing the case preoperatively. We report a similar case of young adult who is diagnosed as Lhermitte-Duclos Disease recently at our institution.

### Case Report

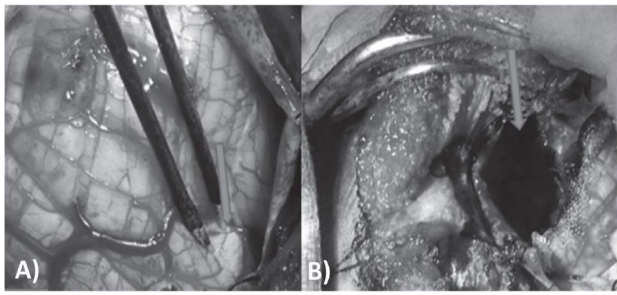
A 31-year-old young right-handed male patient presented to our Neurosurgical Out-Patient Clinic with complaints of recent onset of difficulty in walking as well as balancing, long-standing persistent occipital headache associated with vomiting. On neurological examination, patient showed positive cerebellar signs with ataxia and dysmetria. However, there was no disc edema on fundoscopic examination. CT scan showed features of obstructive hydrocephalus with hypo dense lesion of right cerebellar hemisphere on non-contrast (**Figure 1 A**).

Patient was further investigated with magnetic resonance imaging (MRI) with CSF flow study which revealed approximately 5.6 x 4.6 x 4.4 cm<sup>3</sup> sized mixed signal intensity lesion in the right cerebellar hemisphere in the inferior aspect (**Figure 1, B & C**).

The lesion displayed dominantly low signal intensity in T1-weighted images and heterogeneously high signal intensity in T2 and FLAIR images. Stripe-like signal intensity was noted within the lesion with lobulated outline. Susceptibility-weighted Image (SWI) showed abnormally-dilated and tortuous veins within the lesion.

There was no enhancement of the lesion on the contrast scan. Caudal migration of cerebellar tonsils through foramen magnum was extending downwards up to C2 level, measuring approximately 17 mm in length below the foramen magnum. The 4th ventricle was mildly compressed and displaced. As a part of examination of associated pathology, ultrasonography of the thyroid gland showed 4.6 x 3.6 mm small iso-echoic lesion with hyperechoic halo in the right lobe of thyroid with no calcification. These features were suggestive of thyroid adenomatous nodule. However, abdomen and chest CT scan revealed normal study. Preoperative diagnosis of Lhermitte Duclos syndrome was made; and the patient was subjected to standard suboccipital craniectomy and excision of the tumor.

The patient was kept in prone position on three-pin Mayfield headrest system with back of the head and nape turned slightly to the left and with adequate foam padding. As a safety measure, initially, a burrhole was made at right Dandy's point, using NSK Primado-2 electric drill with burr for perioperative external ventricular drainage in case of dire need. Then, standard suboccipital craniectomy with removal of posterior arch of C1 was performed, using the drill, double-action Lekshell rongeur and Kerrison punch. More occipital squama was removed on the right side exposing the margins of transverse and sigmoid sinus complex. Dura was opened in Y-shaped fashion. After the dural opening, the irregularly thickened and pearly-gray folia of the right cerebellar hemisphere was observed instantly (**Figure 2, A&B**), confirming the preoperative diagnosis. Furthermore, the cerebellar tonsils were found to be pushed downwards and displaced towards the left side. The lesion was encasing the right superficial petrosal vein. The lesion was excised meticulously, sacrificing the right petrosal vein on the superior aspect underneath



*Figure 2: A) Intraoperative picture showing the demarcation between the normal and abnormal folia. (Arrow Head), B) Intraoperative picture after complete excision of the lesion showing the cavity after removal of tumor (Arrow head)*

the tentorium. A gross total resection of this poorly demarcated lesion particularly in the medial and inferior aspects was carried out. A large duroplasty was performed using occipital pericranium which was harvested during exposure. Postoperatively, the patient was managed in ICU and extubated.

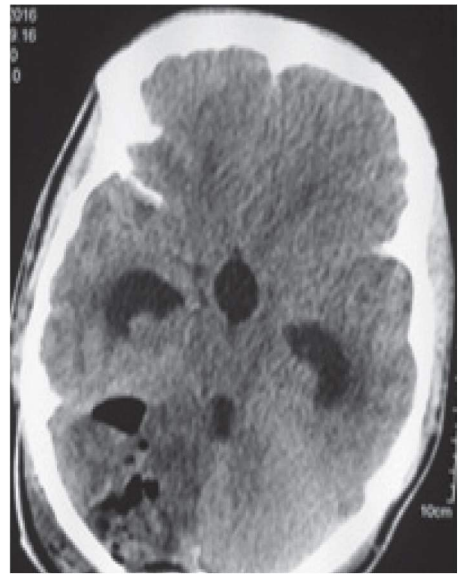On neurological evaluation after surgery, the patient had mild worsening of the cerebellar signs which, however, improved gradually within few days. Postoperative CT scan (**Figure 3**) showed gross total resection of the mass.

Postoperative course was uneventful; and the patient was discharged on postoperative day 16th. Histopathological examination report revealed a cerebellar tissue with Purkinje layer and mild expansion of molecular layer, with early changes of dysplastic gangliocytoma. After surgery, the patient underwent colonoscopy to probe for any colorectal pathology, which showed normal study. No radiotherapy was done postoperatively and the patient was periodically followed up in Neurosurgical Clinic. PTEN genetic analysis was not done due to unavailability.

On follow up, he was stable with Glasgow outcome scale of 5. His cerebellar signs had disappeared. Routine follow-up after one year showed no recurrence of the cerebellar lesion; however, he was found to have bilateral ongoing optic atrophy on fundoscopic examination on Ophthalmology review.

## Discussion

Lhermitte-Duclos disease (LDD) is a rare condition usually affecting patients aged 30-50 years. There is no sex (male to female ratio = 1) or race preference.<sup>2</sup> Lhermitte and Duclos reported the first case of cerebellar ganglion cell tumor in 1920. Exact cause of this disease is still a matter of controversy. Origin of the disease has been postulated as a hamartomatous, neoplastic, or congenital malformative.<sup>2</sup> This is often associated with other anomalies and malformation, like macrocephaly, megacephaly,



*Figure 3: Postoperative Non-contrast CT Head showing pneumocephalus and minimal blood within the right cerebellar hemisphere*

syringomyelia, polydactyly, multiple hemangiomas and mucocutaneous lesions, along with malignancies of thyroid, breast, genitourinary and gastrointestinal tract.<sup>12</sup> It has been found that there is a genetic correlation between LDD and Cowden's syndrome, an autosomal dominant syndrome characterized by a genetic aberration.<sup>9</sup> About 80% percent of patients with Cowden's syndrome have germ line mutations in the PTEN gene at locus 10q23.2, which has been identified as the major susceptibility gene for Cowden's syndrome. Most LDD patients appear to have a germ line loss of the PTEN allele and go on to lose the remaining PTEN allele at some point, thereby allowing abnormal growth of the granule cells.<sup>7</sup>

Patient with LDD usually present with a long-standing history of neurological abnormalities due to gradual expansion of a mass in the posterior fossa.<sup>1</sup> The duration of symptoms range from a few months to more than 10 years on average of approximately one year.<sup>4</sup> In our case, the duration of presentation was short. Patient usually presents with features of other associated anomalies such as polydactyly, hydromyelia, megalencephaly, heterotopia and multiple hemangioma; and, moreover, dysplastic body is also not an uncommon.<sup>13</sup> However, none of these features was found in our case. There are case reports of sudden death due to compensation.<sup>4</sup>

The neuroradiological diagnosis of Lhermitte-Duclos disease had never been suspected preoperatively in early era.<sup>6</sup> With the advent of modern neuro-imaging, it has played an important role in its diagnosis. CT scan however is of limited value. The dysplastic gangliocytoma is hypo attenuated on unenhanced computed tomographic (CT) images. In such cases, the only diagnostic clue may be the

mass effect. There will be no appreciable enhancement of the lesion on contrast-enhanced scan. Conventional MRI with newer sequence like diffusion imaging and spectroscopy, is currently the most useful imaging method which is able to provide a definite diagnosis preoperatively by showing an expansile lesion that is typically hypointense on T1-weighted and hyperintense on T2-weighted sequences.<sup>10</sup> These signal alterations are related to white matter atrophy, thickening of the granule cell layer and enlargement of the cell layers making up the cerebellar cortex as in our case. The mass is characterized by parallel hyperintense striations related to thickening of the cerebellar folia due to enlargement of the cortical cells and dysplasia of the sulci, which are considered pathognomonic signs of LDD. A “tiger-striped” cerebellar lesion with unilateral hemispheric expansion and preservation of the gyral pattern is reported as a specific sign for LDD; and these findings often establish the preoperative diagnosis.<sup>8</sup> Diffusion MR will show a hyperintense area at the level of the lesion, due to the “residual T2-contrast”. In the apparent diffusion coefficient map, the mass appears isointense to the cerebellar parenchyma. MR spectroscopy reveals a typical spectrum of appearance of a lactate peak and reduction in the choline peak.

Histopathological examination reveals derangement of normal laminar cellular architecture of cerebellum with thickening of the outer molecular cell layer and loss of middle Purkinje cell layer and infiltration of inner granular cell layer with dysplastic ganglion cell. Markers of the neoplastic process, such as mitotic activity, necrosis and endothelial proliferation are characteristically absent.<sup>2</sup> No case of malignant transformation has been reported till date. Treatment is still controversial. The natural history of this disorder is not yet well-understood. Surgical excision may be considered when there is mass effect. The slow growth rate of the lesion could allow long term survival despite partial excision.<sup>4</sup> The efficacy of radiation therapy is unknown and is not recommended as an initial treatment. Because of recurrences, radical resection with shunting if necessary is the treatment of choice.<sup>5</sup>

## Conclusion

Lhermitte-Duclos disease is a rare hamartomatous lesion of the cerebellum, mostly occurring in young adults. Histological hallmarks of the disease are thickening and hyper myelination of the outer molecular layer, loss of Purkinje cells and white matter, dysplastic ganglion cells with rounded nuclei and abundant mitochondria invading the inner granular layer. A non-enhancing mass in posterior fossa, hypointense on T1-weighted and hyperintense on T2-weighted images with parallel linear striations

giving a ‘tigroid’ appearance of cerebellum, is considered diagnostic.

## References

1. Ambler M, Pogacor S, Sidman R, Lhermitte-Duclos disease (granule cell hypertrophy of the cerebellum), Pathological analysis of the first familial cases. **J Neuropathol Exp Neuro** **128**: 622-647, 1969
2. Buhl R, Barth H, Hugo HH, et al. Dysplastic gangliocytoma of the cerebellum: rare differential diagnosis in space occupying lesions of the posterior fossa. **Acta Neurochir (Wien)** **145**: 509-512, 2003
3. Di Lorenzo N, Lunardi P, Fortuna A. Granulomolecular hypertrophy of the cerebellum. **J Neurosurg** **60**: 644-646, 1984.
4. Leech RW, Christoferson LA, Gilbertson RL. Dysplastic gangliocytoma of the cerebellum: Case report. **J Neurosurg** **47**: 609-612, 1977
5. Marano SR, Johnson PC, Spetzler RF. Recurrent Lhermitte-Duclos disease in a child. **J Neurosurg** **69**: 599-603, 1988
6. Milbouw G, Born JD, Martin D et al. Clinical and radiological aspects of dysplastic gangliocytoma: a report of two cases with review of the literature. **Neurosurgery** **22**: 124-128, 1988
7. Miller C. Cowden disease (multiple hamartoma syndrome). In: Elmets C, Vinson R, Libow L, Quirk C, James W eds. *EMEDICINE instant access to the minds of medicine*. LU; 2002.
8. Moeninghoff C, Kraff O, Schalamann M, et al. Assessing a dysplastic cerebellar gangliocytoma with 7T MR imaging. **Korean J Radiol** **11**: 244-248, 2010
9. Murray C, Shipman P, Khangure M, et al: Lhermitte-Duclos disease associated with Cowden’s syndrome: case report and literature review. **Australas Radiol** **45**: 343-346, 2001
10. Nagaraja S, Powel T, Griffiths PD, et al. MR imaging and spectroscopy in Lhermitte-Duclos disease. **Neuroradiology** **46**: 355-358, 2004
11. Nowak DA, Trost HA. Lhermitte-Duclos disease (dysplastic cerebellar gangliocytoma): a malformation, hamartoma or neoplasm? **Acta Neurol Scand** **105**: 137-145, 2002
12. Patel S, Barkovich AJ. Analysis and classification of cerebellar malformations. **Am J Neuroradiol** **23**: 1074-1087, 2002
13. Ruchoux MM, Gray F, Gherardi R et al. Orthostatic hypotension from a cerebellar gangliocytoma (Lhermitte-Duclos disease): case report. **J Neurosurg** **65**: 245-252, 1986