

Case Reports

Dipendra Gurung, MBBS, MS
National Trauma centre, Bir Hospital
Kathmandu, Nepal

Binod Sherchan, MBBS, MS
National Trauma centre, Bir Hospital
Kathmandu, Nepal

Nilam Khadka, MBBS, MCh
National Trauma centre, Bir Hospital
Kathmandu, Nepal

Address for correspondence:

Dipendra Gurung, MBBS, MS
National Trauma centre, Bir Hospital
Kathmandu, Nepal
Email: dipendra-gurung@hotmail.com

Received, 11 February, 2017

Accepted, 27 February, 2017

The thoracic spine is the most commonly affected region but gunshot injuries involving the cervical spine are the most devastating of all injuries; such injuries result in the most severe functional impairments.² Spinal cord injuries inflicted by firearms usually result in complete paraplegia.³ This neurological outcome (paraplegia) results from direct trauma brought about by compression of the spinal cord by the bullet to the nucleus, bone fragments, and sometimes disc particles.⁴ The spinal injuries caused by GSW has been classified as type I: transfixing (when small fragments are found inside the canal) type II: intra canal (when the whole projectile is inside the canal) or type III: inter vertebral lesions (when the bullet is inside the inter vertebral disc space; Type III injuries are subdivided into (A) spinal lesion not associated with perforation of abdominal viscera or (B) injury with perforation of abdominal organs. In most cases of GSW the injury is transfixing and only little fragments (altogether <50% of the projectile) remain in the spinal canal. In the second place come cases in which the projectile is lodged inside the canal. Gunshot accidents in the civil

A Case of Bullet Injury of Spine

The incidence of bullet injury of spine depending upon the country is 13-44% in general population. Bullet injury to the spine increases morbidity and mortality. Although a few reports have examined the outcome and its prognosis, most bullet injury would lead to complete neurological deficit. Here we present 30 year old farmer allegedly hit by a bullet presenting with unable to move bilateral lower limbs with urinary incontinence. Radiographic view and CT- scan revealed bullet impinging into the spinal canal at the level of D8-D9. The patient underwent fenestration with central laminectomy with decompression and removal of bullet followed by duroplasty. There were no postoperative complications and although some experts review high complication for surgical intervention we underwent operative intervention for to prevent future deformity and pain.

Key Words: bullet injury, spinal injury, surgical treatment

population therefore involve low-energy firearms and the tissue damage occurs mainly because of the impact from the projectile mass. According to Miller, 0.22, 0.25, 0.32 and 0.38 caliber handguns are indeed the most common. The projectile velocity determines the wounding potential of the weapon however, the energy is not the only factor contributing to tissue damage: the physical properties of the bullets such as design and fragmentation also determine lesion characteristics.

Case Report

A 30-year-old farmer from Bagahi, Parsa presented to our emergency by ambulance on 20th September 2015, A terai riot activist allegedly hit by a bullet of a 3 knot 3 rifle at 2pm on the day of admission. The bullet was fired from close range (distance of 6-8 meter). He fell down after a hit by a bullet and was unable to move his both bilateral lower limbs. He also presented with urinary incontinence while presenting to our emergency. while presenting to emergency Glasgow coma scale was 15/15 and paraplegic

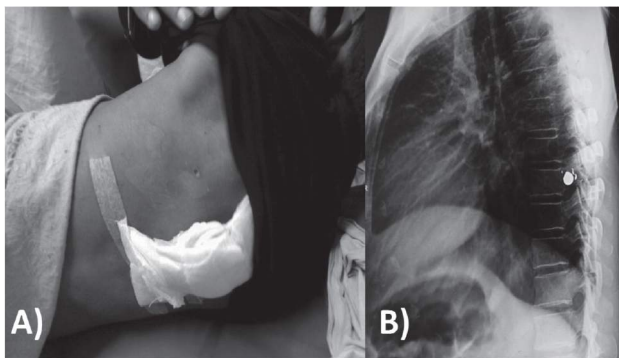


Figure 1: Preoperative pictures, A) penetrating wound, B) X-ray lateral view of thoracic spine, showing the bullet

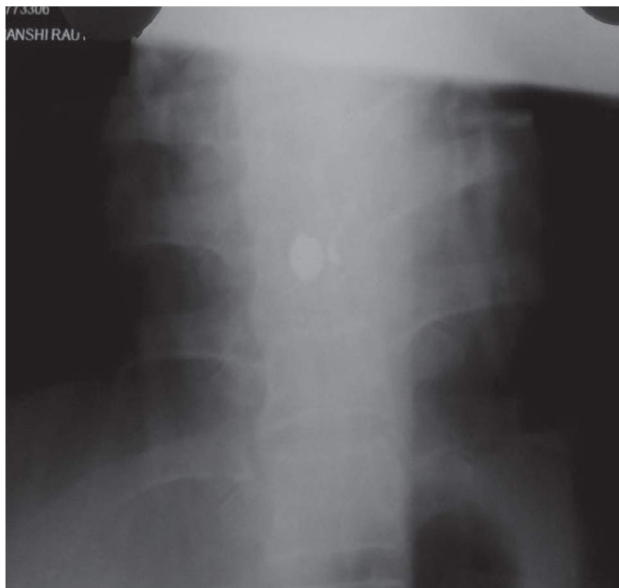


Figure 2: Preoperative X-ray AP view of thoracic spine

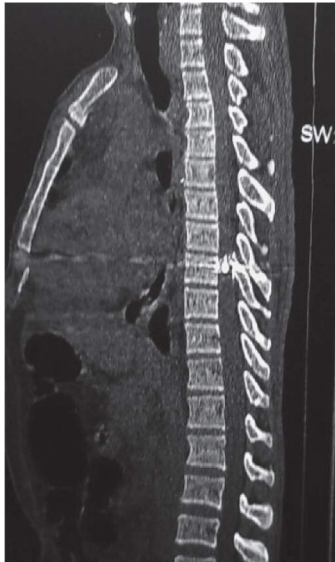


Figure 3: CT scan sagittal view of dorsal spine showing bullet impinging into the spinal canal at the level of D7-D8

both in (Right/left) Grade=0. Bullet entry site wound 1x1cm left para spinal region at the level of inferior angle of scapula was noted. Preoperative radiographs taken (Figure 1, 2, 3) which showed bullet in the spine.

His general examination was done, vitals were stable, paraplegic without anal sensation, bulbocavernous reflex was absent, Hyperesthesia at D8 level with ASIA SCORE as shown in Figure 4.

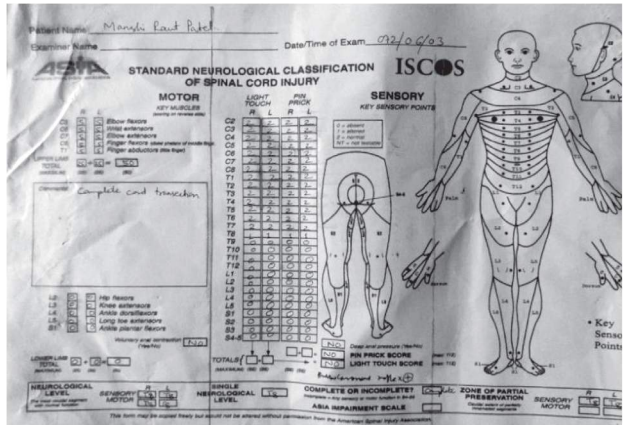


Figure 4: ASIA SCORE (complete transection cord)

Surgical Procedure

An incision given at D7-D8 level, Laminectomy performed, cord decompression done and bullet removed. Duroplasty done and wound was closed (Figure 5 A, B, C).

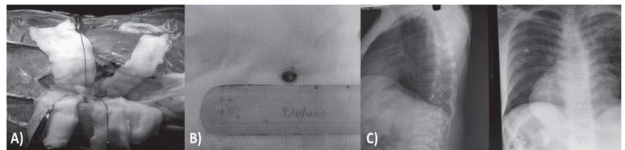


Figure 5: A) laminectomy, decompression and bullet removal with duroplasty, B) bullet size of 1-2 cm in size and around 5 mm in diameter, C) Post operative X-ray of thoracic spine AP and lateral view after removal of bullet

Post operatively patient was stable except pre-operative paraplegia with foley’s catheter in situ.

Discussion

The use of steroids is very controversial. Steroids do not help the primary injury to neurons. Most benefit occurs in the first 8 hours and additional effect occurs within the first 24 hours methyl prednisolone bolus 30 mg/kg then infusion 5.4 mg/kg/h. Infusion is given for 24 hours if bolus given within 3 hours of injury. Infusion is given for 48 hours if bolus given within 3 to 8 hours after injury. There is no benefit if methyl prednisolone started more than 8 hours after injury. There is no benefit with

naloxone, tirilazad etc. In most cases, surgery to remove the bullet does not yield much benefit and may create additional risks including infection, cerebrospinal fluid leak and bleeding. However, occasional cases of gunshot wounds to the spine may require surgical decompression and/or fusion in an attempt to optimize patient outcome. Even if surgery cannot reverse damage to the spinal cord surgery may be needed to stabilize the spine to prevent future pain or deformity. There was no postoperative complications- CSF leakage, infection, pneumonia, pressure ulcer and deep vein thrombosis and bleeding. Currently, there is no cure for SCI. However, ongoing research to test surgical and drug therapies continues to make progress. Drug treatments decompression surgery, nerve cell transplantation, nerve regeneration, stem cells and complex drug therapies are all being examined in clinical trials as ways to overcome the effects of SCI. Currently, there is no cure for SCI. However, ongoing research to test surgical and drug therapies continues to make progress. Drug treatments decompression surgery, nerve cell transplantation, nerve regeneration, stem cells and complex drug therapies are all being examined in clinical trials as ways to overcome the effects of spinal cord injury.

References

1. Araújo Júnior FA, Heinrich CB, Cunha MLV, Veríssimo DCA, Rehder R, Pinto CAS. Spinal cord trauma by a firearm projectile: epidemiological assessment. **Columna** 10: 290–292, 2011
2. de Barros Filho TEP, Oliveira RP, Barros EK, Von Uhlendorff EF, Iutaka AS, Cristante AF. Gunshot wounds of the spine: epidemiological study. *Coluna* 1, 2002
3. Farmer JC, Vaccaro AR, Balderston RA, Albert TJ, Cotler J. The changing nature of admissions to a spinal cord injury center: violence on the rise. **J Spinal Disord** 11: 400–403, 1998
4. Miller CA. Penetrating wounds of the spine. In: Wilkins RH, Rengachary SS, *Neurosurgery* vol. 1. McGraw-Hill: San Francisco. 1985 pp 1746–1748.
5. Rao PM, Ivatury RR, Sharma P, Vinzons AT, Nassoura Z, Stahl WM. Cervical vascular injuries: a trauma center experience. **Surgery** 114: 527–531, 1993