

Anish M Singh, MS

Department of Neurosurgery
B&B Hospital, Gwarko
Lalitpur, Nepal

Prabin Shrestha, MD, PhD

Department of Neurosurgery
B&B Hospital, Gwarko
Lalitpur, Nepal

Address for Correspondence:

Prabin Shrestha, MD, PhD
Department of Neurosurgery
B&B Hospital, Gwarko
Lalitpur, Nepal

Email: prabinshrestha@hotmail.com

Received, 21 July, 2017

Accepted, 11 July, 2017

Hangman's fracture, also known as traumatic spondylolisthesis of Axis (C2), is a common fracture of cervical spine occurring during any road traffic accident (RTA). It is usually caused by hyperextension of the spine and axial load on the C2.^{1,2,3}

Here we present 42-year-old male presented with neck pain and difficulty in neck movement since few days back. There was a history of RTA, fall from bike and blunt head injury about 1 month before his presentation. His CT scan of head was normal. Neurologically he was stable, could walk normally and his hand movement and hand grip were normal. His X-Ray of cervical spine showed typical hangman fracture at C2-3 level and anterior angulation deformity of the spine. CT and MRI of cervical showed the same finding without any significant injury to the cord (**Figure 1 A-C**). He was planned for surgical management. Cervical spine traction was fixed with 3 kg weight to immobilize the spine and to reduce the fracture. Next day surgery was done from posterior approach. With midline incision occiput and uppercervical spine was exposed. C3-4 fixation was done with lateral mass screw, autologous bone graft was put in the screw entry site. Since there was instability at C3-4 junction also lateral mass screw were placed in C4 also. The whole procedure was performed by free-hand technique and was confirmed by C-arm X-Ray at the end of surgery. Post-operative X-Ray showed the perfect alignment of upper cervical spine with lateral mass screw in situ at C2-4 (**Figure 1 D**). patient was neurologically intact post-operatively.

Hangman's Fracture and Its Management

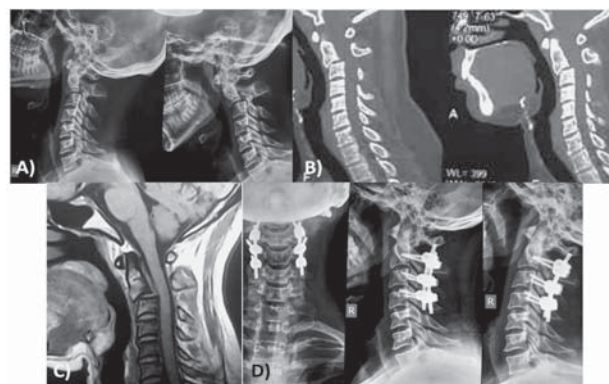


Figure 1: Radiological images, A) preoperative dynamic X-Ray of cervical spine showing hangman fracture of C2-3, B) CT scan of cervical spine, C) T1W MRI of cervical spine, D) post-operative X-Ray of cervical spine

Hangman's fracture is the second most common fracture of cervical spine after odontoid fracture. It is so named as Hangman's fracture as it resembles the spinal injury caused by judicial hanging.

This injury is defined as bilateral avulsion of the neural arches from the vertebral body, with or without subluxation. The fracture is through the pars interarticularis of C2 or through the adjacent portion of the articulating facet.

The pars interarticularis is the site of fracture in traumatic spondylolisthesis, not the pedicles or lateral masses, as is commonly stated.

Surgical management is the choice whenever there is significant listhesis as in our case.^{2,3} however, at times there can be fracture with insignificant displacement or listhesis which can be managed conservatively with rigid cervical collar.¹

References

1. Alexander John Scumpia, Daniel Michael Aronovich, Megan Dekok, Katrina Lopez, Donny Perez. A case of acute hangman's fracture. **Journal of Acute Disease** 5: 337-339, 2016
2. Dong Hwan Jeong, Nam Kyu You, Chul Kyu Lee, Ki Hong Cho, Sang Hyun Kim. Posterior C2-C3 Fixation for Unstable Hangman's Fracture. **Korean J Spine** 10: 165-169, 2013
3. Rafid Al-Mahfoudh, Christopher Beagrie, Ele Woolley et al. Management of Typical and Atypical Hangman's Fractures. **Global Spine J** 6: 248-256, 2016