

Case Report

Sil Kaushik, DNB

Medical Institute of Neurological Diseases
Medical Superspeciality Hospital
Kolkata, India

Basu Sunanadan, FRCS

Medical Institute of Neurological Diseases
Medical Superspeciality Hospital
Kolkata, India

Jain Harsh, FRCS

Medical Institute of Neurological Diseases
Medical Superspeciality Hospital
Kolkata, India

Tripathy Laxminarayan, MCh

Medical Institute of Neurological Diseases
Medical Superspeciality Hospital
Kolkata, India

Address for Correspondence:

Sil Kaushik, DNB
Medical Institute of Neurological Diseases
Medical Superspeciality Hospital
Kolkata, India
Email: kaushikneuro@gmail.com

Received, 19 February, 2015

Accepted, 10 March, 2015

Hydatisosis is a parasitic disease endemic in many parts of the world. Dog is a definitive host and ruminants like Sheep are the intermediate hosts. Accidental infection in man occurs due to contact with the domesticated definitive host or through consumption of contaminated vegetables. Brain infection with Hydatid cyst is rare and occurs in instances where there is loss of capillary filter of liver and lungs. We report a case of multiloculated intracranial hydatid cyst having an indolent course over 30 years, which presented with seizures and an unusual radiology and gross pathological features.

Case Report

A 53-year-old male patient, butcher by profession, from hilly area presented with history of exacerbation of seizures over last few months. The seizures started at the age of 16 years and had been managed with anti-epileptic medication (Phenyton). These seizures were mainly left focal in nature with occasional generalizations. Recently he had some weakness and paraesthesia of left leg and also experiencing headaches.

Multicystic Cerebral Hydatid Cyst: Uncommon Presentation of A Rare Disease

Hydatid cyst is a common zoonosis, affecting the liver and lungs in the endemic areas. Occasionally it involves the brain.

We present a rare case of multicystic cerebral Hydatid cyst present over a long time in an adult patient with some odd radiological features like calcification and discuss the relevant literature.

In endemic areas, neurosurgeons must be aware of this entity.

Key Words: cerebral cyst, hydatid cyst, zoonosis

On examination patient was found to have Grade 3/5 hemiparesis on the left side and also right sided hemianopia.

CT scan (**Figure 1**) done recently showed multiloculated cystic lesions in right parieto-occipital region with calcifications. T2 image on MRI shows (**Figure 2**) irregular peripherally enhancing multiple cysts extending upto but not encroaching the ependymal lining of the lateral ventricles on the right side. Compression of the right lateral ventricles along with midline shift and mild ventriculomegaly on the left is evident on both CT and MRI.

Intraoperatively, the solid calcified lesion was attached to the dura. Multiple cysts were attached to that lesion and extended deep down into the basal cisterns. The cyst walls were friable containing yellow hydatid sands and at the depth the cysts were adherent to the cisternal vessels. Total excision was done taking care not to spill the cyst (**Figure 3**). Hydatid cyst was confirmed on histopathology.

Postoperatively patient was started on Albendazole 10mg/kg per day twice daily for 4 months.

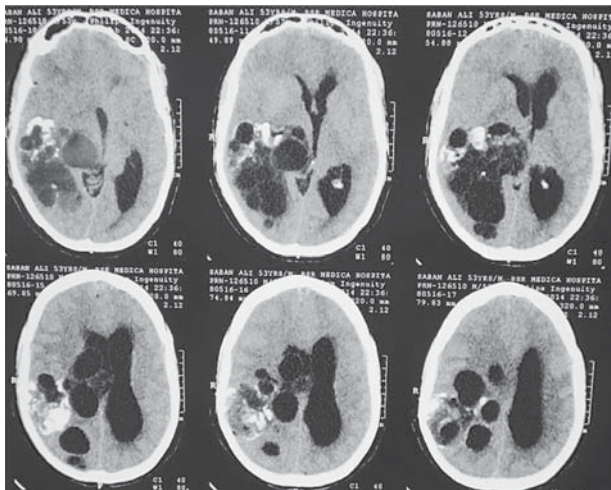


Figure 1: CT scan showing multiloculated cysts with calcified component

Discussion

Hydatid disease is a zoonosis in which a carnivore is a definitive host and adult worm lives in its intestine. The worms release eggs in the feces which are ingested by the intermediate host, usually a sheep during grazing. The embryo then passes into the liver of the intermediate host and stays there. Man becomes infected only after contact with the intermediate or definitive host or by consuming contaminated vegetable, water or meat. Liver and lungs are the most common site of hydatid disease. Spread to the brain occurs in only about 2-3% cases due to embolization through the middle cerebral artery.² The cyst displaces the soft brain tissue and consequently intracranial pressure is not increased until late stage. The usual presentations are with headache and symptoms localized to the particular site of brain. Minority of patients have seizures. Usually cranial hydatid cysts are solitary. Multiple cerebral cysts occur as a result of rupture of primary cyst or embolization from a ruptured peripheral cyst or very rarely from ingestion of multiple larvae.⁴

CT scan usually has been described as very rounded isodense lesion with no peripheral enhancement and pericystic edema. In MRI the lesions usually show T1 hypo-intensity, T2 ring hyper intensity with fine peripheral contrast enhancement.^{3, 6} Alveolar hydatid cysts however present as cystic lesions with contrast enhancement and calcification.⁵

Surgical treatment includes total excision of the cyst. Surgery is difficult in cases of multiloculated, deep seated and thin walled cysts. The challenge is to deliver the cyst

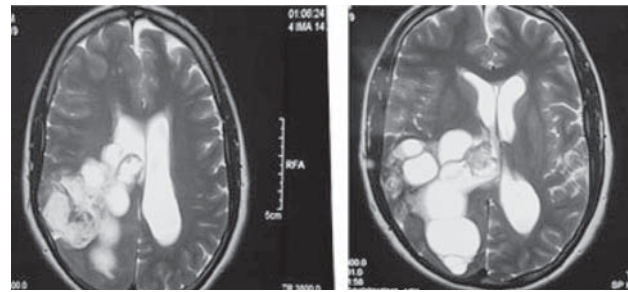


Figure 2: MRI showing cystic lesion extending from the brain surface to ventricular wall




Figure 3: Peroperative pictures showing a) dural attachment, b) hydatid sand and c) hydatid cyst.

without rupture from the surrounding brain parenchyma and also to avoid spillage in case of accidental rupture. Usual method is to do a warm saline aided extra capsular dissection (Dowling's technique).¹ All adhesions must be released before delivery of cyst. To prevent spillage, the brain must be protected with liquid antiseptic (commercially available composition of Chlorhexidine Gluconate 0.3% & Cetrimide 3.0%) soaked cotton patties. Inadvertent rupture can produce severe anaphylaxis leading to hyperpyrexia, cerebral edema, cardiopulmonary arrest. The large cavity left after operation can lead to subdural hemorrhage, hydrocephalus, pneumocephalus, and seizures.

Albendazole with steroid cover is the medical treatment of choice. It should be continued for at least 4 weeks.

Our patient is a butcher by profession and had pet dogs, which probably increased his chance of being an accidental host. He lives in high altitude, where alveolar form of hydatidosis is commoner than pastoral form. Our case is unique because the radiological findings of multiple solid cystic lesions, dural attachments, calcification is very rare. Adhesions with deep cisternal and ventricular structures made it difficult for safe surgical excision.

Conclusion

Cerebral hydatid cyst is a rare entity requiring surgical intervention. Radiology may be inconclusive at times. High index of suspicion especially in endemic is required to diagnose and take necessary pre-operative precautions. Medical treatment is required to check remission.

References

1. Carrea R, Dowling E Jr, Guevara JA. Surgical treatment of hydatid cysts of the central nervous system in the pediatric age (Dowling's technique). **Childs Brain 1:** 4-21, 1975
2. Danziger J, Bloch S. Tapeworm cyst infestations of the brain. **Clin Radiol 26:**141-148, 1975
3. Duishanbai S, Jiafu D, Guo H, Liu C, Liu B, Aishalong M, et al. Intracranial hydatid cyst in children: Report of 30 cases. **Childs Nerv Syst 26:** 821-827, 2010
4. Gana R, Skhissi M, Maaqili R, Bellakhdar F. Multiple infected cerebral hydatid cysts. **J Clin Neurosci 15:** 591-593, 2008
5. Tunaci M, Tunaci A, Engin G, Ozkorkmaz B, Ahishali B, Rozanes I. MRI of cerebral alveolar echinococcosis. **Neuroradiology 41:** 844-846, 1999
6. Wani NA, Kousar TL, Gojwari T, Robbani I, Singh M, Ramzan A, et al. Computed tomography findings in cerebral hydatid disease. **Turk Neurosurg 21:** 347-351, 2011