

Case Report**Ram Kumar Shrestha, MS**Neurosurgery Unit
Department of Surgery
TU Teaching Hospital
Kathmandu, Nepal**Mohan Raj Sharma, MS**Neurosurgery Unit
Department of Surgery
TU Teaching Hospital
Kathmandu, Nepal**Gopal Sedain, MS, MCh**Neurosurgery Unit
Department of Surgery
TU Teaching Hospital
Kathmandu, Nepal**Address for Correspondence:**Mohan R. Sharma, MS
Department of Surgery
TU Teaching Hospital
Kathmandu, Nepal
Email: mohanrajsharma@gmail.com**Received,** December 4, 2014**Accepted,** January 15, 2015

The incidence of organized or calcified CSDH is only 0.5-2%.^{1,6} Formation of SDH or effusion following VP Shunting is commonly encountered in neurosurgical practice.^{4,7} These hematomas are due to over drainage following Cerebrospinal Fluid (CSF) diversion procedures. If recognized in time, these patients can be managed with upgrading of the shunt valve into high-pressure valve. However, in patients who fail to follow up regularly, these may progress to an organized hematoma and lead to significant mass effect requiring craniotomy and evacuation.^{1,4} We report a case of organized CSDH who presented with seizure after three and half year following VP shunting. The child was neglected despite the delay in developmental milestone.

Case History

This 4-year-old female child presented to the Emergency Department of our hospital following an episode of generalized seizure. She had undergone VP Shunting (medium pressure Chhabra slit and spring, Surgiwear, India) at the age of four months for congenital aqueductal stenosis. However, the patient was lost to follow up after surgical intervention. At presentation she is alert and moving all the limbs. The child had delayed

Organized Chronic Subdural Hematoma Following Ventriculoperitoneal Shunt: A Case Report

Subdural Hematoma (SDH) or effusion following Ventriculoperitoneal (VP) shunt for hydrocephalous is not an unusual complication. However, we rarely come across organized chronic subdural hematoma (CSDH) following shunts. We present a case of organized CSDH in a four-year-old female child who presented with seizure three and half year after the VP Shunt placement for obstructive hydrocephalus due to aqueductal stenosis. The child was managed with craniotomy and evacuation of hematoma with membranectomy. We report this unusual case and review the relevant literature.

Key Words: craniotomy, membranectomy, organized chronic subdural hematoma, VP shunt

developmental milestone. She could sit with support and speech consisted of monosyllables only. CT head revealed right frontal hypodense collection with focal calcification and left frontoparietal heterogenous collection with features of mass effect and significant midline shift towards the right side. The shunt tip was seen in situ and the ventricles were slit-like (**Figure 1**). The provisional diagnosis was shunt over drainage leading to CSDH, with organized hematoma due to delay in diagnosis and management.

The patient underwent a left parietal burr hole, however due to the nature of the hematoma it was subsequently converted to a frontoparietal craniotomy. The dura mater was found thick and tightly adherent to the outer membrane of the organized hematoma. Incision of the membrane revealed the contents of the hematoma, which included liquefied hematoma with an appearance similar to machinery oil and a solid component similar to golden yellowish colored scrambled egg appearance (**Figure 2**). These findings were suggestive of repetitive hemorrhage and chronicity. The lesion was removed completely. The inner membrane was approximately 3 mm thick and encasing the brain tightly. Inner membranectomy was done meticulously and brain was made free from

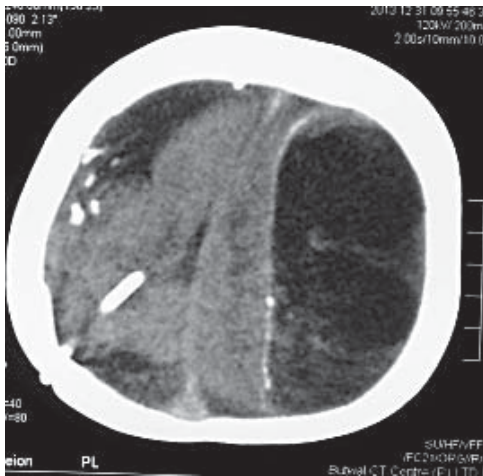


Figure 1: CT scan showing the shunt tip in situ and the ventricles were slit-like

these tight enclosing membrane (**Figure 3**). No other abnormality, including vascular malformations were noted in the hematoma cavity or in the exposed brain surface. The cavity was filled with normal saline and dura was closed in a watertight fashion. Smaller right frontal subdural hematoma was left as it is, as it was not causing any mass effect.

The patient tolerated the surgery well. She was discharged on the 7th post operative day after a CT Scan which revealed some expansion of the compressed brain (**Figure 4**).

Discussion

CSDH following VP Shunting is uncommon but not a rare entity.^{1,4,6,7} Difficulties in noticing the subtle signs of this condition maybe masked in children and lead to delay in diagnosis and consequently lead to organization of hematoma. Only the striking symptoms such as seizure bring forth these patients to medical attention, which is the case for parents from rural areas of developing countries like Nepal. This is in turn worsened by the difficult accessibility to medical care in many parts of Nepal. Hence, these conditions go unnoticed and patient present late in their clinical course as our patient. Other factors for delayed management maybe due to negligence in part of the parents and lack of subspecialty medical facility in the rural areas of developing countries.

The pathogenesis of the formation and development of CSDH is still a matter of discussion. Pathophysiologic processes, such as inflammatory reaction, formation of neomembrane and liquefaction of blood have been implicated.³ Chronic SDH may completely organize depending upon the time lapse, and may sometime even calcify completely giving rise to a condition termed armored brain or “Matrioska” head (Russian doll).⁹

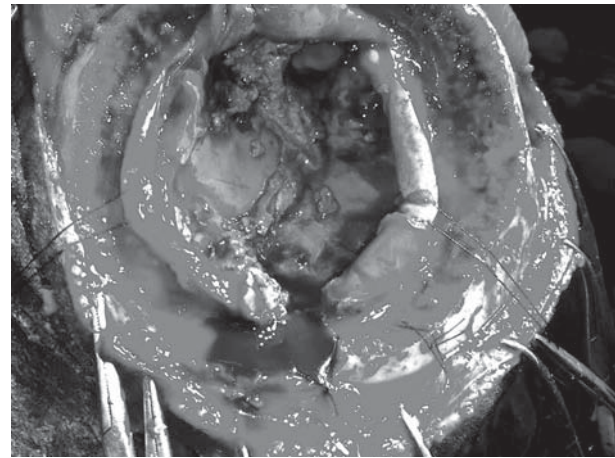


Figure 2: Intraoperative picture showing contents of the hematoma, which included liquefied hematoma with an appearance similar to machinery oil and a solid component similar to golden yellowish colored scrambled egg appearance

The clinical presentation can range from asymptomatic to those with signs of intracranial hypertension, seizure, delayed developmental milestone or even herniation.² CT head is the primary modality for diagnosis of this condition.⁵

The CSDH can be evacuated via small twist drill or burr holes, with or without the placement of a subdural drain. The craniotomy is generally accepted as the optimum approach when CSDH is organized or calcified as in armored brain as burr holes usually fail to evacuate the solid component.⁹ Furthermore the thick membrane trapping the brain needed to be excised.

Chronic SDH has been reported time and again following over drainage of VP shunting. However progression to organized CSDH may be prevented by early recognition with regular follow-up and timely revision of the VP Shunt.

Shigeki, et al. reported that removal of an organized CSDH with calcification usually failed with a burr hole procedure and good results can be obtained by means of craniotomy.¹⁰ In our case though not calcified, the organized solid component eluded the burr hole drainage.

Endoscopic removal of organized CSDH has recently been developed with good results. Although it provides easy access to virtually the entire hematoma cavity under local anesthesia using a keyhole concept, membranectomy using endoscopic approach maybe difficult and is found to have steep learning curve.⁸

Due to negligence and delay in recognition, such complications that can be readily treated with simple procedures now requires a major procedure such as craniotomy with increase in morbidity and mortality.

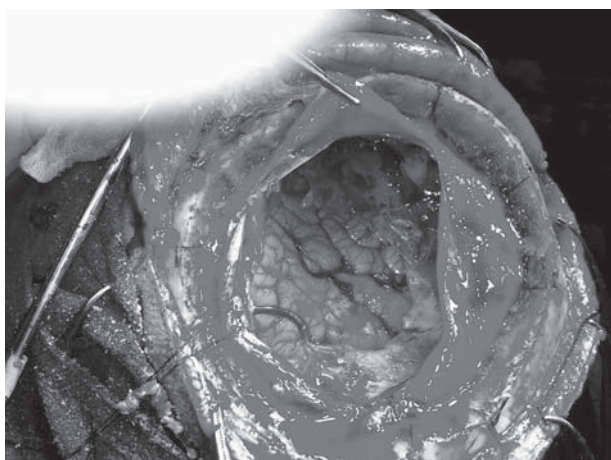


Figure 3: Intraoperative picture showing brain made free from these tight enclosing membrane

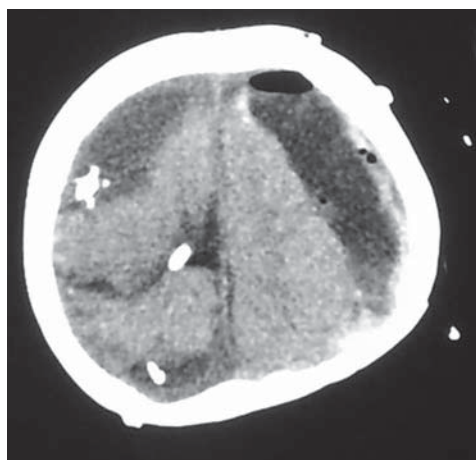


Figure 4: Post OP CT Scan which revealed some expansion of the compressed brain

Key Messages : Delay in diagnosis of chronic subdural hematoma can lead to organization of the hematoma requiring craniotomy which could have been readily treated with minimal intervention like burr hole drainage. Hence, in patients undergoing VP shunt, they should be kept under regular follow up to detect beforehand the organization of hematoma.

References

1. Al Wohaibi M, Russell N, Al Ferayan A: A baby with armoured brain: **CMAJ** **169**:46-47, 2003
2. Dammers R, terLaak-Poort MP, Maas AIR: Armoured brain: Case report of calcified chronic subdural hematoma. **J Neurol Neurosurg Psychiatry** **78(5)**: 542-543, 2007
3. Hideki M, Yuichi H, Masachika S, Kazuhiro S, Masaru K, Kazuhiro G, et al: Why do chronic subdural hematomas continue to grow slowly and not coagulate? Role of thrombomodulin in the mechanism. **J Neurosurgery** **96**: 877-844, 2002
4. Imaizumi S, Takehide O, Kameyama M, Naganum H: Organised chronic subdural hematoma requiring craniotomy; five case reports. **Neurol Med Chir (Tokyo)** **41**:19-24, 2001
5. Ludwig B, Nix W, Lanksch W: Computed tomography of the "armored brain". **Neuroradiology** **25**:39-43, 1983
6. Munro D: Cerebral subdural hematomas in childhood. **J Neurosurg** **24**: 648-655, 1966
7. Papanikolaou PG, Paleologos TS, triantafyllou TM, Chatzidakis EM: Shunt revision 33 years in a patient with bilateral calcified chronic subdural hematoma. **J Neurosurg** **108**: 401, 2008
8. Rodziewicz GS, Chuang WC: Endoscopic removal of organized subdural hematoma. **Surg Neurol** **43**: 569-573, 1995
9. Sgaramella E, Sotgiu S, Miragliotta G, FotiosKalfasCrotti FM: "Matrioska head". Case report of calcified chronic subdural hematoma. **J Neurosurg Sci** **46**: **28-31**: discussion 31, 2002
10. Shigeki I, Takehide O, Motonobu K, Hiroshi N: Organized chronic subdural hematoma requiring craniotomy-five case report. **Neurol Med Chir** **41**: 19-24, 2001