

Shristi Bajracharya, MBBS, MD

Department of Pediatrics
International Friendship Children Hospital
Kathmandu, Nepal

Prabin Shrestha, MD, PhD

Department of Neurosurgery
Norvic International Hospital
Kathmandu, Nepal

Anish M Singh, MS

Department of Neurosurgery
Norvic International Hospital
Kathmandu, Nepal

Reshma Shrestha, MBBS, MD

Department of Anaesthesiology
International Friendship Children Hospital
Kathmandu, Nepal

Shanta C Shakya, MD, PhD

Department of Pediatrics
International Friendship Children Hospital
Kathmandu, Nepal

Address for correspondence:

Shristi Bajracharya, MBBS, MD
Department of Pediatrics
International Friendship Children Hospital
Kathmandu, Nepal

Email: bajra_shristi@yahoo.com

Received, 12 Jun 2015

Accepted, 22 Jun, 2015

A Case of Primary Intraventricular Brain Abscess in a Child: A Challenge to Conquer

Primary intraventricular brain abscess is a rare entity. Not many cases are reported yet. Moreover, proper guidelines for the treatment, conservative treatment or surgery, has not yet been established. Its outcome is also unpredictable and usually poor.

We present a 11-year-old girl with wide spread intraventricular brain abscess. There was no obvious cause for the abscess formation. Cardiac status was normal by history and ECHO. She was treated surgically with external ventricular drainage (EVD). There was significant improvement after EVD. Intraventricular flushing was done with the solution of injection Gentamycin and hydrocortisone. However, the patient expired while planned for discharge from the hospital due to sudden cardiac arrest.

A bigger study is needed to assess the various factors of intraventricular brain abscess including epidemiology, treatment, outcome etc in the Nepalese context.

Key Words: intraventricular brain abscess, outcome, surgical treatment

Primary intraventricular (IV) brain abscess is a rare entity. Not many cases are reported yet. Usually IV brain abscess results from rupture of intraparenchymal brain abscess into the ventricle. However, brain abscess primarily located inside the ventricular system only is rarely found.

It can also be occasionally due to intracranial tuberculosis. Congenital cyanotic heart disease is also responsible for intraventricular abscess at times.¹

Moreover, proper guideline for the treatment, conservative treatment or surgery, has not yet been established. Its outcome is also unpredictable and usually poor. Here we present a case of primary IV brain abscess with great difficulty in its treatment.

Case Report

A 11-year-old girl came with a complain of cough and cold since 15 days which was gradually progressive. It was associated with swelling of left side of face with ear discharge for 12 days. She also had neck pain and fever for the same period and altered sensorium since 1 week ago. There were no history of rashes, seizure and vomiting. There was also no history of any congenital heart disease. Neurological examination showed neck rigidity with coma scale (GCS) of about 7/15, pupils were constricted but equal and reactive to light on both sides. There was no other focal motor deficit but planter reflexes

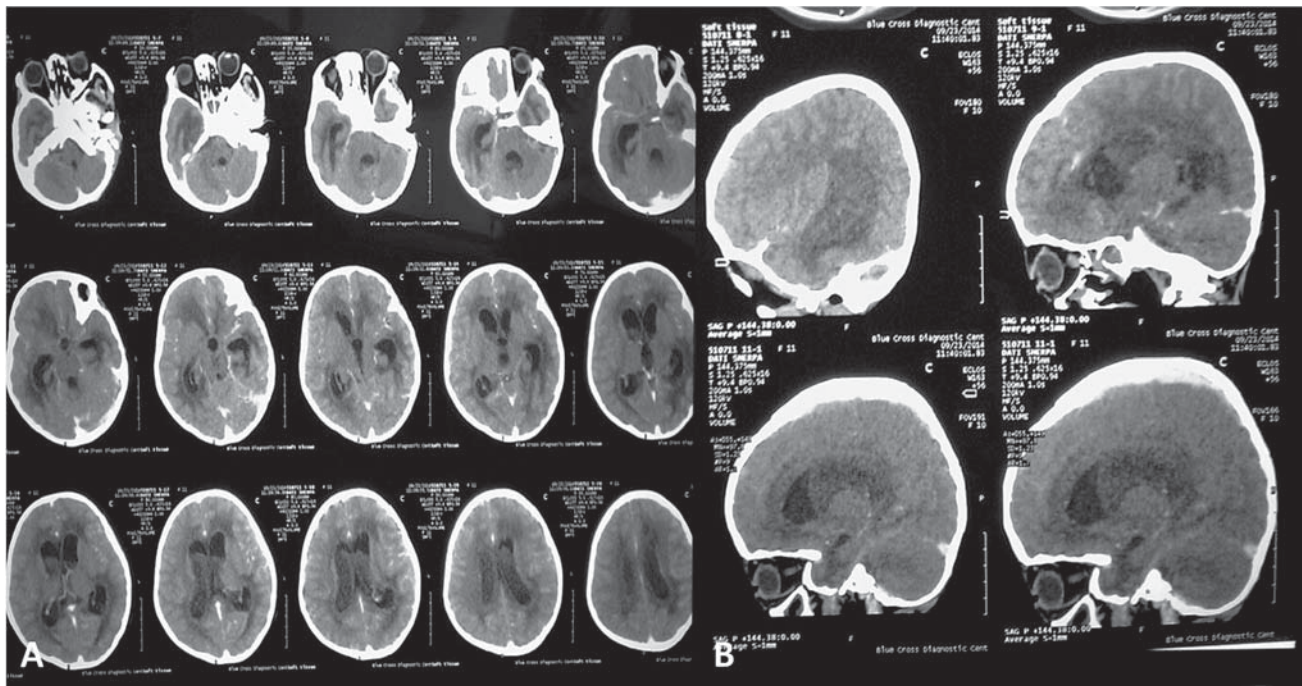


Figure 1: CT scan of brain A) Axial B) Sagittal, with contrast showing isodense mass in bilateral lateral ventricles more on posterior horns, i.e. in dependent part sparing frontal horns suggesting liquid i.e. abscess

were bilaterally up going. ENT examination showed left ear discharge suggesting chronic otitis media.

CT scan of brain revealed meningeal enhancement mainly tentorium cerebelli posteriorly and at skull base suggesting meningitis. There was non enhancing isodense lesion within bilateral lateral ventricles associated with non obstructive, communicating type of hydrocephalous. Intraventricular abscess (IVA) was suspected (**Figure 1**). There was significant peri ventricular lucency suggesting high intra cranial pressure (ICP). Mucosal thickening in both the maxillary and ethmoidal sinuses was also noted. Though there was some sclerotic changes in mastoids, there was no other significant focal lesion in brain parenchyma and other intracranial spaces. Chronic otitis media and mastoiditis bilaterally were suspected depending on CT findings and clinical features.

External ventricular drainage of the IVA abscess was planned. Burr hole was made and Dandi canula inserted in the right frontal horn. As expected thick pus came out of pressure. Due to thick pus 8 F feeding tube was inserted in right ventricle through which free flow of pus was noted. Thorough irrigation with Gentamycin solution was done. Drain was continued for few days. Pus culture was sent. She was kept under intravenous antibiotics and daily irrigation of intraventricular space done with Inj Gentamicin and Inj Hydrocortisone. She made gradual improvement over few days time. On 7th post operative day GCS improved

to 11/15. Since the child was improving gradually, she was planned for discharge. In the mean time on 13th post operative day, she went to sudden cardiac arrest and she died.

Discussions

Primary IVA is not common as has been already mentioned. Intraparenchymal brain abscess is the most common source of intraventricular brain abscess.⁸ There was no other intracranial infective lesion, neither was there any other obvious extracranial source of infections in our case. Though congenital heart disease, middle ear infection, dental infection, trauma etc can be suspected as a causative factor.^{1,2,3} Left ear discharge with otitis media was the only doubtful culprit in our case.

Another causative factor for IV brain abscess can be pyogenic or tubercular meningitis which can transmit the infection into the IV space⁷ which was not evident in our case.

Diagnosis can be occasionally difficult. CT and MRI both if available can give more information than only one of them.⁷ In our case, there was only CT available on the basis of which IVA was almost confirmed without much doubt.

Any treatment, conservative or surgical, for IV brain abscess may not be able to give complete cure^{4,8}

Bajracharya et al

and ultimate prognosis is poor. Though conservative management can be initially started, ultimately surgical drainage and evacuation followed by ventriculo-peritoneal shunting is the definite mode of treatment.^{5,6} We planned for intraventricular drainage of the abscess preoperatively and as planned it was brain abscess coming out under pressure. Through irrigation was done during and after surgery regularly.

Literature also suggests intrventricular antibiotic administration and irrigation is helpful to fight IV brain abscess.⁶

Despite all our effort and despite the fact that the child was improving, suddenly she has cardiac arrest, the cause of which remained unknown.

In conclusion, IVA is not that difficult to recognize in CT or MRI. Timely intervention is mandatory. Despite all the effort, outcome may not be favorable.

References

1. Fernández PB, Suárez JP, Messing-Jünger AM. Case-based update: primary intraventricular brain abscess in a 10-year-old child. **Childs Nerv Syst**, 2015
2. Gadgil N, Chamoun RB, Gopinath SP. Intraventricular brain abscess. **J Clin Neurosci** **19**: 1314-1316, 2012
3. Goto Y1, Sasajima H, Aita K, et al. Munchausen syndrome, a factitious injury, presenting brain abscess and intraventricular hemorrhage: a case report. **No Shinkei Geka** **39**: 381-386, 2011
4. Helweg-Larsen J, Astradsson A, Richhall H, Erdal J, Laursen A, Brennum J. Pyogenic brain abscess, a 15 year survey. **BMC Infect Dis** **12**: 332, 2012
5. Inamasu J, Kuramae T, Tomiyasu K, Nakatsukasa M. Fulminant ependymitis following intraventricular rupture of brain abscess. **J Infect Chemother** **17**: 534-537, 2011
6. Inamasu J, Moriya S, Kawazoe Y, Nagahisa S, Hasegawa M, Hirose Y. Primary Intraventricular Brain Abscess Resulting in Isolated Dilation of the Inferior Horn and Unilateral Hydrocephalus. **Case Rep Neurol** **7**: 156-161, 2015
7. Singh P, Paliwal VK, Neyaz Z, Srivastava AK, Verma R, Mohan S. Clinical and magnetic resonance imaging characteristics of tubercular ventriculitis: an under-recognized complication of tubercular meningitis. **J Neurol Sci** **342**: 137-140, 2014
8. Tunthanathip T, Kanjanapradit K, Sae-Heng S, Oearsakul T, Sakarunchai I. Predictive factors of the outcome and intraventricular rupture of brain abscess. **J Med Assoc Thai** **98**: 170-180, 2015