

## Surgical Treatment of Tardive Dystonia in Nepal: A Case Report

Tardive dystonia is a subtype of dystonia which is seen in patients receiving antipsychotic treatment for long period. Medical treatment of tardive dystonia is very complex and many cases do not respond well to currently available treatment and sometimes can be irreversible. Surgical treatments like pallidotomy and Deep Brain Stimulation (DBS) have shown some promising results. We report this case of Tardive Dystonia who benefitted from Pallidotomy. We believe this is the first case in Nepal.

**Key Words:** deep brain stimulation, pallidotomy, tardive dystonia

### Case Report

**Resha Shrestha, MBBS, MS**

Department of Neurosurgery  
Annapurna Neurological Institute and Allied Sciences  
Maitighar, Kathmandu, Nepal

**Takaomi Taira, MD PhD**

Department of Neurosurgery  
Tokyo Womens Medical University, Tokyo, Japan

**Pranaya Shrestha, MBBS, MS**

Department of Neurosurgery  
Annapurna Neurological Institute and Allied Sciences  
Maitighar, Kathmandu, Nepal

**Pravesh Rajbhandari, MBBS, MS**

Department of Neurosurgery  
Annapurna Neurological Institute and Allied Sciences  
Maitighar, Kathmandu, Nepal

**Sudan Dhakal, MBBS, MS**

Department of Neurosurgery  
Annapurna Neurological Institute and Allied Sciences  
Maitighar, Kathmandu, Nepal

**Samir Acharya, MBBS, MS**

Department of Neurosurgery  
Annapurna Neurological Institute and Allied Sciences  
Maitighar, Kathmandu, Nepal

**Basant Pant, MD PhD**

Department of Neurosurgery  
Annapurna Neurological Institute and Allied Sciences  
Maitighar, Kathmandu, Nepal

**Address for Correspondence:**

Resha Shrestha, MBBS, MS  
Annapurna Neurological Institute and Allied Sciences  
Maitighar, Kathmandu, Nepal  
**Email:** reshkums@hotmail.com

**Received,** 17 December, 2015

**Accepted,** 29 December, 2015

**D**ystonia is a movement disorder characterized by repetitive involuntary sustained muscle contraction resulting in bizarre posture which may eventually become fixed.<sup>10</sup> Tardive dystonia has been considered a late-onset subtype of dystonic reaction in which there is hypertonicity of the muscles and it is seen in patients who have been receiving antipsychotic treatment for a prolonged period. It is a rare kind of movement disorder with the estimated prevalence of 2.1%-5.3%.<sup>12</sup>

The clinical features of tardive dystonia are usually divided into four categories: 1) focal (only a single body part affected), 2) segmental (two or more segments of a body part), 3) multifocal (two or more non-contiguous

body parts) and 4) generalized (combined involvement of at least one leg, trunk and body part).<sup>2</sup> It usually develops insidiously and mainly occurs in face, neck or both and is less common in leg and hand. Medical management of dystonia is often unsatisfactory and surgical treatment like thalamotomy, pallidotomy and Deep Brain Stimulation (DBS) have shown some promising results.<sup>3,4</sup>

### Case Report

A 47-years-old lady complained of abnormal neck movement since five months. It initially started with slow involuntary repetitive contraction of her neck muscles

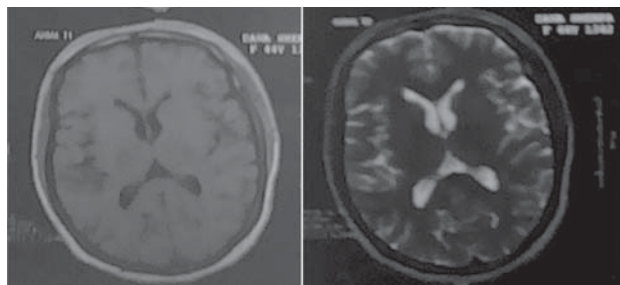


Figure 1: Preoperative MRI Brain, T1W and T2W Axial Images

which was intermittent type with the frequency of about 3-4 times in a day and it did not occur at night. But gradually the frequency increased and progressed rapidly to her trunk muscles when we first saw her. But in two weeks time the symptoms again progressed and she was almost bed bound and could not mobilize by herself.

She had past history of taking antipsychotics (Haloperidol) and antidepressant (amtryptiline) since two years but she had no early dystonic reactions to her drugs. When she visited her psychiatrist with these symptoms five months back, she was advised to stop all those medicine and sodium valproate, baclofen and clonazepam was started. However her symptoms did not improve and progressed rapidly.

She has no family history of dystonia and no other significant past medical history. On examination, she had twisting and bending of the neck and head to one side of the upper thorax mainly on the right and sometimes on the left. Her Magnetic Resonance Imaging (MRI) brain was grossly normal as shown in (Figure 1) and her MRI Cervical spine showed degenerative changes only. Other hematological parameters were normal. After proper discussion of the case, we reached to the conclusion that she can be a surgical candidate either Bilateral (B/L) Globus Pallidus internus (GPi) DBS or bilateral pallidotomy. As B/L GPi DBS was expensive and the patient could not afford it, we finally decided for B/L GPi pallidotomy and patient and patient party were counselled about the procedure and the possibility of failure or recurrence.

### Surgical Method

A day before the operation we decided for a brain MRI under general anesthesia in a 0.3 T Machine (Siemens) as her head was constantly moving. Then her imaging was transferred in DICOM CD. Then the next day she was kept on stereotactic frame (ZD Fisher) under local anesthesia. Then 4 slice CT(Siemens) scan was taken with minimum spacing with her frame in situ. And this imaging was also taken in a DICOM CD. Finally the previous image of her MRI and this CT image with the frame was

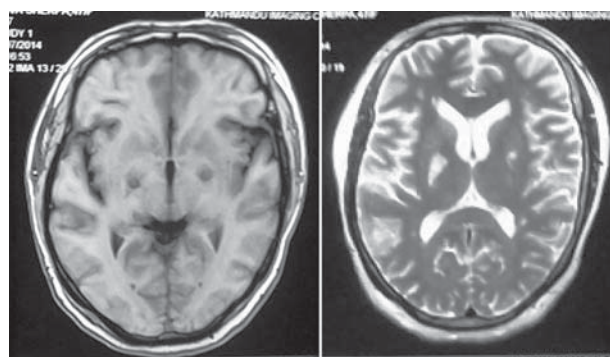


Figure 2: Immediate postoperative MRI Brain; T1W and T2W Axial Images

Showing lesion in B/L Globus Pallidus Internus with perilesional edema

transferred into the computer where the fusion software was present. In this computer or workstation, these two images were fused and area of GPi was identified anatomically and reverified with the inbuilt Scheltenberg Atlas. The usual targets for GPi were also used. After determination of the targets for both right and left GPi, the patient was transferred to the operation table. Her head with the frame was fixed in a head holder. Under all aseptic precautions local anesthesia was given on her scalp and bilateral vertical incision was given (4 cm lateral to midline and 1 cm in front of coronal suture). Two burr holes were created and dura was coagulated and cut. The thermal lesioning machine of Cosman RF generator was used and the voltage, impedance and rate of the thermal coagulation were set. The lesioning electrode of 1 mm diameter and 2 mm exposed tip was used.

At first the lesioning was started on the left side. The targets were set and it was checked by C-arm. Firstly test dose of 50 degree centigrade for 30 sec was used and we made sure that there is no motor deficits. Then two lesions were made 1 mm apart (70 degree centigrade for 40 second each). Continuous communication to the patients was done to make sure that there is no motor symptoms and visual symptoms. Similar procedure was done on the right side with 65 degree for 40 second each.

Hemostasis was secured and there was no intraoperative complications like hemorrhage or seizure and the patient felt much comfortable and then was shifted to the postoperative ICU.

On the first postoperative day, her symptoms completely resolved like magic and there was no involuntary movement at all. She was given prophylactic anti epileptic Drug ( Phenytoin) but steroid was not given.

Postoperative MRI Brain was done on 5<sup>th</sup> post operative day and it showed beautiful lesions over the B/L GPi region as shown in (Figure 2). There was some

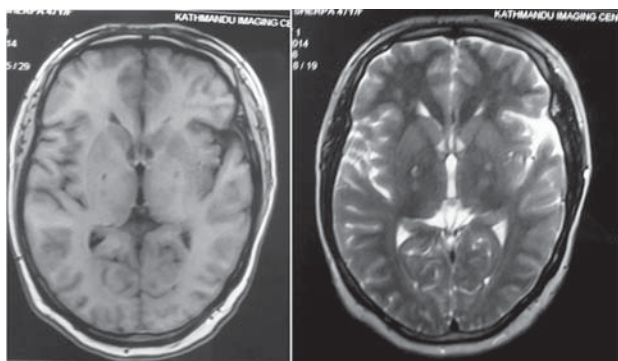


Figure 3: Postoperative MRI Brain After three months; T1W and T2W Axial Images:

Showing lesion in B/L Globus Pallidus Internus without perilesional edema

perilesional edema with no other complications. The patient was discharged on the 5th postoperative day and the sutures were removed on the 10th post operative day. All her medicines were stopped and she was in regular follow up. After three months of her regular follow up, there are still no symptoms. Repeat MRI after three month still showed the lesion but it has become smaller and there is no perilesional edema as shown in (Figure 3).

## Discussions

Tardive dystonia was first reported by Keegan and Rajput.<sup>5</sup> Burke et al showed its correlation with antipsychotics and developed four criteria to diagnose it.<sup>1</sup> They include: 1) presence of dystonic movements or postures; 2) their development during treatment with D2 receptor blockers or within 2 months of treatment discontinuation; 3) a negative family history for dystonia; 4) exclusion of other secondary dystonias, such as Wilson's disease. Our patient completely met all these criteria.

The exact pathophysiology of tardive dystonia is not well understood but it is mainly attributed to chronic dopamine receptor blocking effects. Other leading explanatory models include dopamine receptor supersensitivity, depletion of GABA (Gamma Amino butyric Acid) receptors, deficiency of cholinergic activities, neurotoxicity, changes in synaptic plasticity and defective neuroadaptive signaling.<sup>9</sup>

The incidence of TD is higher in middle aged and elderly patients mainly women and the risk is still higher in postmenopausal women<sup>13</sup> and our case is a perimenopausal women.

Medical treatment of Tardive Dystonia is very complex and many cases do not respond well to currently available treatment and sometimes can be irreversible. In our case

## Tardive Dystonia

the patient was not responsive to the combination of baclofen, valproic acid and clonazepam.

Surgical lesions in the striatum i.e. lesioning have been noted to help some patients with TD.<sup>11</sup> This may be due to interruption in the movement pathways resulting in stopping/mitigating any involuntary movements. The target for treatment of dystonia is located in the posteroventral lateral portion of the GPi. The standard co-ordinates of the GPi are 20-22 mm lateral, 4 mm below and 2-3 mm anterior to the mid commissural line. Usually two lesions are placed with a distance of 2 mm along the trajectory of radiofrequency probe.<sup>6,8</sup>

In cases of unilateral pallidotomy, there is risk of contralateral weakness or hemiparesis if the lesion is too close to internal capsule and speech disturbance may occur in bilateral surgery. These complications did not occur in our cases and these things can be prevented when we perform the surgery in local anesthesia as there is continuous communication to the patients.

Nowadays Deep brain stimulation (DBS) of GPi is the treatment of choice due to the reversibility and adaptability. There are studies showing an average improvement 71% after 3 months of GPi stimulation and maintained till 6 months follow up.<sup>7,14</sup> Our patient did not undergo DBS due to financial constraint. But with bilateral pallidotomy she is completely symptom free in three months follow up and follow up MRI also shows the lesion. Now it has been more than a year and she is still fine.

## Conclusions

Tardive dystonia results from prolong use of antipsychotic medications and one should be careful when prescribing them rampantly. It is very challenging to treat. If the medical treatment fails, then surgical treatment like pallidotomy will be very beneficial to the patient.

## References

1. Burke RE, Fahn S, Jankovic J, et al. Tardive dystonia: late-onset and persistent dystonia caused by antipsychotic drugs. **Neurology** 32: 1335-1346, 1982
2. Fahn S, Marsden CD, Calne DB: Classification and investigation of dystonia. In Marsden CD & Fahn S eds. *Movement Disorders 2*. Butterworth & Co, London, 332-358, 1987
3. Hamani C, Moro E. Surgery for other movement disorders-dystonia, tics. **Curr Opin Neurol** 20: 470-476, 2007

Shrestha et al

4. Jankovic J. Treatment of dystonia. **Lancet Neurol** **5**: 864-872, 2006
5. Keegan DL, Rajput AH: Drug induced dystonia tarda. Treatment with 1-dopa. **Dis Nerv Syst** **34**: 167-169, 1973
6. Krauss JK, Grossman RG. Principles and techniques of movement disorders surgery. In: Krauss JK, Jankovic J, Grossman RG, editors. Surgery for parkinson's disease and movement disorders. Philadelphia: Lippincott, Williams & Wilkins; 74-109, 2001
7. Mentzel CL, Tenback DE, Tijssen MA, Visser-Vandewalle VE, van Harten PN. Efficacy and safety of deep brain stimulation in patients with medication-induced tardive dyskinesia and/or dystonia: a systematic review. **J Clin Psychiatry** **73**: 1434-1438, 2012
8. Ondo WG, Krauss JK. Surgical therapies for dystonia. In: Brin MF, Comella C, Jankovic J, editors. Dystonia monograph. Philadelphia: Lippincott, Williams & Wilkin., 125-147, 2003
9. Rana AQ, Chaudry ZM, Blanchet PJ. New and emerging treatments for symptomatic tardive dyskinesia. **Drug Des Devel Ther** **7**:1329-1340, 2013
10. Tarsy D, Simon DK. Dystonia. **N Engl J Med** **355**: 818-829, 2006
11. Thobois S, Poisson A, Damier P. Surgery for tardive dyskinesia. **Int Rev Neurobiol** **98**: 289-296, 2011
12. Van Harten PN, Kahn RS. Tardive dystonia. **Schizophr Bull** **25**: 741-748, 1999
13. Waln O, Jankovic J. An Update on tardive dyskinesia: from phenomenology to treatment. **Tremor Other Hyperkinet Mov** **3**: 03-161-4138-1, 2013
14. Welter ML, Grabli D, Vidailhet M. Deep brain stimulation for hyperkinetics disorders: dystonia, tardive dyskinesia, and tics. **Curr Opin Neurol** **23**: 420-425, 2010