

Neuro View Box

Anish M Singh, MSDepartment of Neurosurgery,
Norvic International Hospital,
Thapathali, Kathmandu, Nepal**Rupendra B Adhikari, MD**Department of Neurosurgery,
Hiroshima University, Hiroshima, Japan**Hemant Sah, MS**Department of Neurosurgery,
Norvic International Hospital,
Thapathali, Kathmandu, Nepal**Prabin Shrestha, MD, PhD**Department of Neurosurgery,
Norvic International Hospital,
Thapathali, Kathmandu, Nepal**Address for Correspondence:**

Anish M Singh, MS

Department of Neurosurgery,
Norvic International Hospital,
Thapathali, Kathmandu, Nepal**Email:** anishmsingh@gmail.com**Received,** October 6, 2015**Accepted,** October 15, 2015

A 23-year-old male presented with multiple episodes of seizures and headache for few months. On neurological examination his GCS was 15/15 without any deficits.

CT scan of head was done which (**Figure 1A**) showed hypodense lesion in corpus callosum region. To further confirm the type of lesion MRI brain was done which showed hyperintense lesion in all T1W T2WI and FLAIR images in the same region. However, the lesion appeared hypointense in fat suppression images (**Figure 1B,C,D,E**). On the basis of these radiological features the diagnosis of intracranial lipoma was made.³

Patient was started on anti-epileptic drugs (AED) following which he is completely seizure-free. MRI brain repeated after few years of regular follow up revealed no increase in size of the mass

Intracranial lipoma is a benign slow growing congenital lesion, which accounts for <0.1% of all primary brain tumors.^{1,2} This congenital aberration stems from abnormal differentiation of persistent meninx primitive, an area that constitutes the inner level of pia, arachnoid and dura mater.³ They can be found anywhere intracranially. The most common ones based on sites are¹Pericallosal Lipoma (45%), Quadrigeminal cistern lipoma (25%), Suprasellar cistern lipoma (15%), Cerebellopontine angle lipoma (10%), Sylvian fissure lipoma (5%). Our case is a pericallosal lipoma which is most common type.

Intracranial Lipoma: A Rare Variant of Brain Tumor

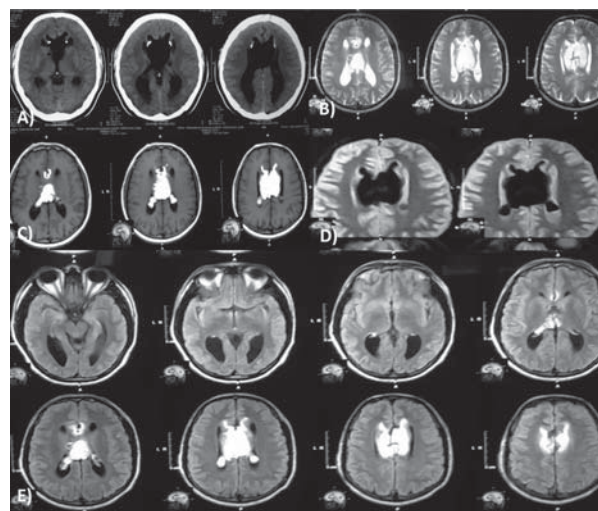


Figure 1: A) CT head axial showing hypodense lesion in pericallosal region with tiny calcifications, B) the same pericallosal lesion appearing hyperintense in T1WI image, C) hyperintense in T2WI image, D) hypointense in Fat suppression image and E) hyperintense FLAIR Image

These tumors are mostly detected as incidental finding in CT and MRI.^{2,3} In CT, it typically appears as a mass with uniform hypodense fat density without enhancement. Some peripheral calcification may be present, occasionally, as in our case. Diagnosis is straightforward with MRI (with or without fat saturation sequences). MRI features include: high signal intensity in T1WI and T2WI, without enhancement in T1WI with contrast and low signal in fat saturated sequences.

These tumors rarely need surgical excision and histopathological confirmation.¹ Symptomatic conservative management is enough in most cases as we did in our case.

References

1. Ogbole G, Kazaure I, Anas I. Quadrigeminal plate cistern lipoma. **BMJ Case Rep.** doi: 10.1136/bcr.07.2009.2110. 2009
2. Venkatesh BP, Malik G, Bora MK, Narasingam AP. Multiple intracranial lipoma. **J health Spec** 2:78-81, 2014
3. Yilmaz N, Unal O, Kiymaz N, Yilmaz C, Etlik O. Intracranial lipomas--a clinical study. **Clin Neurol Neurosurg.** 108(4):363-368, 2006