


## Morphometric Assessment of Sellar Turcica: Tertiary Neurocenter study from Nepal

Suresh Bishokarma<sup>1</sup>, Mohit Raj Dahal<sup>2</sup>, Nawaraj Adhikari<sup>3</sup>, Suraj Bhusal<sup>4</sup>, Shamin Parajuli<sup>5</sup>, Suraj Gurung<sup>6</sup>, Shiwani Rai<sup>7</sup>, Rushel Chowhan<sup>8</sup>, Sunita Shrestha<sup>9</sup>, Suraj Thulung<sup>10</sup>



<sup>1,2,3,4,5,6,9,10</sup> Department of Neurosurgery, Upendra Devkota Memorial National Institute of Neurological & Allied Sciences

<sup>7,8</sup> Department of Otorhinolaryngology, Upendra Devkota Memorial National Institute of Neurological & Allied Sciences

Date of submission: 14<sup>th</sup> July 2023

Date of Acceptance: 18<sup>th</sup> December 2023

Date of publication: 15<sup>th</sup> January 2023

### Abstract

**Introduction:** The sella turcica (ST) is a vital structure located in the median position within the middle cranial fossa and is frequently utilized in cephalometric for assessing craniofacial features. However, there is limited literature available regarding cephalometry of the ST in Nepal. Consequently, this study aimed to establish the normal dimensions of the ST in the Nepalese population and explore the potential difference in radio-morphometric measurement among sexes.

**Materials and Methods:** This study encompassed a descriptive, cross-sectional chart review conducted at the Upendra Devkota Memorial National Institute of Neurological and Allied Sciences over a three-month period. Morphometric assessment of the ST was performed using computed tomography scans. A single radiologist employed an EV Insite DICOM viewer to measure and record the length, depth, and antero-posterior diameter of the ST. Independent-Samples t-test was employed to compare the means between sexes, and a significance level of  $p < 0.05$  was considered statistically significant.

**Results:** Among the 385 cases analyzed, 199 were male (51.8%) and 185 were female (48.2%), resulting in a male-to-female ratio of 1.07:1. The age range of the patients was 20 to 87 years, with a mean age of  $44.5 \pm 18.5$  years. The mean dimensions of the sella turcica were determined as 9.32 mm for length, 7.07 mm for depth, and 10.29 mm for the antero-posterior diameter.

**Conclusions:** The findings of this study indicate that the ST dimensions in the Nepalese population are relatively smaller compared to those reported in various other countries. Additionally, no statistically significant differences were observed in ST dimensions between males and females within the Nepalese population. These results emphasize the importance of considering population-specific variations when utilizing cephalometric measurements and provide valuable reference standards for future studies and accurate assessment of craniofacial morphology in the Nepalese population.

### Introduction

The sella turcica is a structure readily recognized on lateral cephalometric radiographs and routinely traced for cephalometric analysis. This makes it a good source of additional diagnostic information related to pathology of the hypophysis, or to various syndromes that affect the craniofacial region. Clinicians should be familiar with the normal radiographic

anatomy and morphologic variability of this area, in order to recognize and investigate deviations that may reflect pathological situations, even before these become clinically apparent.<sup>1,2</sup> The main objective of this study was to establish the normal dimensions of the sella turcica in the Nepalese population, with a specific focus on exploring the potential role of radio-morphometric analysis of the sella turcica in determining the sex of individuals. The findings from this study can serve as reference standards for future investigations involving the sella turcica area in the Nepalese population.

#### Access this article online

Website: <https://www.nepjol.info/index.php/NJN>

DOI: <https://doi.org/10.3126/njn.v20i4.56637>



#### HOW TO CITE

Bishokarma S. Morphometric Assessment of Sellar Turcica: Tertiary Neurocenter study from Nepal. NJNS. 2023;20(4):23-26

#### Address for correspondence:

Dr. Suresh Bishokarma,  
Consultant Neurosurgeon  
Department of Neurosurgery Upendra Devkota Memorial National  
Institute of Neurological & allied Sciences  
E-mail: [drsureshbk@gmail.com](mailto:drsureshbk@gmail.com)

Copyright © 2023 Nepalese Society of Neurosurgeons (NESON)

ISSN: 1813-1948 (Print), 1813-1956 (Online)

This work is licensed under a Creative Commons Attribution-Non Commercial 4.0 International License.



### Material & Methods

This was a descriptive, cross sectional chart review conducted in this Institute for a period of 3 months. Computed tomography (CT) based morphometric assessment of Sellar Turcica was done. Standard formula for calculating the sample size was calculated as;

$$N = Z^2 * P * (1 - P) / e^2 = 384.16$$

Where,

Z is the z-score = 1.96

e is the margin of error = 0.05

P is the standard of deviation = 0.5

Sample size of 385 was considered for data collection.

Computed tomography (CT) scans of adult patients were performed using Siemens Somatom 16 Slice CT Scanner with

exposure parameters of 120 kV, 200 mA, 2-second scanning time and bone algorithm. All data are available on institutional picture archiving and communication systems (PACS) with individuals' identification. Dimensions were measured and recorded by radiologists by using an EV Insite DICOM viewer. Exclusion criteria were Pediatric age group, Cleft lip and palate patients, Scan that had a patient history of surgery and Traumatic and pathological condition in the sellar/parasellar region.

The following measurements will be obtained in the midsagittal section according to Silverman and Kisling methods.<sup>3,4</sup>

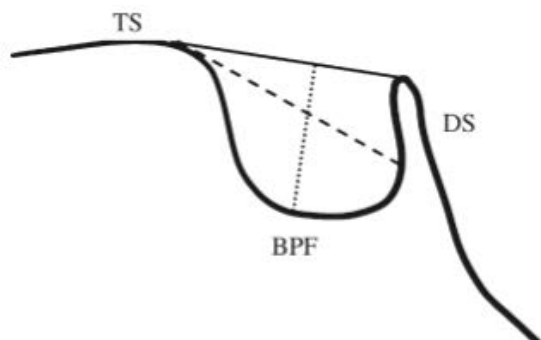


Figure 1: Normal sella turcica morphology and reference lines used for measuring sella size:

- TS: Tuberculum sellae
- DS: Dorsum sellae
- BPF: Base of the pituitary fossa

- Sella length: The distance from tuberculum sellae to dorsum sellae. (Black line)
  - Sella depth: The length of the line drawn vertically from the deepest point of the sella turcica in the direction of the sella turcica length. (Dotted line)
  - Antero-posterior diameter: The distance measured from the tuberculum sellae to the backmost point in the interior surface of the posterior wall of the pituitary fossa. (Dashed line)

Data was collected in the pre-formed proforma and entered in Microsoft Excel Version 2020 and analyzed using IBM SPSS Statistics version 24.0. Point estimate and 95% CI were calculated. Independent-Samples t-test was conducted to compare means among different sexes.

## Result

Out of a total of 385 cases, there were 199 males (51.7%) and 186 females (48.3%), resulting in a male-to-female ratio of 1.07:1. The minimum age observed among the patients was 20, while the maximum age was 87. The mean age was calculated as 44.5±18.5. The average measurements for the length, depth, and antero-posterior (AP) diameter of the sella turcica (ST) were 9.32 mm, 7.07 mm, and 10.29 mm, respectively. Our study revealed similarity in these measurements between males and females. Specifically, the mean length, depth, and AP diameter of ST for males were 9.36 mm, 6.99 mm, and 10.26 mm, respectively, while for females, the corresponding values were 9.28 mm, 7.16 mm, and 10.31 mm. However, this difference

was not statistically significant. (Table 1). Dimension were statistically not significant in different age groups. Moreover, there were no statistically significant deviations in dimension of sella turcica from normal trend among different age in the studied populations.

Table 2: Morphometric Measurements of Sella diameters.

Dimensions	Measurements (in mm)	Total cases N= 385	Male n= 199	Female n= 186	P value
Sella Length	Minimum	5	5	6	0.526
	Maximum	13	13	13	
	Mean	9.32	9.36	9.28	
	Standard Deviation	1.54	1.58	1.48	
Sellar Depth	Minimum	4	4	4	0.148
	Maximum	12	11	12	
	Mean	7.07	6.99	7.16	
	Standard Deviation	1.15	1.09	1.19	
Anteroposterior diameter	Minimum	7	7	7	0.712
	Maximum	14	14	14	
	Mean	10.30	10.26	10.33	
	Standard Deviation	1.3	1.3	1.3	

Independent-Samples t-test to assess Equality of Means was conducted to compare means among different sexes. P value of <0.05 was considered significant.

## Discussion

Sella turcica (ST) is a crucial structure that is morphologically situated in the median position in middle cranial fossa and is well-used in cephalometrics. ST is an intracranial bony structure that plays an important role in the endocrine equilibrium of the body.<sup>5</sup> This is because of the presence of the pituitary endocrine gland inside it. Any pertinent and notable variations in the dimension of ST usually lead to the malfunctioning of the pituitary gland and its hormones. In our study, the mean length, depth, and AP diameter of ST were 9.32 mm, 7.07 mm, and 10.30 mm. Variations in the measurements of the length, depth and antero-posterior diameter of sella turcica among male and females were noted in our study. The mean length, depth, and AP diameter of ST in male were 9.36 mm, 6.99 mm and 10.26 while the mean length, depth, and AP diameter of ST in females were 9.28 mm, 7.16mm, and 10.33 mm. In Usman et al. the mean length, depth, and AP diameter of ST in male participants were 9.82 mm, 8.89 mm, and 12.93 mm, respectively.<sup>6</sup> The values for female participants were slightly lesser at 9.64 mm, 8.28 mm, and 12.03 mm for length, depth, and AP diameter, respectively. These findings are inconsistent with Kumar et al. where the measurements of ST dimensions for female participants were larger.<sup>7</sup> Mean sella turcica linear dimensions measurement from various studies from different countries shows the dimension of ST to be comparable/smaller or larger in comparison to our Nepali population (Table 2).

## Morphometric Assessment of Sellar Turcica:

Alkofide et al reported no difference between male and female in mean depth and diameter but the length was larger in male throughout the observation period.<sup>15</sup> However, Turamanlar et al concluded mean length larger in female compared to male.<sup>12</sup> Comparing the value of our study with that of Srinivas et al who reported values of length 9.51, depth 7.39 mm and Antero-posterior diameter 10.13; values are larger compared to our study.<sup>9</sup> Hasan et al reported mean sella-turcica length (antero-posterior diameter) even larger than values reported by Srinivas et al.<sup>14</sup> However, Ghaida et al reported mean sella turcica dimension lesser as compared to our study.<sup>8</sup>

**Table 3:** Comparison of different studies for mean sella turcica linear dimensions (in mm):

Studies	Length (mm)	Depth (mm)	Anterior-posterior diameter (mm)
Present Study	9.32	7.07	10.30
Jordan <sup>8</sup>	7.55	6.32	.....
India <sup>9</sup>	9.51	7.39	10.13
Malaysia <sup>10</sup>	8.46	7.44	10.79
Brazil <sup>11</sup>	10.31	6.33	.....
Turkey <sup>12</sup>	9.18	7.87	11.48
Iraq <sup>13</sup>	8.46	7.44	10.49
Nigeria <sup>14</sup>	9.8	8.6	11.5

**Table 3:** Comparison of different studies for mean sella turcica among male and female in linear dimensions (in mm)

Studies	Male			Female			Significance
	Length	Depth	APD	Length	Depth	APD	
Present Study	9.36	6.99	10.26	9.28	7.16	10.33	None
Saudi Arabia <sup>15</sup>	11	9.1	13.9	10.7	9.1	14	None
Malaysia <sup>10</sup>	10.26	6.61	.....	10.45	6.66	.....	None
Iraq <sup>13</sup>	10.79	7.44	.....	10.47	7.07	.....	None
Turkey <sup>12</sup>	9.64	7.79	11.73	8.5	7.98	11.11	<0.05 for Length
India <sup>9</sup>	9.87	7.42	10	9.1	7.36	10.25	<0.05 for Length
North India <sup>16</sup>	7.8	5.6	.....	7.54	7.53	.....	<0.05 for depth

Abbr: APD: Anteroposterior Diameter

## Conclusions

The typical measurements for the length, depth, and anteroposterior (AP) diameter of the sella turcica were 9.32 mm, 7.07 mm, and 10.29 mm, respectively. This study's findings suggest that the sella turcica dimensions in the Nepalese population are comparatively smaller when compared to measurements from various other countries. Additionally, no significant differences in sella turcica dimensions were observed between males and females and among different ages in the study population. Our study may have clinical implication on recognizing and investigating deviations of sella anatomy among Nepalese population that may reflect pathological situations, even before these become clinically apparent. Further research is needed to explore potential connections between sella turcica dimensions and other craniofacial characteristics in this particular population.

## Reference

1. Feldkamp J, Santen R, Harms E, Aulich A, Mödder U, Scherbaum W A. Incidentally discovered pituitary lesions: high frequency of macroadenomas and hormone-secreting adenomas—results of a prospective study. *Clinical Endocrinology*. 1999;51:109-13. <https://doi.org/10.1046/j.1365-2265.1999.00748.x>
2. Friedland B, Meazzini M C 1996 Incidental finding of an enlarged sella turcica on a lateral cephalogram. *American Journal of Orthodontics and Dentofacial Orthopedics* 110: 508–12. [https://doi.org/10.1016/s0889-5406\(96\)70057-4](https://doi.org/10.1016/s0889-5406(96)70057-4)
3. Silverman FN. Roentgen standards for size of the pituitary fossa from infancy through adolescence. *Am J Roentgenol* 1957;78:451-60. PMID: 13458563

4. Kisling E. Cranial morphology in Down's syndrome. A comparative roentgencephalo-metric study in adult males Thesis, Munksgaard, Copenhage; 1966.
5. Surana MP, Bhagawati BT, Kumar N, Jaral S, Kumar A, B S. Radio-Morphometric Analysis of Sella Turcica in Relation to Age and Gender in Sri Ganganagar Population: A Prospective Cephalometric Study. *Cureus*. 2022;14(11):e32048. <https://doi.org/10.7759/cureus.32048>
6. Usman Z, Zagga AD, Yunusa GH, Abubakar A, Bello A, Usman JD et al. Shapes and sizes of sella turcica using computerized tomography(CT) from Tertiary Hospital in Sokoto, Nigeria. *Asian J Med Health*. 2020;24:8-15. <https://doi.org/10.9734/ajmah/2020/v18i130175>
7. Kumar TM, Govindraju P. Relationship between the morphological variation of sella turcica with age and gender: a digital radiographic study. *J Indian Acad Oral Med Radiol*. 2017, 29:164-9.
8. Ghaida JHA, Mistareehi AJ, Mustafa AG, Mistarihi S, Ghozlan HH. The normal dimensions of the sella turcica in Jordanians: A study on lateral cephalograms. *Folia Morphol (Warsz)*. 2017;76(1):01-9. <https://doi.org/10.5603/fm.a2016.0038>
9. Srinivas M, Vedaraju K, Vijay Kumar K, Deepashri B. Morphometry of sella turcica in an Indian population using computed tomography. *International Journal of Anatomy, Radiology and Surgery*. 2017;6(1):06-11.
10. Hasan HA, Alam MK, Yusof A, Mizushima H, Kida A, Osuga N. Size and morphology of sella turcica in Malay populations: A 3D CT study. *Journal of Hard Tissue Biology*. 2016;25(3):313-20. <https://doi.org/10.2485/jhtb.25.313>
11. Ruiz C, Wafae N, Wafae G. Erratum: Sella turcica morphometry using computed tomography. *European Journal of Anatomy*. 2008;12(1):47-50.
12. Turamanlar O, Öztürk K, Horata E, Acay MB. Morphometric assessment of sella turcica using CT scan. *Anatomy: International Journal of Experimental & Clinical Anatomy*. 2017;11(1):3-11. <http://dx.doi.org/10.2399/ana.16.047>
13. Hasan HA, Alam MK, Abdullah YJ, Nakano J, Yusa T, Yusof A, et al. 3D CT morphometric analysis of sella turcica in the Iraqi population. *Journal of Hard Tissue Biology*. 2016;25(3):227-32.
14. Ejike CA, Anthony U, Adimchukwunaka GA. Computed Tomography Evaluation of Sella Turcica Dimensions and Relevant Anthropometric Parameters in an African Population. *International Journal of Neurosurgery*. 2017;1(1):07-11.
15. Alkofide EA. The shape and size of the sella turcica in skeletal Class I, Class II, and Class III Saudi subjects. *The European Journal of Orthodontics*. 2007;29(5):457-63. <https://doi.org/10.1093/ejo/cjm049>
16. Chauhan P, Kalra S, Mongia SM, Ali S, Anurag A. Morphometric analysis of sella turcica in North Indian population: A radiological study. *Int J Res Med Sci*. 2014;2(2):521-26.