

# Spinal Epidural Cavernous Hemangioma Mimicking Schwannoma: Case Report and Review of Literature



Abhinav Debanath<sup>1</sup> , Subir Dey<sup>2</sup> 

<sup>1</sup> YCM hospital and PGI, Pimpri, Pune, Maharashtra, India, <sup>2</sup> Armed Forces Medical College and Command Hospital Southern Command, Pune, Maharashtra, India

Date of submission: 3<sup>rd</sup> March 2022

Date of acceptance: 18<sup>th</sup> May 2022

Date of publication: 25<sup>th</sup> June 2022

## Abstract

Pure epidural spinal cavernous hemangiomas are encountered rarely in clinical practice. These lesions are more commonly found in the thoracic region and present with features of myelopathy. Presentation is usually insidious due to slow growth of these tumors, however, acute neurological deterioration is possible in cases with intra-lesional hemorrhage. Surgery is the treatment of choice with patients having good outcomes after complete resection. Due to high vascularity there may be excessive blood loss intra-operatively which might limit complete resection. It is for these reasons that these lesions should be considered in the differential diagnosis of spinal epidural lesions. Literature on these lesions reveals that these tumors are pre-operatively misdiagnosed as schwannomas. We report a case of an elderly male who presented with features of myelopathy and an epidural lesion in the thoracic region. A diagnosis of spinal epidural schwannoma with paravertebral extension was made pre-operatively on the basis of imaging characteristics. However, the lesion was found to be highly vascular during surgery and post-resection histopathology revealed a cavernous hemangioma.

**Key words:** Cavernous hemangioma, Spinal extradural tumor

## Introduction

Primary Spinal Extradural tumors constitute only 10% of all spinal extradural tumors<sup>1</sup>. Cavernous Hemangioma must be considered in the differential diagnosis of pure extradural spinal lesions. These tumors are generally benign slow growing lesions which usually present with features of myelopathy<sup>2,3,4,5</sup>. These lesions are usually an extension from a vertebral origin, but less commonly, they are purely extradural and may be misdiagnosed pre-operatively as nerve sheath tumors and meningiomas<sup>2,6,7</sup>. Certain imaging characteristics may

help in clinching the diagnosis<sup>7,8</sup>. However, a high index of suspicion is required.

## Case Report

A 56 years old male, known case of Chronic Hepatitis B Virus infection, presented with insidious onset, gradually progressive weakness and tightness of both lower limbs with imbalance while walking of two months duration. He also complained of burning sensation over the left half of his lower back. Neurological examination revealed spastic paraparesis with no sensory deficits. His Deep Tendon reflexes were brisk and Plantar reflex showed equivocal response on left side with flexor response on the right side. Rest of the neurological examination was normal.

He underwent Contrast enhanced MRI of Dorsal spine with whole spine screening and Computed Tomography of dorsal spine.

His Ultrasound of abdomen and pelvis revealed chronic changes in liver with normal portal vein diameter and normal post-void urine volume. Hematological and biochemical analysis did not favor a diagnosis of plasmacytoma. A provisional diagnosis of D6 to D8 extradural schwannoma with paravertebral extension and D7 vertebral hemangioma was made.

He underwent Laminectomy D6-D8 with excision of tumor. D6-D7 facet joint on left side was removed for adequate exposure of paraspinous component. Intra-operatively a reddish, firm, non-suckable, highly vascular tumor with well-defined tumor-dural interface was found extending into the left paravertebral space. Complete

### Access this article online

Website: <https://www.nepjol.info/index.php/NJN>

DOI: <https://doi.org/10.3126/njn.v19i2.43608>

### HOW TO CITE

Debanath A, Dey S. Spinal Epidural Cavernous Hemangioma Mimicking Schwannoma: Case Report and Review of Literature. NJNS. 2022;19(2):64-67.



### Address for correspondence:

Dr. Abhinav Debanath  
YCM Hospital and PGI,  
Pimpri, Pune, Maharashtra, India.  
E-mail: [abhi.debanath@gmail.com](mailto:abhi.debanath@gmail.com)  
Phone: +91 9130052518

Copyright © 2022 Nepalese Society of Neurosurgeons (NESON)

ISSN: 1813-1948 (Print), 1813-1956 (Online)

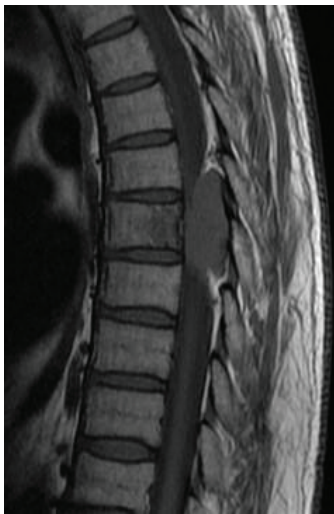

This work is licensed under a Creative Commons Attribution-Non Commercial 4.0 International License.

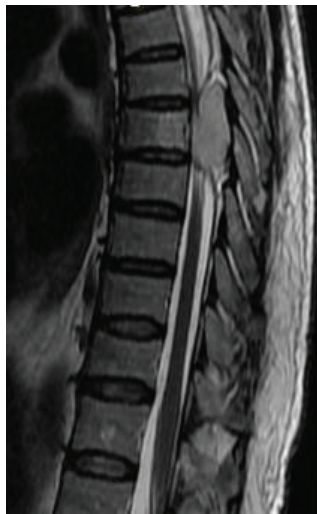## Spinal Epidural Cavernous Hemangioma Mimicking Schwannoma: Case Report and Review of Literature

excision of tumor was done without spinal fixation. Intra-operative frozen section was suggestive of Hemangioma.

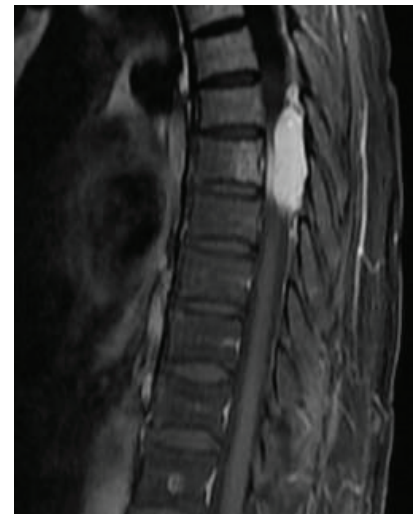Final histo-pathological report was suggestive of Cavernous Hemangioma.



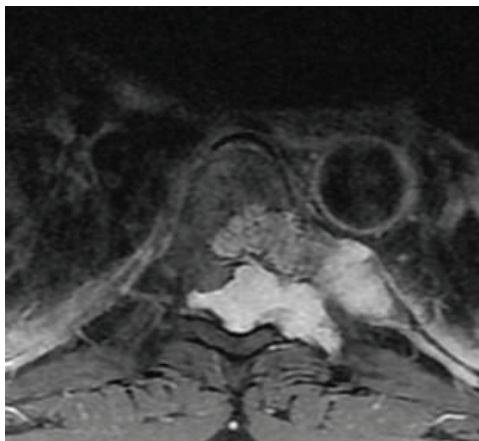
*Figure 1: Sagittal T1W MRI image showing hypointense posterior epidural soft tissue lesion in thoracic spine.*



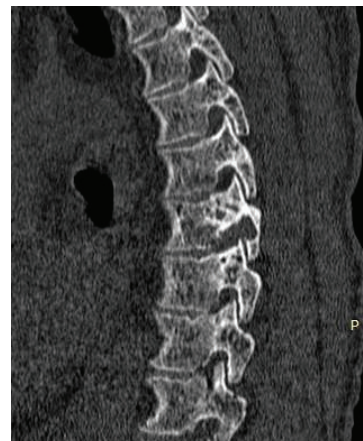*Figure 2: Sagittal T2W MRI image showing homogeneously hyperintense lesion in epidural space along with hyperintensity in D7 vertebral body.*



*Figure 3: Sagittal post-contrast MRI image showing brilliantly enhancing epidural lesion spanning 3 vertebral segments (D6 to D8).*



*Figure 4: Axial post-contrast MRI image showing brilliant post-contrast enhancement separate from vertebral lesion.*



*Figure 5: Sagittal CT image showing widening of left neural foramen of D7 vertebra along with erosion of bone.*

### Discussion

Cavernous hemangiomas are benign vascular lesions of congenital origin found throughout the central nervous system. They are mostly encountered as intra-parenchymal lesions in the supratentorial compartment<sup>8,9,10</sup>. They make up 3 to 16% of all spinal vascular lesions<sup>5,9,10</sup>. Spinal cavernous hemangiomas usually originate from the vertebral body and may present in the epidural space through secondary extension. Pure epidural cavernous hemangiomas are a rare entity and they account for 12%

of all intraspinal cavernous malformations and only 4% of all spinal epidural tumors<sup>2,4,5,7,8,9,11,12,13</sup>. Most literature on pure spinal epidural cavernous hemangiomas is based on isolated case reports and small case series<sup>2-13</sup>. They usually present in patients aged 30-60 years with peak incidence at 40 years of age<sup>3,4,5</sup>. Literature review has revealed a female preponderance in most reports<sup>2,3,4</sup>. However, there are conflicting reports showing a predominantly male distribution<sup>3,11,12</sup>. This observation may be attributed to the rarity of the tumors and the relatively small sample size in most reports.

These lesions are most commonly found in the thoracic region followed by cervical spine<sup>2,3,4,5,8,9,11</sup>. However, a retrospective review of 23 cases of pure epidural hemangiomas by Zhang L published in 2020 found the lumbar region to be the second most common region affected with cervical being less common<sup>2</sup>. These lesions commonly present with features of myelopathy<sup>2,3,4,5</sup>. The growth of these tumors is attributed to micro-hemorrhages in the lesion<sup>2</sup>. Acute neurological deterioration is seen if there is bleeding or thrombosis within the lesion<sup>2,3,6,7,8</sup>.

Spinal epidural cavernous hemangiomas are most commonly found in the posterior epidural space but can rarely extend through the neural foramen giving them a dumb-bell shape mimicking nerve sheath tumors<sup>2,4,6,7,12</sup>. An analysis of 118 cases of spinal dumbbell tumors by Hiroshi Ozawa et al in 2007 revealed that only 2% of these tumors were histopathologically proven to be hemangiomas, with the most common being schwannomas (69%) followed by neurofibromas (12%)<sup>14</sup>. It has been found that dumbbell shaped hemangiomas do not cause dilatation of neural foramen as often as nerve sheath tumors of comparable size<sup>3,5,12</sup>.

MRI of the spine with contrast administration is the investigation of choice for these lesions. They may have an ovoid shape and have a tendency to wrap around the cord. These lesions are iso to hypointense on T1W, homogeneously hyperintense on T2 W images and show brilliant post-contrast enhancement. Dural enhancement is usually not seen. This appearance correlates with their histological appearance<sup>2,3,6,7</sup>. Peripheral hemosiderin ring, seen in intraparenchymal cavernous hemangiomas, is not seen in these lesions possibly because of effective clearance of blood products from the spinal epidural space<sup>3</sup>. Features that may differentiate it from schwannomas are the homogenous appearance and brilliant enhancement of these lesions. However, widening of the neural foramen and a dumbbell shape point more towards the lesion being of neural origin<sup>3,5,12</sup>. In our case, even though the lesion was homogeneously enhancing, a pre-operative diagnosis of schwannoma was made due to the paravertebral spread through the neural foramen. Review of the existing literature shows that these lesions are frequently misdiagnosed pre-operatively<sup>2,5,12</sup>.

Based on microscopic appearance spinal hemangiomas are divided into 4 types – cavernous, capillary, arterio-venous and venous with cavernous type being the most common<sup>2,3,5</sup>. Cavernous hemangiomas are composed of collection of thin-walled blood vessels covered with a single layer of flattened endothelial cells forming large, blood-filled vascular spaces separated by fibrous connective tissue septa. There may be evidence of recent or recurrent hemorrhage in the lesion<sup>4,5,6</sup>.

Complete resection is the mainstay of treatment to prevent bleeding and progressive neurological

deterioration<sup>2,3,4,5,6,9,12</sup>. The recurrence rate of these tumors is low with some reports showing no recurrence for 5 years after complete resection<sup>6</sup>. In case of recurrence, redo-surgery is advisable with the aim of complete excision<sup>6</sup>. Tumors with extensive extra-foraminal extension may be difficult to remove completely, and in such cases subtotal resection may be done to relieve cord compression<sup>2,3,4</sup>. However, there are chances of recurrent bleeding in these patients<sup>3,4</sup>. Hence, radiotherapy has been recommended as adjuvant therapy after subtotal resection to minimize chances of further bleeding<sup>2,3,4,6,9,12</sup>. Most patients have a good outcome with functional recovery, even in case of redo surgery for recurrence<sup>2,5,9</sup>.

Conclusion: Spinal Cavernous hemangioma may mimic schwannoma in radiologically, however intraoperative picture will guide us.

**Conflict of Interest:** None

**Source(s) of support:** None

## References

1. Sharma, G., Khadka, N., Jha, R., Adhikari, D. and Bista, P., 2016. Extradural Spinal Tumors: Report of 36 Cases and Review of Literature. *Nepal Journal of Neuroscience*, 13(1), pp.3-10. <https://doi.org/10.3126/njn.v13i1.15905>
2. Zhang, L., Qiao, G., Shang, A. and Yu, X., 2020. Clinical features and long-term surgical outcomes of pure spinal epidural cavernous hemangioma—report of 23 cases. *Acta Neurochirurgica*. <https://doi.org/10.1007/s00701-020-04358-x>
3. Choi, B., Kim, J. and Lee, S., 2018. A Thoracolumbar Pure Spinal Epidural Cavernous Hemangioma: A Case Report. *Journal of Korean Society of Spine Surgery*, 25(4), p.169. <https://doi.org/10.4184/jkss.2018.25.4.169>
4. Sheikhabaei, E. and Andalib, A., 2017. A Dumbbell-Shaped Extradural Intracanal Cavernous Hemangioma: A Rare Case Report and Review of Literature. *Journal of Orthopedic Oncology*, 03(01). <https://doi.org/10.4172/2472-016X.1000116>
5. Narayan S, Kumar K, Singh N, Singh R. An Unusual Long Segment Spinal Epidural Cavernous Hemangioma: A Case Report. *Indian J Musculoskeletal Radiol* 2019;1(2):117-120. [https://doi.org/10.25259/IJMSR\\_23\\_2019](https://doi.org/10.25259/IJMSR_23_2019)
6. Gao, C., Xu, W., Qing Lian, J., Feng, D., Cui, J. and Liu, H., 2018. Spinal Epidural Cavernous Hemangioma: A Clinical Series of 7 Patients. *World Neurosurgery*, 111, pp.e183-e191. <https://doi.org/10.1016/j.wneu.2017.12.006>
7. Sanghvi D, Munshi M, Kulkarni B, Kumar A. Dorsal spinal epidural cavernous hemangioma. *J*

## Spinal Epidural Cavernous Hemangioma Mimicking Schwannoma: Case Report and Review of Literature

- Craniovertebr Junction Spine. 2010;1(2):122-125. <https://doi.org/10.4103/0974-8237.77677>
8. Minh NH. Cervicothoracic spinal epidural cavernous hemangioma: case report and review of the literature. *Surg Neurol.* 2005;64(1):83-85. <https://doi.org/10.1016/j.surneu.2004.10.030>
  9. A L H, T R, Chamarthy NP, Puri K. A pure epidural spinal cavernous hemangioma - with an innocuous face but a perilous behaviour!! *J Clin Diagn Res.* 2013;7(7):1434-1435. <https://doi.org/10.7860/JCDR/2013/6030.3159>
  10. Killeen T, Czaplinski A, Cesnulis E. Extradural spinal cavernous malformation: a rare but important mimic. *Br J Neurosurg.* 2014;28(3):340-346. <https://DOI:10.3109/02688697.2013.841858>
  11. Aoyagi N, Kojima K, Kasai H. Review of spinal epidural cavernous hemangioma. *Neurol Med Chir (Tokyo).* 2003;43(10):471-476. <https://doi:10.2176/nmc.43.471>
  12. Zhang, L., Zhang, Z., Yang, W. et al. Spinal dumbbell-shaped epidural cavernous hemangioma (CM): report of nine surgical cases and literature review. *Chin Neurosurg J* 4, 3 (2018). <https://doi.org/10.1186/s41016-017-0107-2>
  13. Rovira A, Rovira A, Capellades J, Zauner M, Bella R, Rovira M. Lumbar extradural hemangiomas: report of three cases. *AJNR Am J Neuroradiol.* 1999;20(1):27-31
  14. Ozawa, H., Kokubun, S., Aizawa, T., Hoshikawa, T. and Kawahara, C., 2007. Spinal dumbbell tumors: an analysis of a series of 118 cases. *Journal of Neurosurgery: Spine*, 7(6), pp.587-593. <https://doi.org/10.3171/SPI-07/12/587>