


# Unilateral Cranial Polyneuropathy in Herpes Zoster Oticus: Infection teaching us Anatomy



Abdul Qavi *DM*<sup>1</sup>, Ashutosh Tiwari *DM*<sup>2</sup>, Pradeep Kumar Maurya *DM*<sup>3</sup>, Ajai Kumar Singh *DM*<sup>4</sup>, Pradeep Kumar *MD*<sup>5</sup>

<sup>1,2,3,4,5</sup> Department of Neurology, Dr. Ram Manohar Lohia Institute of Medical Sciences, Lucknow, Uttar Pradesh, India

Date of submission: 29<sup>th</sup> May 2020

Date of acceptance: 16<sup>th</sup> November 2020

Date of publication: 1<sup>st</sup> December 2020

## Abstract

Herpes zoster oticus or Ramsay Hunt syndrome is an uncommon neurological manifestation of herpes virus infection causing external ear rash with otalgia and facial nerve palsy. Rarely herpetic infection may present with multiple cranial nerves palsies involving VII, VIII, IX and X cranial nerves.

Here we report a case of herpes zoster oticus with multiple cranial nerve palsy. This case study will help in understanding the dermatomal distribution of cranial nerves with cranial polyneuropathy due to reactivation of neurotropic herpes virus.

Some interesting case reports regarding different cranial nerve involvement in herpetic infection are discussed in the table which helps in understanding the neurotropism of herpes virus.

**Key words:** Cranial Polyneuropathy, Ear rashes, Facial palsy, Herpes Zoster oticus

## Introduction

Herpes zoster oticus or Ramsay Hunt syndrome is an uncommon neurological manifestation of herpes virus infection causing external ear rash with otalgia and facial nerve palsy.<sup>1</sup> Sometimes this herpetic infection may

present with multiple cranial nerves palsies involving VII, VIII, IX and X cranial nerves.<sup>2</sup>

## Case report

A 55 years old man presented to us with right ear pain, deviation of angle of mouth to left side and unsteadiness while walking. First, he developed ear pain and on the next day he noticed rashes around right ear involving pinna. On the same day he developed a nasal twang of voice with nasal regurgitation. He was complaining of tinnitus in right ear with difficulty in walking and swaying on the third day of illness. On examination there was lower motor neuron palsy of right cranial nerve VII with facial deviation to the left side and involvement of right sided cranial nerve VIII including both vestibular and cochlear divisions. Gag reflex on the right side was absent with drooped soft palate depicting right sided cranial nerves IX and X palsies. Local examination revealed herpetic rashes and crust on the right pinna, external ear canal and on right sided soft palate (Figure 1).

There was no neck rigidity and signs of meningeal irritation were absent. On higher mental function examination, the patient was conscious and oriented to time place and persons, alert and following commands with intact memory. Cerebellar examination was normal but the patient had vestibular ataxia. The clinical features of meningitis and/ or encephalitis were absent.

Patient was admitted and Ryle's tube was inserted for feeding and oral medications. In routine blood investigation he was found to be recently diagnosed

### Access this article online

Website: <https://www.nepjol.info/index.php/NJN>

DOI: <https://doi.org/10.3126/njn.v17i3.33129>

### HOW TO CITE

Qavi A, Tiwari A, Maurya PK, Singh AK, Kumar P. Unilateral Cranial Polyneuropathy in Herpes Zoster Oticus: Infection teaching us Anatomy. *NJNS*. 2020;17(3):59-62



<sup>1</sup>ORCID id: 0000-0002-4223-5540

<sup>2</sup>ORCID id: 0000-0002-2311-8891

<sup>3</sup>ORCID id: 0000-0002-6485-7527

<sup>4</sup>ORCID id: 0000-0001-9551-4378

<sup>5</sup>ORCID id: 0000-0001-6407-703X

### Address for correspondence:

Dr. Abdul Qavi,  
Assistant Professor, Department of Neurology,  
Dr. Ram Manohar Lohia Institute of Medical Sciences,  
Lucknow, Uttar Pradesh, India  
E-mail: [drqavi2008@gmail.com](mailto:drqavi2008@gmail.com)  
Phone: +91 9450417111

Copyright © 2020 Nepalese Society of Neurosurgeons (NESON)

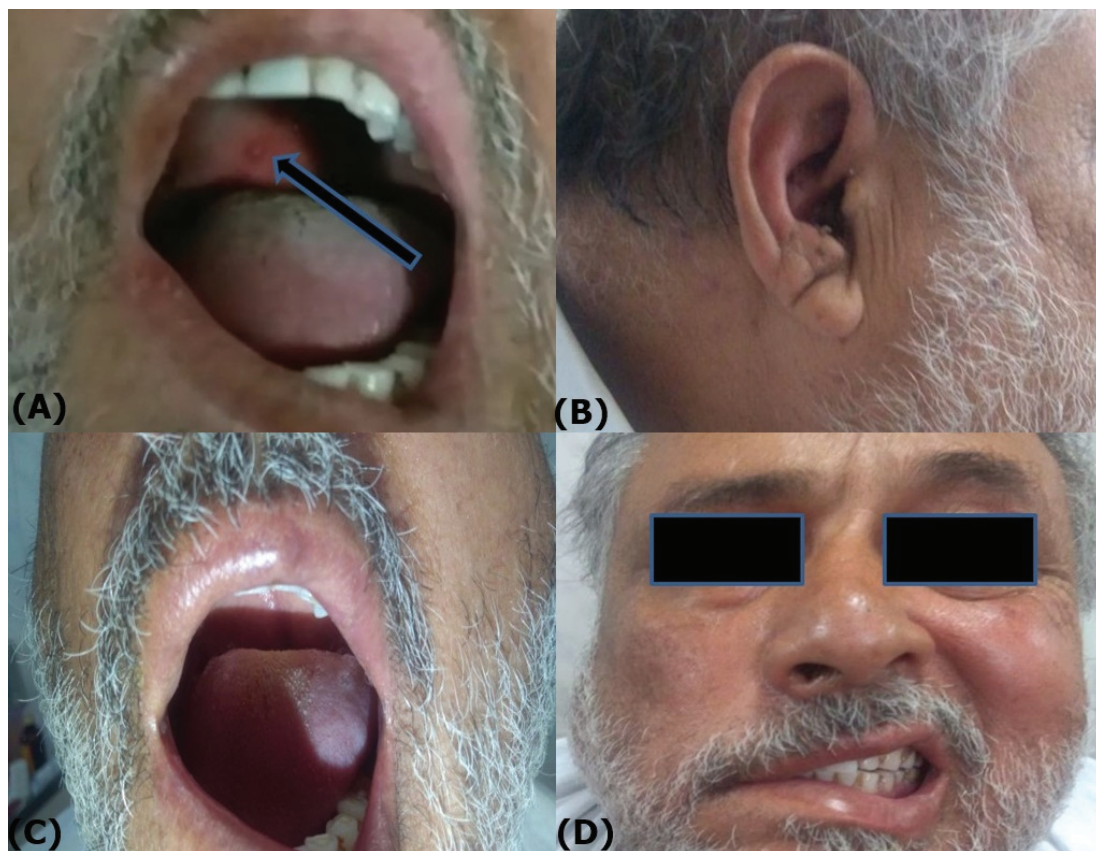
ISSN: 1813-1948 (Print), 1813-1956 (Online)



This work is licensed under a Creative Commons Attribution-Non Commercial 4.0 International License.

diabetes mellitus. His CSF examination was showing lymphocytic pleocytosis (WBC count was 45 cells/mm<sup>3</sup>, polymorphs 10%, lymphocytes 90 %) with slightly raised proteins (95.0 mg/dl) and normal sugar level (82 mg/dl with corresponding blood sugar was 156 mg/dl). CSF was clear watery in appearance and ADA level was 1.1. CSF PCR for Herpes Simplex Virus and Varicella Zoster virus were negative. MRI brain with contrast was also normal without any evidence of meningeal enhancement or parenchymal intensity changes. The abnormality in the CSF examination can be explained by immunological

reaction to reactivation of latent herpes virus infection presenting in the form of Herpes zoster oticus. Patient was treated with antiviral oral valacyclovir 1 gm three times a day for seven days, acyclovir ointment for local application, prednisolone 1 mg/ kg with tapering and oral hypoglycemic agents monitoring sugar levels and physiotherapy. The patient improved symptomatically allowing removal of Ryle's tube and reduction in pain, rashes and gait difficulty in two weeks of treatment. However residual facial palsy was present on the last follow up (three months after discharge).



*Figure 1. (A) Rashes on right palate, (B) Resolving rashes and crusting over pinna and neck, (C) Right palatal palsy, on attempt to phonation flat and drooped right soft palate with median raphe deviated to left, (D) Right sided LMN facial palsy*

## Unilateral Cranial Polyneuropathy in Herpes Zoster Oticus

S.N.	Author	Age/ Sex	Risk Factors/ Co-morbidity	Clinical Features	Cranial Nerve Involved	Treatment given	Remarks
1	Sato K. et al. 1991	56y/ female	none	Right ear and facial pain, respiratory distress, fatigue	V, VII, VIII, IX, X, XI and XII	Ventilatory support, Antiviral, steroid	Improved with late recovery of hoarseness of voice
2	Kikuchi H. et al 1995	50y/ male	none	Left sided tinnitus, hoarseness, dysphagia, facial deviation	Left VII, IX, X, XI and right VII, IX, X	Antiviral, steroid	Improved
3	Xanthopoulos J. et al. 2002	63y/ female	Old age	features of multiple cranial nerve palsy	V, VII, VIII, IX, and XII	Acyclovir, steroid	improved
4	Sugita-Kitajima A et al. 2009	58y/ female	Rheumatic heart disease	Right ear ache, vertigo, swallowing difficulty, hoarse voice	VII, VIII, IX and X	Antiviral, steroid	Improved with late recovery of hoarseness of voice
5	Lauridsen AG et al. 2010	56y/ male	none	Ear rashes, features of multiple cranial nerve palsy	V, VII, VIII, IX, X and XII	Antiviral, steroid	Not available
6	Sun W et al. 2011	-	Diabetes Mellitus	features of multiple cranial nerve palsy	V, VII, VIII, and XII	Insulin, antiviral, steroid	Improved
7	Kim CH. et al 2012	66y/ female	none	Left ear pain and rashes, diplopia, vertigo, facial palsy	VI, VII, VIII	Acyclovir, steroid	improved
8	Coleman C et al 2012	80y/ female		Left sided ear and facial pain, ear rashes, tinnitus, left SNHL, facial deviation	V, VII, VIII, X and XII	Valacyclovir, steroid	improved
9	Patil V. et al. 2014	70y/ male	Old age	Ear rash, headache, facial deviation, hiccups, swallowing difficulty	VII, VIII, IX and X	Valacyclovir, steroid	improved
10	Talukdar J. et al. 2016	66y/ male	hypothyroidism	Ear ache and rashes, swallowing difficulty, change in voice, giddiness	VII, VIII, IX and X	Valacyclovir, steroid	Improved with residual facial weakness
11	Arya D. et al. 2018	29y/ male	Retroviral positive	Headache, facial deviation, gait disturbance, abnormal tongue sensation	V, VII, VIII, IX, X	Valacyclovir, steroid along with continuation of antiretroviral therapy	Symptomatic improvement

*Table 1: Review of some interesting cases of Cranial Polyneuropathy in Herpes Zoster Oticus*

## Discussion

Herpes is a neurotropic virus having the ability to remain dormant in dorsal root and cranial nerve ganglia. The reactivation can cause zoster in a dermatomal distribution usually in elderly, diabetes mellitus and immuno-compromised patients.<sup>3</sup> Sometime due to atypical presentation or involvement of multiple cranial nerves, misdiagnosis occurs. In our case, cranial nerves having fibers of Nucleus Tractus Solitarius, namely VII, IX and X were involved. Small carotid artery branch supplying contiguous cranial nerves, peripheral anastomosis of V, VII, IX and X cranial nerves and cranial nerves neighborhood in cavernous sinus has been considered as the plausible explanations for such presentations.<sup>2,4</sup>

After the Bell's palsy, Ramsay Hunt Syndrome is described in literature as second most common cause of unilateral lower motor neuron type of facial nerve palsy with incidence of 12%.<sup>5</sup> Rarely this Ramsay Hunt Syndrome can present with cranial polyneuropathy involving V, VII, IX and X cranial nerves as shown in some of interesting case reports in Table 1.<sup>1,2,6</sup>

Sharing such cases help us identify simple infections with complex anatomical presentations and simultaneously provide an insight of anatomy and interconnections of cranial nerves.

## Conclusion

Herpes zoster oticus is one of the common causes of unilateral facial palsy and should always be kept as a differential diagnosis of unilateral cranial polyneuropathy

especially in elderly patients and associated with comorbidities. Early and prompt management with antiviral and steroid results a favorable outcome.

**Conflicts of interest:** None

**Source(s) of support:** None

## References

1. Sweeney CJ, Gildea DH. Ramsay Hunt syndrome. *J Neurol Neurosurg Psychiatry*. 2001;71: 149-54. <https://doi.org/10.1136/jnnp.71.2.149>
2. Xanthopoulos J, Noussios G, Papaioannides D, Exarchakos G, Assimakopoulos D. Ramsay Hunt syndrome presenting as a cranial polyneuropathy. *Acta Otorhinolaryngol Belg*. 2002; 56:319-23.
3. Steiner I, Kennedy PG. Herpes simplex virus latent infection in the nervous system. *J Neurovirol*. 1995;1(1):19-29. <https://doi.org/10.1136/jnnp.71.2.149>
4. Kim YH, Chang MY, Jung HH, Park YS, Lee SH, Lee JH, et al. Prognosis of Ramsay Hunt syndrome presenting as cranial polyneuropathy. *Laryngoscope*. 2010;120:2270-6. <https://doi.org/10.1002/lary.21108>
5. A Simon Carney, Herpes Zoster Oticus, Scott-Brown's Otorhinolaryngology, Head and Neck Surgery, Hodder Arnold, 7th edition, 2008, 3379-82. <https://doi.org/10.1201/b15118-275>
6. Patil V, Borkar M, Saoji N. Rare case report of multiple cranial nerve involvement in Ramsay Hunt syndrome. *Egyptian Dermatology Online Journal*. 2014 Jun 1;10(1). <https://doi.org/10.17511/ijmrr.2016.i08.24>