

Anisha Joshi MBBS

Junior Resident, Department of Dermatology
Nepal Medical College Teaching Hospital
Attarkhel, Kathmandu, Nepal
ORCID iD: <https://orcid.org/0000-0001-8316-3259>

Deeptara Pathak Thapa MBBS, MD, FAM

Associate Professor, Department of Dermatology
Nepal Medical College Teaching Hospital
Attarkhel, Kathmandu, Nepal
ORCID iD: <https://orcid.org/0000-0002-1602-415X>

Address for correspondence:

Dr. Deeptara Pathak Thapa
Associate Professor, Department of Dermatology
Nepal Medical College Teaching Hospital
Attarkhel, Kathmandu, Nepal
E-mail: drdeeptarapathak@yahoo.com
Contact number: +977-1-491108

Date of submission: 1st March 2020

Date of acceptance: 19th April 2020

DOI: <https://doi.org/10.3126/njn.v17i1.28369>

HOW TO CITE

Joshi A, Thapa DP. Asymptomatic nodule on face:
Dermoscopic and histopathological clue for diagnosis. NJNS.
2020;17(1):63-65

To access Nepal Journal of Neuroscience Archives,
scan QR code:



Asymptomatic nodule on face: Dermoscopic and histopathological clue for diagnosis

Abstract

Schwannomas/ neurilemmomas are benign tumors of nerve sheath arising from Schwann cells that form myelin sheath around peripheral nerves. They are usually solitary, slow growing and encapsulated lesions. Head and neck are the common sites.

We report a case of a 38 years old Nepalese female who had presented with a solitary asymptomatic, slow growing nodule on the left side of the chin for the last three years. Dermoscopy of the lesion revealed arborizing vessels with brownish pigmentation overlying a whitish to pinkish background. Complete excision of the lesion was performed. Histopathological evaluation of the lesion revealed schwannoma.

Though schwannomas are a rare diagnosis, they should be considered as a differential diagnosis of any unilateral, asymptomatic, slow growing nodule in the head and neck region. Dermoscopy is a useful tool which helps to differentiate schwannoma from other lesions. Histopathology is the gold standard for diagnosis and the treatment of choice is surgical excision.

Key words: Dermoscopy, Histopathology, Schwannomas

Introduction

Schwannoma is a tumor of nerve sheath composed of Schwann cells of peripheral nerve.¹ They are rare neoplasia and are usually single encapsulated lesions most commonly occurring in the 4th and 5th decades¹ affecting both the genders.² They occur in the head and neck region in approximately 25% of the cases.²

Case Report

A 38 years old Nepalese female patient presented to the Dermatology outpatient department (OPD) with a complaint of asymptomatic nodular swelling on the left

side of the chin for the last three years. Initially it was small in size but gradually increased in size within a few months. It was painless without itching or discharge from the lesion. There was no similar history in the past. She had not received any treatment for the condition and there was no similar history in other family members.

On examination, it was rounded, circumscribed, dome-shaped skin colored nodule, 7 mm in size, firm in consistency, non-tender near left side of chin. There was no discharge and ulceration. (Figure 1) Our clinical differential diagnosis was Eccrine poroma, Trichofolliculoma, Dermal mole, Fibroepithelioma of Pinkus (a variant of Basal cell carcinoma) and epidermoid cyst.

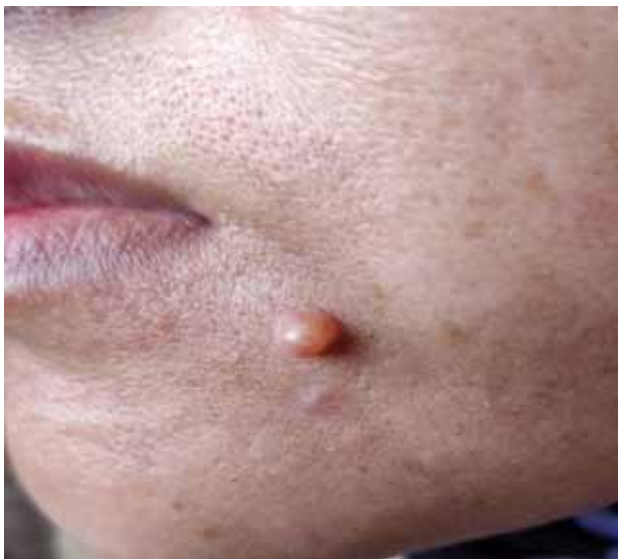

Figure 1: Skin colored, dome-shaped nodule present on the left side of the chin

Dermoscopy of the lesion was done with DermLite DL1, which revealed arborizing vessels with brownish pigmentation overlying a whitish to pinkish background. (Figure 2) The lesion was surgically removed and was sent for histopathological evaluation. Histopathology revealed encapsulated tumor with proliferation of spindle cells in the dermis. There was presence of hypercellular (Antoni A) and hypocellular areas (Antoni B). Hypercellular areas showed spindle shaped cells arranged in fascicles. The cells had elongated to wavy nuclei and fibrillary cytoplasm. Occasional areas of nuclear palisading were also noted but classic Verocay bodies formation were not seen. (Figure 3 A and B)

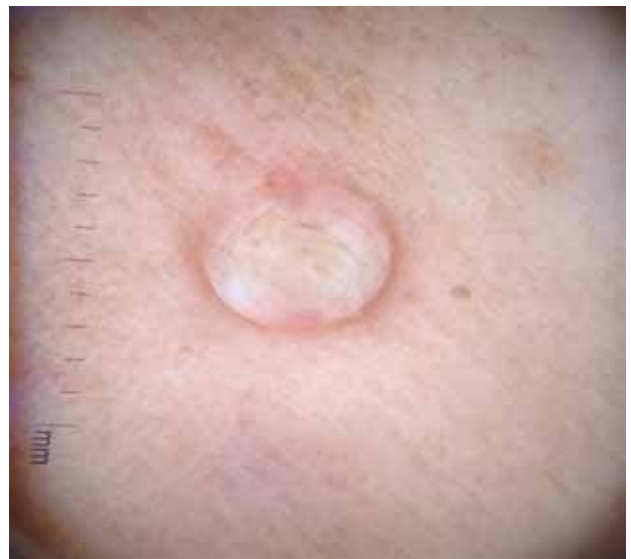

Figure 2: Dermoscopic findings of arborizing vessels with brownish pigmentation overlying a whitish to pinkish background

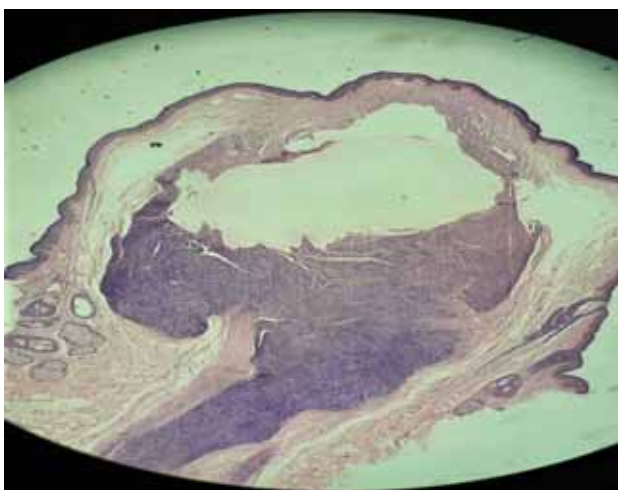


Figure 3A: Hematoxylin and eosin stain, 4X. Histopathology shows encapsulated tumor with proliferation of spindle cells in the dermis. There are presence of hypercellular (Antoni A) and hypocellular areas (Antoni B)

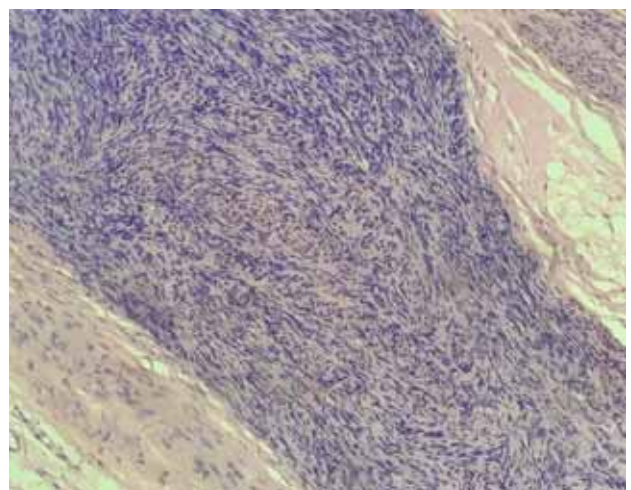


Figure 3B: Hematoxylin and eosin stain, 40X. Histopathology show cells have elongated to wavy nuclei and fibrillary cytoplasm

The histo-pathological features were consistent with schwannoma. The patient was counseled regarding prognosis and advised to follow-up every six months for the first two years.

Discussion

Schwannomas are benign nerve sheath neoplasms that are derived from proliferation of Schwann cells within nerve sheaths and are thus surrounded by a true capsule consisting of epineurium.² Solitary circumscribed neuroma is frequently misdiagnosed as a benign cutaneous tumor that usually can present as an asymptomatic, small nodule measuring 2 to 6 mm, located on the face of an adult.³ However, cases have been described in other locations, including the shoulder, hands, arms, feet and mucosal areas.⁴ The greatest incidence of age group in most of the studies was between third and fifth decades.² They are equally distributed between the genders.² Diagnosis of cutaneous schwannomas are usually done after surgical excision and followed by histopathology.⁵

Dermoscopy is a non-invasive diagnostic technique that helps to visualize morphologic features invisible to the naked eye and also helps to differentiate tumours that mimic Basal cell carcinomas (BCC).^{3,4} In dermoscopy, the characteristic arborising vascular patterns of schwannoma is seen which appear dermoscopically as white patches on a pink-white background.⁴

The exclusive presence of arborizing telangiectasia on a pink-white background as an isolated dermoscopic criterion supports the diagnosis of BCC, adnexal tumors (hidradenoma, cylindroma, and intraepidermal poroma), vascular tumors (angiohistiocytoma, glomangioma, and glomangiomyoma) and intradermal melanocytic nevus.³ However, other than the arborizing vessels as seen in BCC, specific features like maple leaf-like areas, spoke wheel areas, short white streaks (chrysalis), blue-gray ovoid nests, multiple blue-gray globules, in-focus dots and ulcerations were missing in this case.

Palisaded encapsulated neuroma (PEN) also known as solitary palisaded neuroma can clinically present as a solitary flesh colored dome shaped tumor but can be differentiated histopathologically which reveals a well-circumscribed partially-encapsulated intradermal nodule consisting of spindle cells grouped in distinct fascicles which usually lack nuclear pleomorphism and mitosis.³ Dermoscopic features include arborising vessels on a pinkish-reddish background, a central white spot and peripheral pigmentation.

Classical dermoscopic features to support eccrine poroma such as chalice-form and cherry-blossom vessels or structure-less pink-white areas and the absence of halo around the vessels were not seen in this case.^{5,6}

Characteristic histopathology of schwannoma includes spindle shaped cells with poorly defined cytoplasm and elongated wavy basophilic nuclei. The nuclei appear palisading and are arranged in parallel rows with intervening eosinophilic cytoplasm in a typical appearance known as Verocay bodies. Cellular areas known as Antoni A areas are intermixed with areas showing prominent myxoid change known as Antoni B areas.¹ The latter areas are likely to be result of degeneration.¹ S100 is the most widely used marker for peripheral nerve sheath tumors. The tumor cells are positive for S100 protein, HMB45 Melan A (in case of melanotic/pigmented schwannoma) and are EMA negative.⁷ Therefore, dermoscopic clue and histopathologic evaluation after surgical excision remains the gold standard for diagnosis and definitive treatment.

References

1. Calonje E. Soft-tissue tumours and tumour-like conditions. In: Griffiths C, Barker J, Bleiker T, Chalmers R, Creamer D, editors. **Rook's textbook of Dermatology, (9th ed)**. London; Wiley Blackwell. 2016, 4: 137.46- 137.48.
2. Langner E, Negro AD, Akashi HK, Costa Araújo PP, Tincani AJ, Martins AS. Schwannomas in the head and neck: retrospective analysis of 21 patients and review of the literature. **Sao Paulo Med J.** 2007; 125:220-2. <https://doi.org/10.1590/S1516-31802007000400005>
3. Fernández-Crehuet P, Fernández-Crehuet JL, Ruiz-Villaverde R, Sanz-Trelles A. Solitary circumscribed neuroma: A clinical and dermoscopic mimicker of basal cell carcinoma. **Int J Dermatol.** 2015; 54:275–7. <https://doi.org/10.1111/ijd.12828>
4. Fernández-Crehuet P, Ruiz-Villaverde R. Solitary Circumscribed Neuroma Dermoscopic clues to facilitate diagnosis. **Sultan Qaboos Univ Med J.** 2018; 18:116–7. <https://doi.org/10.18295/squmj.2018.18.01.023>
5. Daulatabad D, Gandhi D, Tanveer N, Sharma S, Kaur I. Solitary dome -shaped erythematous lump of long duration on the palm. **Indian J Dermatol Venerol Leprol.** 2018; 84:437-9. https://doi.org/10.4103/ijdv.IJDVL_845_16
6. Ferrari A, Buccini P, Silipo V, De Simone P, Mariani G, Marena S, *et al.* Eccrine poroma: A clinical-dermoscopic study of seven cases. **Acta Derm Venereol.** 2009; 89:160-4. <https://doi.org/10.2340/00015555-0608>
7. Megahed M. Palisaded encapsulated neuroma (solitary circumscribed neuroma): A clinicopathologic and immunohistochemical study. **Am J Dermatopathol.** 1994; 16:120-5. <https://doi.org/10.1097/00000372-199404000-00002>