

ORIGINAL ARTICLE

Outcome of fixation of acromioclavicular joint dislocation type-iii with clavicular hook plate.

Pabin Thapa¹, Krishna Sapkota², Niraj Ranjeet², PR Onta³, K Wahegaonkar⁴, UJ Thapa³

¹Lecturer, Department of Orthopaedics, MTH, Pokhara

² Associate Professor, Department of Orthopaedics, MTH, Pokhara

³ Assiatant Professor, Department of Orthopaedics, MTH, Pokhara

⁴ Professor, Department of Orthopaedics, MTH, Pokhara

Received: November 15, 2019

Accepted: December 30, 2019

Published: February 15, 2020

How to cite this article:

Thapa P, Sapkota K, Ranjeet N et al. Outcome of fixation of acromioclavicular joint dislocation type-iii with clavicular hook plate. *Nepal Journal of Medical Sciences* 2020;5(1):45-52

ABSTRACT

Introduction: Acromioclavicular (AC) joint dislocation is one of the most common shoulder injuries accounting for approximately 9-12% of all shoulder girdle injuries. Rockwood classification of AC joint dislocation is the most widely accepted classification system which classifies the injury into six types. Surgical management with open reduction and fixation with clavicular hook plate without the repair of coracoclavicular ligament has proved to be one of the best treatment options for Type III AC joint dislocations.

Methods: Twenty-three patients with Rockwood Type III AC joint dislocation were included in the study. Open reduction was done and the fixation was done with the clavicular hook plate. The functional outcomes were assessed before and two months after the implant was removed using the Constant- Murley Score.

Results: A total of 23 patients were included in the study with the mean age of 30.74 years. The plates were removed on an average of 6.43 months and mean follow up was 8.83 months. The functional outcome was assessed using the Constant- Murley Shoulder score. The pain scores were significantly better after the implant removal was done ($p= 0.007$). The final mean constant score was 74.6 ± 4.11 before removal and 93.91 ± 2.71 after implant removal and all the 23 patient had excellent result (>90 points).

Conclusions: The pre-contoured clavicular hook plate has proved to be a good implant option in the fixation of Rockwood Type III AC joint dislocation without the need of any ligamentous repair

Key words: *Acromioclavicular joint; Dislocation; Hook plate; Rockwood Type III.*

Correspondence: Pabin Thapa, Lecturer in Orthopaedics, MCOMS, Pokhara.
Email: drpabin@gmail.com



Licensed under CC BY 4.0 International License which permits use, distribution and reproduction in any medium, provided the original work is properly cited

INTRODUCTION

Acromioclavicular (AC) joint dislocation is one of the most common shoulder injuries accounting for approximately 9-12% of all shoulder girdle injuries.[1-3] These injuries often occur in younger population and up to 43.5% sustain AC joint dislocation after direct trauma to the shoulder.[4,5] Rockwood classification of AC joint dislocation is the most widely accepted classification system which classifies the injury into six types according to the extent of displacement of clavicle in relation to the acromion.[6,7] Type I and II are incomplete injuries which can be managed conservatively with a short period of immobilization with bandage or sling. Due to severe instability in Type IV, V and VI, operative management is widely accepted as it provides anatomical reduction, stability and restores joint anatomy.[8,9] The debate remains in the treatment of Type III injuries as both good to excellent results has been obtained with the non-operative treatment. However, some authors have reported persistent pain and chronic instability with conservative treatment. Thus to restore the anatomy of the AC joint and to improve the functional outcome surgical treatment has been advocated for Type III injuries as well.[10-12] Numerous surgical options are available to treat acute AC joint dislocations which includes extra-articular or trans-articular Kirschner wires, Tension band wiring, Knowels pins, Coracoclavicular screws, the modified Weaver-Dunn procedure and the clavicular hook plates.[13-15] Open surgical technique has been the workhorse for the anatomical reconstruction of the AC joint dislocation so far, but recent advances have led to the possibilities of minimal invasive percutaneous fixation or even the arthroscopic assisted reconstructions.[16,17] Currently 44% of the surgeons prefer open reduction and clavicular hook plate fixation for the Type III AC joint dislocations.[18,19]

Clavicular hook plates are pre-contoured plates with different sizes, varying depth of hook and sides to fit anatomically in the shoulder. Once the joint is reduced the hook is placed under the acromion posteriorly and the plate is fixed with screws on the lateral end of the clavicle.[2,14,15] Many Studies have proven this implant to be an effective device for the treatment of Type III injuries but few adverse effects such as the acromial osteolysis, subchondral impingement, osteoarthritis and even possibility of rotator cuff tears has been mentioned. Thus to prevent these complications it has been recommended to remove the plates on time preferably after three months of surgery.[2,14,15,19]. We did a prospective study to see the outcome of fixation of the AC joint dislocation Type III by clavicular hook plate without acromioclavicular or coracoclavicular ligament repair.

METHODS

A prospective study was conducted from Jan, 2016 to Jan, 2018 in the patients admitted for AC joint injuries in the department of Orthopaedics, Manipal Teaching Hospital, Nepal. The study was done after the approval from the hospital's Ethical Committee. The inclusion criteria were as follows: Age \geq 18 years, Isolated acute Rockwood Type III injury (trauma \leq 2 weeks). The exclusion criteria were any previous shoulder pathology, Open injury, Polytrauma, Neurovascular injury, Chronic AC joint dislocation or other type of acute AC dislocations. Informed consent was taken from all patients included in the study. All admitted patients had antero-posterior and a stress view x-rays of the affected shoulder. The injuries were classified using Rockwood classification.

The operations were done in beach chair position under general anesthesia. A bottle of intravenous fluid was placed under the ipsilateral shoulder to make the shoulder prominent. Skin incision about 5-7 cm long was made along the Langer's skin line two to three cm medial to the AC joint. Full thickness sub periosteal flap was made and the periosteum, delto-trapezius fascia and the capsule were incised to expose the AC joint and the lateral end of the clavicle. The dislocation was reduced and an appropriate sized hook plate was inserted underneath the acromion and the plate was fixed with screws on the lateral end of the clavicle. Repair or reconstruction of the acromioclavicular or coracoclavicular ligament was not done. Shoulder range of motion was done to ensure that there was no impingement intraoperatively.

Postoperatively, arm sling was used for two weeks and range of motion exercises was started after two weeks. The patients were followed up every month of the first six months and every three months thereafter. The patients were advised to remove the implants after three months of surgery. Shoulder radiographs were obtained at three months, before removal of implant and at final follow up to see the congruency of the AC joint and or any complications like acromial osteolysis.(Figure1) The functional outcome was assessed before and two months after the implant removal using the Constant-Murley Score.[20,21] Here two subjective variables included pain and limitation of activities of daily living and two objective variables included range of motion and power of the shoulder. The absence of pain was given a maximum of 15 points; no limitation of activities of daily living was allocated a maximum of 20 points. Range of motion which included forward flexion, lateral elevation, external and internal rotation scored a maximum of 40 points and the power of shoulder was 25 points. The total Constant-Murley shoulder score was 100 and results were excellent (86-100 points), good (71-85 points), fair (56-70 points) and poor (<56 points). Statistical analysis was done using SPSS 16.0. The scores before removal and after removal of implant were subjected to paired t-test and p value < 0.05 was considered statistically significant.

RESULTS

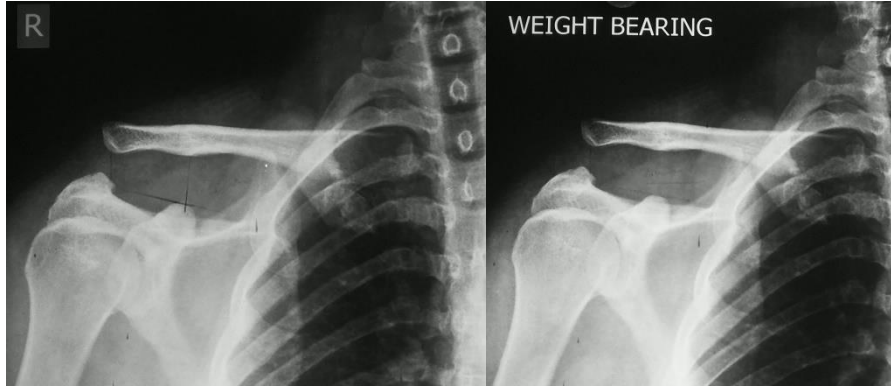
A total of 33 patients with acute Rockwood Type III AC joint dislocation were enrolled in the study. Five patients did not follow up at all and 3 patients who had implant removed but lost for the final follow up. Thus only 23 patient who underwent clavicular hook plate fixation, implant removed and did the final follow up were finally evaluated.

There were 17 (73.9%) male and 6 (26.1%) female with the mean age of 30.74 years (range 19-51years). We had total of 16 (69.6%) right sided and 7 (30.4%) left sided Type III AC joint dislocations. The mechanism of injury include fall from height (n =9), motor vehicle accident (n=8) and sports injuries (n=6). On an average the plates were removed at 6.43 months (range 5 to 11 months) from the day of surgery. The mean follow up was 8.83 months (range 7 -13 months). We only had one incidence of acromial osteolysis. The functional outcome was assessed using the Constant- Murley Shoulder score for pain, limitation of activities of daily living, range of motion and power of the shoulder before and after the implant removal was done. (Table 1)

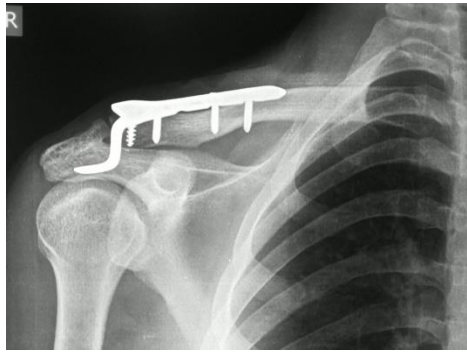
Table 1: Functional outcome according to Constant –Murley Shoulder score

Parameter	Before Implant	After Implant
	Removal (mean±SD)	Removal (mean±SD)
Pain	10.87 ± 3.58	13.48 ± 2.35
Activities of daily living	15.48 ± 2.25	18.78 ± 0.90
Range of motion	27.65 ± 2.31	37.30 ± 1.87
Power	20.65 ± 1.58	24.35 ± 0.88
Constant score	74.65 ± 4.11	93.91 ± 2.71

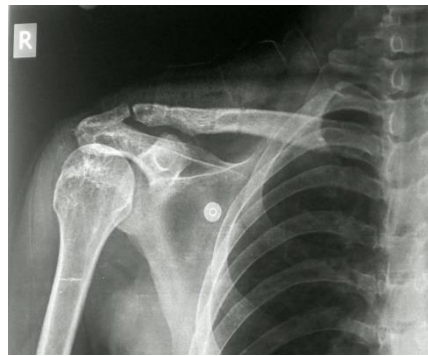The pain score and the final constant were significantly better after the implant removal was done (p= 0.007 and p=0.000 respectively). The final mean constant score was 74.6 ± 4.11 before removal and 93.91 ± 2.71 after implant removal and all patients had excellent result (>90 points).



a. Pre op X-ray



b. Follow up before removal



c. After implant removal

Figure 1: AC joint dislocation fixed with clavicular hook plate

DISCUSSION

AC joint dislocations are relatively common shoulder injuries. However, there has been no established gold standard treatment protocol specially for the Rockwood Type III injuries.[2,9,11,13] Many authors have recommended operative management for the Type III injuries as it showed better functional outcomes.[4,12,13,19] Many implants are mentioned for the fixation of the AC joint dislocation after reduction like Kirschner wires, Coracoclavicular screws or Suspensory loop devices like tightrope or endo-buttons. But a number of studies have shown that the clavicular hook plate is an effective implant for the fixation of the Type III AC joint dislocation.[1,5,13,14] Still an issue regarding whether or not to repair the coracoclavicular ligament is present as studies have not demonstrated any significant differences between the outcomes of repaired or non-repaired torn ligaments. Good to excellent functional outcomes

were achieved in Type III AC joint dislocations which were fixed with clavicular hook plate without repair of the coracoclavicular ligament and our study also had similar results.[2,4,15] Many authors have cited that the major disadvantage of using a clavicular hook plate have been repeat surgery for implant removal, persistent shoulder pain, acromial osteolysis, sub acromial impingement and even rotator cuff tears.[3,5,14] In our study except for one case of acromial osteolysis no other complications were observed. It was probably due to the implant retention by the patient for a period of 11 months. Timely removal of the implant may be a solution to avoid such a complication. The AC joint is kept reduced with the hook plate during the time necessary for the biological healing of the ligaments as it works as an internal splint. Thus, it is generally recommended to remove the implant as soon as the bony union and/or ligamentous healing is achieved and that is around 3 months after the initial surgery. Cases with timely removed implants have shown better functional outcomes and lesser complication which is comparable in many literatures as well as in our study.[1,14,15,19]

Early restoration of the joint function and return to the pre injury level of activities is the main goal of the surgical intervention in the Type III AC joint dislocations. Such injuries would benefit with early reduction and fixation with hook plate followed by timely removal of implant in young active patients. This was evident from the studies done by Kumar N et. al and Steinbacher G et. al which had the final Constant score of ≥ 90 in 57% and 73.7% of cases respectively.[2,4,13] These results were comparable to ours where we had excellent results and the final mean Constant score was 93.9 in all the 23 cases.

The limitation of our study is a relatively small number of cases and an absence of control group. Further, a longer duration of follow up was required to see for the long term complications.

CONCLUSION

The pre-contoured clavicular hook plate has proved to be a good implant option in the fixation of Rockwood Type III AC joint dislocations without the need of any ligamentous repair. Timely removal of the implant, preferably after three months of surgery ensures better functional outcome and lessen the number of complications as well

CONFLICT OF INTEREST

None

SOURCES OF FUNDING

None

REFERENCES

1. Arirachakaran A, Boonard M, Piyapittayanun P, et al. Post-operative outcomes and complications of suspensory loop fixation device versus hook plate in acute unstable acromioclavicular joint dislocation: a systematic review and meta-analysis. *Journal of Orthopaedics and Traumatology*. 2017 Dec;18(4):293.
2. Kumar N, Sharma V. Hook plate fixation for acute acromioclavicular dislocations without coracoclavicular ligament reconstruction: a functional outcome study in military personnel. *Strategies in Trauma and Limb Reconstruction*. 2015 Aug 1;10(2):79-85.
3. Ye G, Peng CA, Sun HB, et al. Treatment of Rockwood type III acromioclavicular joint dislocation using autogenous semitendinosus tendon graft and endobutton technique. *Therapeutics and clinical risk management*. 2016;12:47.
4. Steinbacher G, Sallent A, Seijas R, et al. Clavicular hook plate for grade-III acromioclavicular dislocation. *Journal of Orthopaedic Surgery*. 2014 Dec;22(3):329-32.
5. Kienast B, Thietje R, Queitsch C, et al. Mid-term results after operative treatment of rockwood grade III-V Acromioclavicular joint dislocations with an AC-hook-plate. *European Journal of Medical Research*. 2011;16(2):52-56.
6. Edgar C, DeGiacomo A, Lemos M J. Acromioclavicular Joint Injuries. In: Rockwood and Green's Fractures in Adults. Volume 1. 8th ed. Philadelphia: Wolters Kluwer Health, 2015: 1573-1606
7. Kovilazhikathu Sugathan H, Dodenhoff RM. Management of type 3 acromioclavicular joint dislocation: comparison of long-term functional results of two operative methods. *ISRN surgery*. 2012 Jun 13;2012.
8. Kim S, Blank A, Strauss E. Management of Type 3 Acromioclavicular Joint Dislocations. *Bulletin of the Hospital for Joint Diseases*. 2014 Jan 1;72(1).
9. De Carli A, Lanzetti RM, Ciompi A, et al. Acromioclavicular third degree dislocation: surgical treatment in acute cases. *Journal of orthopaedic surgery and research*. 2015 Dec;10(1):13.
10. Gao YS, Zhang YL, Ai ZS, et al. Transarticular fixation by hook plate versus coracoclavicular stabilization by single multistrand titanium cable for acute Rockwood grade-V acromioclavicular joint dislocation: a case-control study. *BMC musculoskeletal disorders*. 2015 Dec;16(1):360.
11. Ceccarelli E, Bondi R, Alviti F, et al. Treatment of acute grade III acromioclavicular dislocation: a lack of evidence. *Journal of Orthopaedics and Traumatology*. 2008 Jun 1;9(2):105-8.
12. Smith TO, Chester R, Pearse EO, et al. Operative versus non-operative management following Rockwood grade III acromioclavicular separation: a meta-analysis of the current evidence base. *Journal of orthopaedics and traumatology*. 2011 Mar 1;12(1):19-27.

13. Dou Q, Ren X. Clinical therapeutic effects of AO/ASIF clavicle hook plate on distal clavicle fractures and acromioclavicular joint dislocations. *Pakistan journal of medical sciences*. 2014 Jul;30(4):868.
14. Lin HY, Wong PK, Ho WP, et al. Clavicular hook plate may induce subacromial shoulder impingement and rotator cuff lesion-dynamic sonographic evaluation. *Journal of orthopaedic surgery and research*. 2014 Dec;9(1):6.
15. Dawood Jafary HK, Mazhar FN, Zadeh HS, et al. Clinical and radiological results of fixation of acromioclavicular joint dislocation by hook plates retained for more than five months. *Trauma monthly*. 2014 Apr;19(2).
16. Acar MA, Güleç A, Erkocak OF, et al. Percutaneous double-button fixation method for treatment of acute type III acromioclavicular joint dislocation. *Acta Orthop Traumatol Turc*. 2015 Jan 1;49(3):241-8.
17. Gille J, Heinrichs G, Unger A, et al. Arthroscopic-assisted hook plate fixation for acromioclavicular joint dislocation. *International orthopaedics*. 2013 Jan 1;37(1):77-82.
18. Horst K, Garving C, Thometzki T, et al. Comparative study on the treatment of Rockwood type III acute acromioclavicular dislocation: clinical results from the TightRope® technique vs. K-wire fixation. *Orthopaedics & Traumatology: Surgery & Research*. 2017 Apr 1;103(2):171-6.
19. Chen CH, Dong QR, Zhou RK, et al. Effects of hook plate on shoulder function after treatment of acromioclavicular joint dislocation. *International journal of clinical and experimental medicine*. 2014;7(9):2564.
20. Cetinkaya E, Arıkan Y, Beng K, et al. Bosworth and modified Phemister techniques revisited. A comparison of intraarticular vs extraarticular fixation methods in the treatment of acute Rockwood type III acromioclavicular dislocations. *Acta orthopaedica et traumatologica turcica*. 2017 Dec 1;51(6):455-8.
21. Constant CR, Murley AH. A clinical method of functional assessment of the shoulder. *Clinical orthopaedics and related research*. 1987 Jan(214):160-4.