MASTOID CAVITY OBLITERATION IN CHILDREN

Guragain R P

Ganesh Man Singh Memorial Academy of ENT and Head & Neck Studies, IOM, TU Teaching Hospital, Maharajgunj, Kathmandu, Nepal

Correspondence to:
Prof. Rajendra Guragain
Ganesh Man Singh Bhawan,
TU Teaching Hospital, Maharajgunj,
Kathmandu, Nepal
e-mail: professorrajendraguragain@hotmail.com

Keywords: canal down mastoidectomy, mastoid cavity obliteration, musculoperiosteal flap

Management of cholesteatoma in developing countries is usually by canal down mastoidectomy, thus offering a mastoid cavity for rest of the life of patients. The open mastoid cavity has several problems which can be avoided by obliterating the cavity in a same sitting while performing canal down technique or can be done later.There are various techniques by which we can obliterate the cavity. Principle behind each method is almost the same. The cavity is filled (fillers) and is lined by fascia. The fillers we use are bone chips, bone dusts and inferiorly based musculoperiosteal flap. The filled part on the canal side is covered by temporalis fascia.

Fig.1: Showing postaural incision

Here I describe the technique of mastoid cavity obliteration in children in my department under general anesthesia. Postaural incision slightly posterior and parallel to postauricular grove is given. Temporalis muscle and fascia are exposed and temporalis fascia graft is taken from upper part of the exposure, keeping the fascia intact in lower part to create a flap for obliteration.

Fig. 2 : Showing harvested temporalis fascia and bone chips

About 2 mm width flap from posterior wall of EAC towards occipital region, based inferiorly on the mastoid process and superiorly going few mm superior to upper attachment of pinna is fashioned.

Fig. 3 : Showing harvested bone dust

Fig. 4 : Showing fashioned inferiorly based musculoperiosteal flap

The flap contains subcutaneous tissue and periosteum in lower part and temeporalis fascia muscle and periosteum in upper part . The flap is turned inferiorly loosely wrapped in a wet gauge.

Fig. 5 : Showing mastoid cavity after obliteration

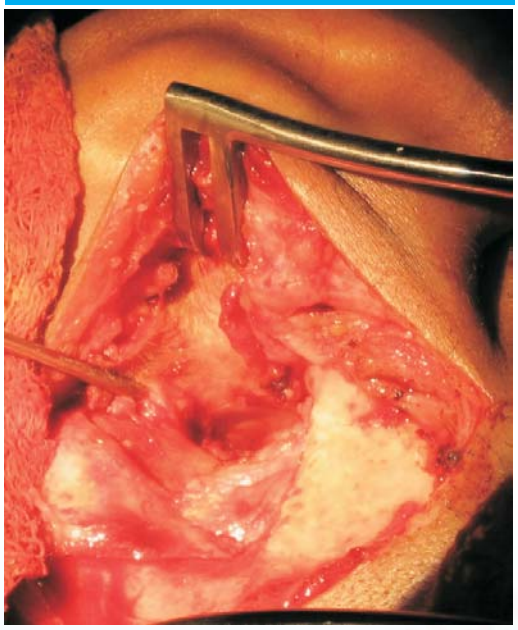

Canal down mastoidectomy is performed with the following differences. The normal mastoid cortical bone is preserved by collecting with a gouge and hammer. Bone dust is collected while drilling normal bone. The cavity is not saucerised. The posterior canal is not over enthusiastically lowered.

Fig. 6 : Showing repositioning of flap over the filled mastoid cavity

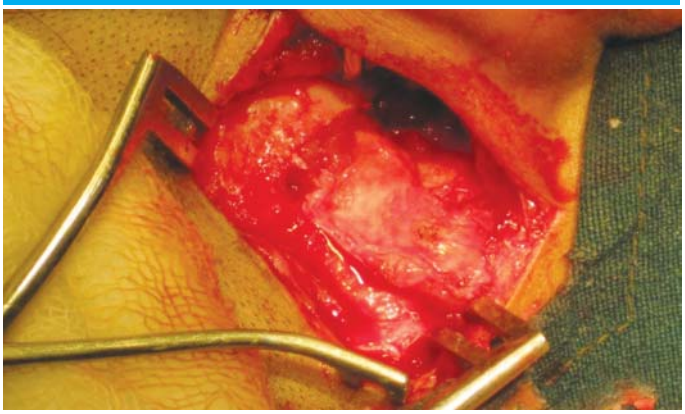

After eradicating disease from middle ear cleft, the attic and posterior canal wall are reconstructed by sculpturing the cortical bone and the rest of mastoid is obliterated by putting pieces of cortical bones and bone dust. The inferiorly based musculoperiosteal flap is placed over the bone clips and dust filled cavity. The temporalis fascia after reconstructing the tympanic membrane covers the EAC side of the reconstructed attic, bony canal wall and flap. The canal is packed with BIPP. The wound is closed in usual fashion. No meatoplasty is fashioned.

Fig. 6 : Showing temporalis fascia after reconstructing the TM covering the EAC side of reconstructed attic, bony canal wall and flap

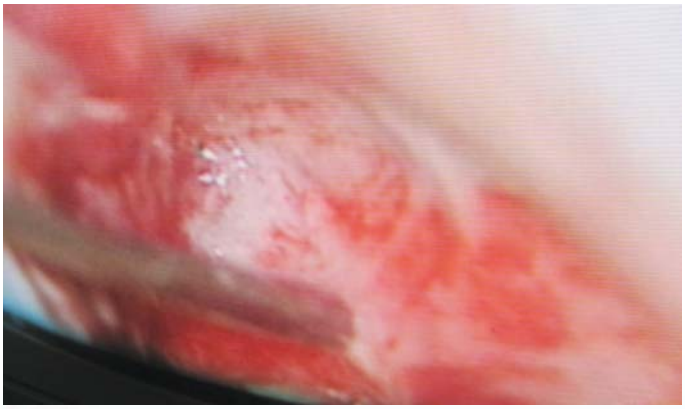

The patient is put on antibiotic for a week . Sutures are taken out on 7th post operative day and the ear pack is removed on 2 weeks, after which antibiotic ear drop is prescribed for 2 week.

The long term results are yet to be seen. But 3 years follow up in 20 patients so far reveals early healing up of canal and middle ear as compared to open mastoid cavity. No major complications have been observed so far.