

Shrestha Kundan Kumar
Jha Anil Kumar
Joshi Rupesh Raj
Rijal Anupama Shah
Dhungana Anup
Regmi S
Amatya A

Department of Otolaryngology & Head and Neck Surgery
Nepal Medical College Teaching Hospital, Kathmandu, Nepal

Correspondence to:

Dr. Kundan Kumar Shrestha
Department of Otolaryngology & Head and Neck Surgery
Nepal Medical College Teaching Hospital, Attarkhel, Jorpati, Kathmandu, Nepal;
email: kundanshrestha9@hotmail.com

AN UNUSUAL PRESENTATION OF THYROID GLAND CARCINOMA: A CASE REPORT

ABSTRACT

Thyroid disorder is a common clinical presentation in our day to day Otolaryngology and Head and Neck Surgery (ENT and HNS) practice. Papillary thyroid carcinoma (PTC) and medullary thyroid carcinoma (MTC) have always been considered different from each other; in their incidence, their cell origin and their histopathological features. The simultaneous occurrence of PTC and MTC in the same thyroid gland is rather rare. We are presenting a case of a 75 year old gentleman from Sindhupalchowk who came with history of swelling in front of neck for 20 years. Computer Tomography (CT) scan of the neck showed features consistent with huge colloid goiter without local invasion. Fine needle aspiration cytology (FNAC) showed features of mixed papillary and medullary carcinoma. Near total thyroidectomy was performed. Post operative histopathological examination (HPE) showed poorly differentiated carcinoma with features of papillary and medullary carcinoma.

Keywords: Thyroid, Papillary carcinoma, Medullary carcinoma, Collision tumor.

INTRODUCTION:

Thyroid cancer is the most common endocrine tumor with an incidence ranging from 1.2-3.8/100,000 cases per year in the UK. It has a favourable outlook in comparison to most other solid tumors, and accounts for less than 0.5% of the cancer deaths¹. PTC accounts for around 81 percent of all thyroid cancers whereas medullary cancer accounts for around 5 percent. Concurrent occurrence of both PTC and MTC is rare. We present a case of such unusual presentation of thyroid cancer that came to ENT and HNS outpatient department (OPD) of Nepal Medical College Teaching Hospital (NMCTH).

CASE REPORT:

A 75 year old gentleman from Sindhupalchowk came to ENT OPD of NMCTH with swelling in front of the neck for 20 years. It was insidious in onset and gradually progressive. It was associated with pain in the neck while walking and difficulty in breathing in supine position for past 2 months. There was no history suggestive of hyper or hypothyroidism.

On examination of neck, there was a single, smooth, globular mass around 20x15cm, firm to hard in consistency, extending laterally to the anterior

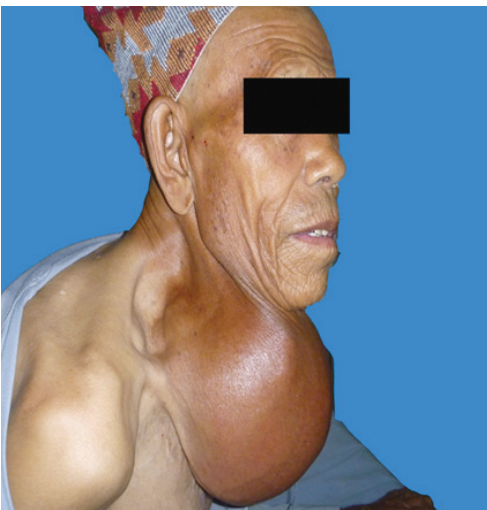

Fig. 1: Clinical presentation of the patient in OPD

border of sternocleidomastoid on both sides, superiorly to body of the mandible and inferiorly to the clavicle on both sides (Fig 1) which moved with deglutition. There were two cervical lymph nodes on right side, corresponding to level III (between the carotid bifurcation

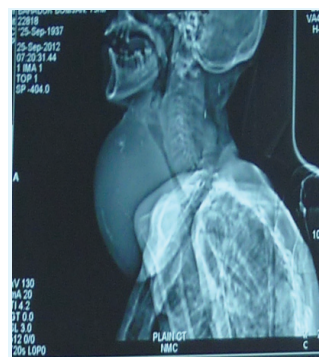

Fig. 2: CT scan of the patient (Sagittal view)

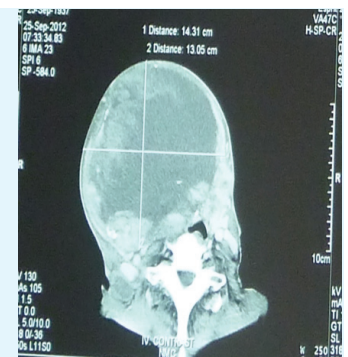


Fig. 3: CT scan of the patient (Axial view)

above and omohyoid muscle below), each measuring 3x2 cm, firm in consistency and mobile laterally.

The patient was worked up in NMCTH. Thyroid function tests were normal. Ultrasound neck showed a large hypoechoic lesion. CT scan of the neck was done which showed a large swelling in the anterior neck without evidence of local invasion and right cervical lymphadenopathy (Fig. 2 and 3). FNAC was consistent with malignant tumor with mixed features of medullary and papillary carcinoma of thyroid.

Total thyroidectomy with excision of level III & VI lymph nodes was done (Fig. 4 and 5). Post operative period was uneventful. Biopsy report suggested poorly differentiated carcinoma with features of papillary and medullary carcinoma. In view of the HPE report, patient was advised for further neck dissection but refused. The patient was then advised for chemoradiotherapy and discharged on day 10.

DISCUSSION:

Papillary thyroid carcinoma (PTC) and medullary thyroid carcinoma (MTC) are two different thyroid neoplasia. The former originates from thyroglobulin-producing follicular cells, whereas the latter arises from calcitonin-producing cells. MTC is a rare tumor that arises from neural crest-derived parafollicular C cells. The coexistence of PTC and MTC has been reported in the literature. Tumors showing both features

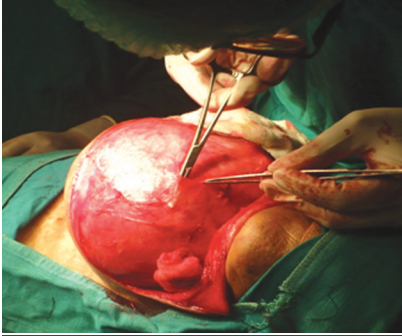


Fig. 4: Patient undergoing total thyroidectomy with excision of level III and VI nodes

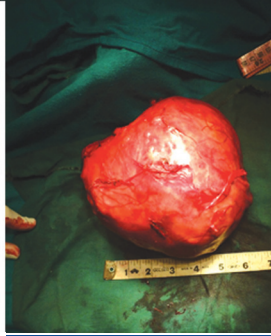


Fig. 5: Post surgery specimen

are rare and represent less than 1% of all thyroid malignancies.² They have different patterns of clinical presentation and biological behavior. The simultaneous occurrence of MTC and PTC in the same thyroid is a rare phenomenon that can be observed in two main settings: a mixed tumor showing dual differentiation or a collision tumor (that is, a tumor with two separate and different components).^{2,3} These tumors occurred together more frequently in women, presented with a palpable neck mass, and were treated with surgery. In our case, however, the patient was an elderly male. Kim et al⁴ have compared the concurrent occurrence rate of PTC in MTC patients with that in Grave's disease (GD) and follicular thyroid carcinoma (FTC) patients and have concluded that the simultaneous occurrence of MTC/PTC is generally a simple reflection of incidental papillary microcarcinoma. Older patients tend to have more aggressive thyroid cancers so surgical thyroidectomy should not be delayed. Age itself should not be a contraindication to surgery when indicated on clinical backgrounds.⁵ Lin et al⁶ conducted a retrospective analysis of 204 thyroid cancer patients aged 60 years and older, however, they have not commented upon the simultaneous occurrence of papillary and medullary thyroid carcinoma in their study.

CONCLUSION:

The concomitant occurrence of papillary thyroid carcinoma and medullary thyroid carcinoma and the exact diagnosis of this uncommon event are important. Whenever encountered, even in older age group, surgical thyroidectomy should be considered. Age itself should not be a contraindication to surgery when indicated on clinical backgrounds.

REFERENCES:

1. Ramsden J, Watkinson JC. Thyroid Cancer. In: Gleeson M, editors. Scott-Brown's Otorhinolaryngology, Head and Neck Surgery. 7th edition. Great Britain. Hodder Arnold; 2008: 2663-2701.
2. Rossi S, Fugazzola L, De Pasquale L, Braidotti P, Cirello V, Beck-Peccoz P, Bosari S, Bastagli A: Medullary and papillary carcinoma of the thyroid gland occurring as a collision tumour: report of three cases with molecular analysis and review of the literature. *Endocr Relat Cancer* 2005, 12:281-289.
3. Gero MJ, Lipper S, Chernys AE, Silver L: Medullary and papillary carcinomas occurring as a collision tumor: report of a case. *Clin Nucl Med* 1989, 14:171-174.
4. Kim WG, Gong G, Kim EY, Kim TY, Hong SJ, Kim WB, Shong YK: Concurrent occurrence of medullary thyroid carcinoma and papillary thyroid carcinoma in the same thyroid should be considered as coincidental. *Clin Endocrinol (Oxf)*. 2010 Feb; 72(2):256-63.
5. Grogan RH, Mitmaker EJ, Hwang J, et al. A population – based prospective cohort study of complications after thyroidectomy in the elderly. *J Clin Endocrinol Metab*. 2012; 97: 1645-53.
6. Lin JD, Chao TC, Chen ST, et al. A Characteristics of thyroid carcinomas in aging patients. *A Eur J Clin Invest*. 2000; 30: 147-53.

