

<https://doi.org/10.3126/njdv.v18i1.25996>

Mucopolysachharidosis-II: A Rare Case Report

Kalgi Baxi¹, Ashish Jagati², Pooja Agarwal³

¹Senior resident, Department of Dermatology, GCS Medical College, Ahmedabad, Gujarat, India, ²Associate Professor, ³Assistant Professor, Department of Dermatology, Shardaben Hospital and NHL medical college, Ahmedabad, Gujarat, India

Abstract

Mucopolysaccharidosis belongs to a group of metabolic disorders caused by absence or defective activity of lysosomal enzymes. Mucopolysaccharides are major components of intercellular connective tissue and defect in their metabolism leads to an accumulation of incompletely degraded mucopolysaccharides in the lysosomes which affect various body systems through enzymatic activity. We present a case of mucopolysaccharidosis type II with hallmark cutaneous features, mild mental retardation associated with radiological changes.

Key words: Glycosaminoglycans; Iduronic Acid; Lysosomes; Mucopolysaccharidosis II

Introduction

Mucopolysaccharidosis type II (MPS II) or Hunter syndrome is an, X linked recessive, inborn error of metabolism. It belongs to the subgroup of diseases caused by lysosomal accumulation.¹ The primary defect is a mutation of the IDS gene which causes a deficiency in the activity of the lysosomal enzyme iduronate-2-sulfatase (I2S).² This leads to the accumulation of glycosaminoglycans in the tissues, leading to multiorgan dysfunction. The clinical features of this disease manifest between the ages of two and four years. Airway obstruction and heart failure due to valve dysfunction are the most common causes of death, with an average life expectancy of 15 years.³ We present a case of mucopolysaccharidosis type II with cutaneous features and radiological changes.

Case Report

A six-year-old boy presented to the outpatient department with asymptomatic, bilaterally symmetrical skin colored papules over scapular region, arms, and thighs. [Figure 1a] He had gradual abdominal distension which was progressive and breathlessness.

Financial disclosure: None.

Conflict of interest to disclosure: None declared.

Address of Correspondence

Dr. Ashish Jagati

Associate Professor

Department of Dermatology

Smt SCL Hospital and NHL Municipal Medical College, Ahmedabad, Gujarat, India

E-mail: jagatiashish@gmail.com

He had coarse facial features, depressed nasal bridge, and small stubby fingers with flexion deformity and stiffness of all the large joints. [Figure 1b] His head circumference was 53.4 cm at occipital protuberance, suggestive of macrocephaly and a height of 103.5 cm. Detailed ophthalmic examination was normal; abdomen was soft and distended with umbilical hernia and hepato-splenomegaly.

X- Ray skull lateral view showed J shaped sella turcica. [Figure 2] X- Ray chest showed his ribs as wide with tapered posterior ends (paddle or spatulated appearance). Vertebral bodies appeared ovoid due to convexity of the superior and inferior surfaces. [Figure 3]

All the above clinical features and radiological findings were suggestive of MPS-II. Mental retardation, which is reportedly severe, was quite mild in this case. Unfortunately, we could not perform any measurement of Keratan and heparan sulfate in his urine and enzyme assay. Enzyme assay for iduronate sulfatase is not carried out in our laboratory therefore

Submitted: 21st October 2019

Accepted: 1st December 2019

Published: 7th October 2020

How to cite this article

Baxi K, Jagati A, Agarwal P. Mucopolysachharidosis-II: A rare case report. Nepal Journal of Dermatology, Venereology and Leprology. 2020;18(1):80-2. <https://doi.org/10.3126/njdv.v18i1.25996>.



Licensed under CC BY 4.0 International License which permits use, distribution and reproduction in any medium, provided the original work is properly cited.

it was not performed either. Our diagnosis of MPS was confirmed from his history, clinical examination and skeletal survey.

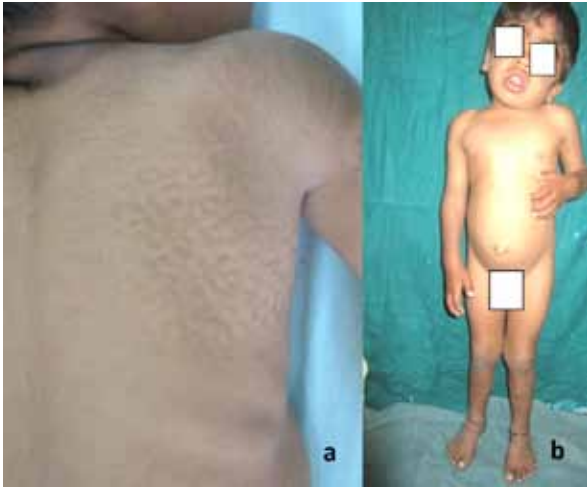

Figure 1(a and b): Typical Phenotype: coarse facial features, depressed nasal bridge, small stubby fingers and protuberant abdomen. Cobblestone appearance of the interscapular skin: Multiple skin colored papules

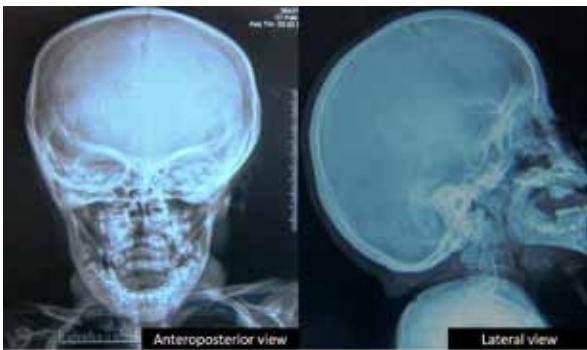


Figure 2: X-Ray skull Anteroposterior and lateral view: J shaped sella turcica, depressed nasal bridge

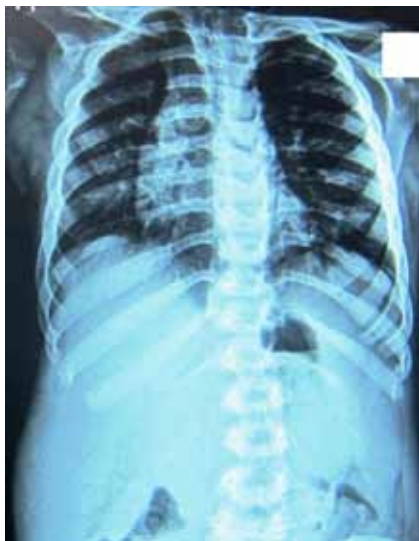

Figure 3: X-Ray chest: Posteroanterior view: Wide ribs with posterior tapering ends (spatulated appearance) and ovoid vertebral bodies.

Discussion

Mucopolysaccharidoses are a group of inherited disorders characterized by defective lysosomal enzymes responsible for breakdown of mucopolysaccharides. It was first described by Charles Hunter, a Canadian physician, who in 1917 described it in two brothers.⁴ Mucopolysaccharides are major components of intercellular connective tissue. Hence a defect in their metabolism, leads to an accumulation of incompletely degraded mucopolysaccharides in the lysosomes which affect various body systems through enzymatic activity. All mucopolysaccharidoses are autosomal recessive, except Hunter syndrome, which is X-linked recessive.⁵

Absence of corneal clouding helps distinguish Hunter syndrome from other mucopolysaccharidosis. Multiorgan dysfunction in terms of right and left ventricular hypertrophy and heart failure, hepatosplenomegaly, bronchopneumonia in end stage, sleep apnea with narrow airway are all attributable to the deposition of glycosaminoglycans in the tissues.

The reported incidence of Hunter syndrome is 1 in 1,62,000 male live births.⁶ The enzyme defect is iduronate 2 sulfatase which leads to the accumulation of dermatan sulfate and heparan sulfate. It is of two types: mild (type II, B) and severe (type II, A) based on the length of survival and the presence or absence of central nervous system (CNS) disease.⁷

The child is normal at birth. The disease manifests between two and four years of age in the severe form, but much later (second decade) in the milder variant. Prominent cutaneous features include firm, ivory colored papules, symmetrically distributed between angles of the scapulae and posterior axillary line, generalized hypertrichosis. Craniofacial anomalies include coarse facies with thick nose and depressed nasal bridge, thick lips and tongue, short neck, macrocephaly. Other musculoskeletal features observed are short stature, large head (dolichocephaly), broad nose with flared nostrils, large jaws, hypotonia, broad hands with short fingers, "dysostosis multiplex"-stiff joints, contractures, kyphoscoliosis, and claw hand deformity.⁴

The differentiating feature between the severe and mild variants of this disease is the degree of central nervous system impairment and longevity.⁸ Severe form is characterised by- severe mental retardation and loss of skills, progressive neurological impairment, deafness, hydrocephalus. In the mild form, lesser

degree of mental retardation with almost normal intelligence is observed.

Prognostically, 6 cases of mild form have been described by Berg K, and the patients survived to the ages of 65 and 87 in two cases.⁹ Three of these affected men had children, thus stressing on the relative survival benefit in mild cases.

In our case the clinical features such as short stature, a large head, organomegaly, a depressed nasal bridge, a short neck, coarse facial features, small stubby fingers, mild mental retardation with normal intelligence; and radiological features such as a J-shaped sella turcica and tapering of the posterior ends of ribs (paddle and/or spatulated ribs) as well as his developmental history were all suggestive of MPS type II.⁷ However, it cannot be said for sure whether the patient can be classified as a milder variant (due to mild mental retardation) or a severe phenotype (based on the other clinical features and an early onset).

Unfortunately, we could not do enzyme assay studies or further work up as they are not available in our institute.

The patient was lost on follow up, and hence the progression of mental retardation could not be observed. However, this case presents unique features because in spite of an early onset and a phenotype matching the severe presentation, the mental retardation which would be expected, was much milder.

Conclusion

Mucopolysaccharidosis is a multisystem disorder which presents with a constellation of clinical findings. Careful and systemic approach is needed to accurately diagnose the exact type as enzymatic studies are not available in most centers.

References

1. Kosuga M, Mashima R, Hirakiyama A, Fuji N, Kumagai T, Seo JH, et al. Molecular diagnosis of 65 families with mucopolysaccharidosis type II (Hunter syndrome) characterized by 16 novel mutations in the IDS gene: genetic, pathological, and structural studies on iduronate-2-sulfatase. *Mol Genet Metabol* 2016; 118: 190-7. <https://doi.org/10.1016/j.ymgme.2016.05.003>
2. Muenzer J, Beck M, Eng CM, Escolar ML, Giugliani R, Guffon NH, et al. Multidisciplinary management of Hunter syndrome. *Pediatrics* 2009;124:1228-39. <https://doi.org/10.1542/peds.2008-0999>
3. Muenzer J, Bodamer O, Burton B, Clarke L, Frenking GS, Giugliani R, et al. The role of enzyme replacement therapy in severe Hunter syndrome-an expert panel consensus. *Eur J Pediatr* 2012;171: 181-8. <https://doi.org/10.1007/s00431-011-1606-3>
4. Chinawa JM, Adimora GN, Obu HA, Tagbo B, Ujunwa F, Onubogu I. Clinical Presentation of Mucopolysaccharidosis Type II (Hunter's Syndrome). *Ann Med Health Sci Res* 2012; 2:87-90. <https://doi.org/10.4103/2141-9248.96946>
5. Pagni L, Bartolozzi L, Giacchetti D. Mucopolysaccharidosis. A case report of Morquio's type-A disease (MPS IV-A). *Minerva Stomatol* 1992; 41:527-33.
6. Raluy-Callado M, Chen WH, Whiteman DA, Fang J, Wiklund I. The impact of Hunter syndrome (mucopolysaccharidosis type II) on health-related quality of life. *Orphanet J Rare Dis* 2013; 8:101. <https://doi.org/10.1186/1750-1172-8-101>
7. Gupta A, Uttarilli A, Dalal A, Girisha KM. Hunter syndrome with late age of presentation: clinical description of a case and review of the literature. *BMJ Case Rep* 2015;2015: bcr2015209305. <https://doi.org/10.1136/bcr-2015-209305>
8. Gajula P, Ramalingam K, Bhadrashetty D. A rare case of mucopolysaccharidosis: Hunter syndrome. *J Nat Sc Biol Med* 2012; 3:97. <https://doi.org/10.4103/0976-9668.95984>
9. Berg K, Danes BS, Bearn AG. The linkage relation of the loci for the Xm serum system and the X-linked form of Hurler's syndrome (Hunter syndrome) *Am J Hum Genet* 1968; 20:398-401.