

<http://dx.doi.org/10.3126/njdv1.16i1.19419>

Unilateral Lichen Planus: A Rare Case Report

Jha N¹, Kanish B², Bhatia A²

¹Senior Resident, Department of Dermatology, Dr. BC Roy Post Graduate Institute of Pediatric Sciences, Kolkata, West Bengal, India; ²Associate Professor, Department of Dermatology, Christian Medical College and Hospital, Ludhiana, Punjab, India.

Abstract

Lichen planus (LP) is a papulosquamous disorder characterized by violaceous, flat topped papules and plaques seen on the volar aspect of the wrists, lumbar region and around the ankles. It can have a varied presentation. Here we describe a rare variant of LP in a female who presented with unilateral eruptions of violaceous papules over the right side of the body.

Key words: Hyperpigmentation; keratinocytes; lichen planus; mucous membrane

Introduction

Lichen planus (LP) is an inflammatory disorder of unknown etiology that affects skin, mucous membranes and nails.^{1,2} It is characterized by development of pruritic, flat topped, violaceous papules with white reticulate network referred to as Wickham's striae.³ The lesions are distributed symmetrically and bilaterally over extremities. It tends to involve the flexor aspect of the wrist, arms and legs. Many variants of this disorder like papular, hypertrophic, eruptive, annular, linear, atrophic, erosive, vesiculobullous etc. have been described.^{3,4} Here we report a rare variant of this disorder in a 30-year-old female, who presented to our skin outpatient department with unilateral eruption of violaceous papules over the right side of the body.

Case report

A 30-year-old female presented with history of multiple, asymptomatic, slightly raised violaceous lesions on the right arm, forearm, breast and thigh for the past 3 years. The eruption of the lesions was not preceded by any trauma, dental treatment or any drug intake. Patient gave a history of self-resolution of some of these lesions which left behind residual hyperpigmentation. Patient had no other comorbidities.

On examination, multiple violaceous, plane topped papules were noticed on the right arm and forearm (Figure 1). Post inflammatory hyperpigmentation was noticed on the right breast and the right thigh (Figure 2,3). Some of these lesions showed Wickham's striae. Examination of nails, scalp, oral and genital mucosa revealed no lesions.

A provisional diagnosis of unilateral LP was made and a skin biopsy was sent for histopathological examination (HPE) from one of the representative lesions on the right forearm.

HPE revealed moderate hyperkeratosis and mild irregular acanthosis. Basal cell degeneration and saw tothing of rete ridges was seen. The upper dermis showed a moderately dense lymphocytic infiltrate abutting the basal layer of the epidermis. Apoptotic keratinocytes and pigment incontinence was also noticed (Figure 4).

A final diagnosis of unilateral LP was made. Patient was started on topical steroids, emollients and antihistamines and showed improvement.

Submitted: 16th August 2017

Accepted: 15th October 2017

Published: 21st March 2018

How to cite this article

Jha N, Kanish B, Bhatia A. Unilateral lichen planus: A rare case report. Nepal Journal of Dermatology Venereology and Leprology. 2018;16(1):70-1. doi: <http://dx.doi.org/10.3126/njdv1.16i1.19419>



Licensed under CC BY 4.0 International License which permits use, distribution and reproduction in any medium, provided the original work is properly cited.

Address of Correspondence:

Dr. Niharika Jha, Senior Resident

Department of Dermatology, Dr. BC Roy Post Graduate Institute of Pediatric Sciences, Kolkata, India

E-mail: niharikajha88@gmail.com

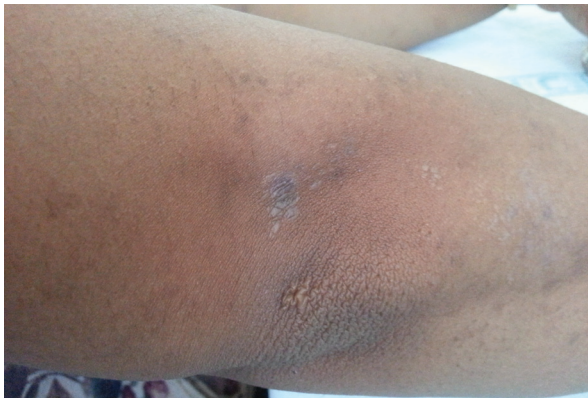

Figure 1: Violaceous plane topped papules on the right arm showing Wickham's striae.

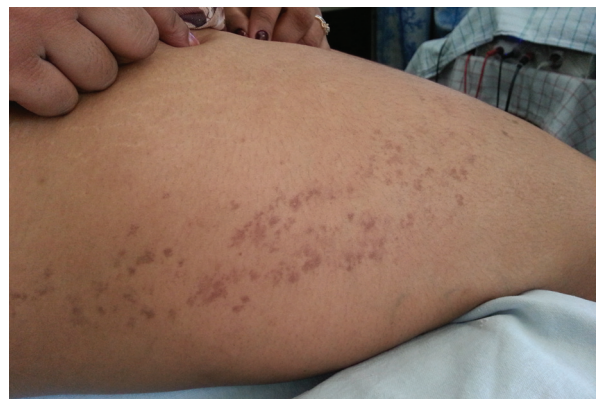

Figure 2: Residual hyperpigmentation of lichen planus lesions on the right thigh.

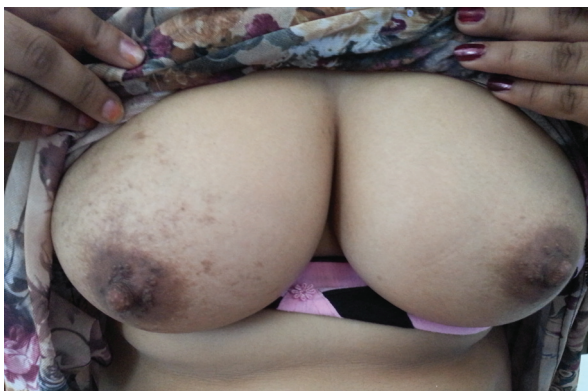

Figure 3: This figure shows presence of the lesions only on the right breast and sparing of the left breast.

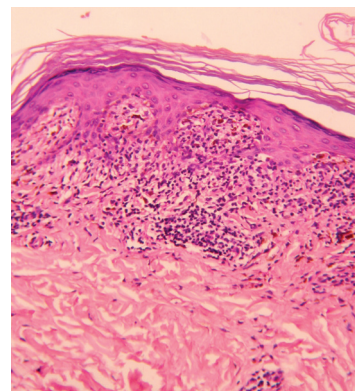


Figure 4: Basal cell degeneration, saw toothing of rete ridges and a band of lymphocytic infiltrate. H & E, 200x.

Discussion

Several variants of LP have been described but unilateral LP is a very rare presentation. The presence of lesions only on the right side of the body in this patient and a strict demarcation of these lesions at the midline cannot be explained. Few cases of unilateral LP along the lines of Blaschko have been described in the literature.^{2,3,5,6} Unilateral oral LP has also been described.⁷ However, in our patient the lesions did not strictly confine to the Blaschko's lines.

Conclusion

Unilateral Lichen Planus is a rare disease but it is important to differentiate it from other naevoid disorders because lichen planus responds to therapy.

Financial disclosure: None.

Conflict of interest to disclosure: None declared.

References

1. Gutte RM. Unilateral acrosyringial lichen planus of palm. *Indian Dermatol Online J.* 2013;4:350-2. <https://doi.org/10.4103/2229-5178.120681>
2. Yayla D, Cakmak SK, Oquz DI, Gonul M, Ozhman E, Colak A, et al. Two cases of unilateral lichen planus following the lines of blaschko. *Ann Dermatol.* 2014;26(5):636-8.
3. Rahman SB, Bari AU, Mumtaz N. Unilateral blaschkoid lichen planus involving the entire half of the body, a unique presentation. *Dermatol Online J.* 2007;13(3):36. <https://doi.org/10.5021/ad.2014.26.5.636>
4. Hartl C, Steen KH, Wegner H, Seifert HW, Beiber T. *Acta Derm Venereol.* 1999;79(2):145-6. <https://doi.org/10.1080/000155599750011390>
5. Sharma R, Maheshwari V, Chandra M. Unilateral multiple linear lichen planus along the lines of blaschko: A report of two cases. *Indian J Dermatol Venereol Leprol.* 1999;65:225-6.
6. Gupta S, Gupta S, Thomas M, Mahendra A. Unilateral lichen planus along the lines of blaschko: a rare clinical presentation. *Acta Med Indones.* 2012;44(2):163-4.
7. Bajpai M, Agarwal D, Bhalla A, VatchalaRani RM, Kumar M. Unilateral lichen planus: A rare case report. *J Nat Sci Biol Med.* 2014;5(2):453-5. <https://doi.org/10.4103/0976-9668.136248>