

A Study of the Efficacy of Skin Needling and Platelet Rich Plasma in the Treatment of Acne Scars

Ranjan S¹, Gupta RS², Gupta S³

¹Senior Resident, ²Associate Professor, ³Professor & HOD; Department of Dermatology, Venereology and Leprosy, Ascoms Hospital, Sidhra, Jammu, J&K, India, 180001

Address for correspondence

Dr. Shivani Ranjan

Senior Resident

ASCOMS Hospital, Jammu

Sec. no. 3, H. No. 717, Opp. New Shiv Mandir, Bhagwati Nagar, Jammu, J&K, India, 180016

7298161570, (Fax) 0191-2439701

E-mail: drshivaniaranjan@rocketmail.com

Abstract

Introduction: Permanent scars are the major complications of acne. Correction of scars is the priority for acne patients. Platelet-rich plasma (PRP) may be useful in the treatment of atrophic acne scars by promoting collagen deposition. Skin needling also releases growth factors, initiate a cascade of wound healing resulting in collagen production. Hence, skin needling and PRP should act synergistically to improve acne scars.

Objective: To assess the effectiveness of the combined use of skin needling and PRP application in acne scar treatment.

Material and Methods: The study enrolled 10 patients of acne scars. Platelet rich plasma therapy with needling was given to them at monthly interval for a therapeutic period of 6 months. The effects of therapy were evaluated based on photographic assessment and patient's satisfaction.

Results: Mean age of the patients was 28.10 ± 5.065 . Twenty percent of patients showed excellent response, 80% showed good response. The results were found to be significant with p value < 0.014 . Pain and edema were major complaints which subsided in 1-2 days.

Conclusion: Platelet rich plasma therapy combined with skin needling is a safe and effective treatment for management of acne scars.

Key words: platelet rich plasma, skin needling, dermaroller, acne scars

Introduction

Acne has a prevalence of over 90% among adolescents¹ and persists into adulthood in approximately 12%–14% of cases.^{2,3} Acne scar is a possible outcome of the inflammatory acne lesions. Acne scars are of two types- hypertrophic and atrophic. Atrophic acne scars are by far the most common type.⁴ Facial scars not only lead to cosmetic problems, but also have psychological effects such as emotional debilitation, embarrassment, poor self-esteem, and social isolation.⁵ Many techniques are available for the correction of atrophic acne scars, including subcision, dermabrasion, chemical peeling, laser technology, fat grafting, and use of fillers; however, these techniques have resulted in varying degrees of success and associated adverse effects.⁵⁻⁸ It has been postulated

that autologous platelet-rich plasma (PRP) could be used for the treatment of atrophic facial scars, because it can enhance wound healing, which has been shown to accelerate tissue repair.^{5,9} Percutaneous collagen induction or skin needling has recently been proposed as a simple and effective therapeutic option for the management of atrophic scars.¹⁰ Skin needling is a technique that uses a sterile dermaroller to puncture the skin and release growth factors. PRP can be combined with skin needling to enhance the efficacy of both modalities. Accordingly, this current study was conducted aiming to clarify the efficacy and safety of each modality.

Platelet-rich plasma (PRP) is an autologous concentration of human platelets in a small volume of plasma that has a higher platelet concentration (4-7

times) above baseline.¹¹ It contains growth factors (GFs) derived of platelets alone (stored as α granules in platelets) and plasma proteins, namely fibrin, fibronectin and vitronectin.¹² The membrane bound α -granules are an important intracellular storage pool of growth factors including platelet-derived growth factor (PDGF), transforming growth factor (TGF- α) and insulin-like growth factor (IGF-I) that are vital to wound healing^{13,14} whereas the plasma proteins act as a scaffold for the bone, connective tissue and epithelial migration. On activation, these α -granules fuse with the platelet cell membrane and activate secretory proteins to a bio-active state. These secreted proteins then binds to their transmembrane receptors on the target cells like epidermal cells, mesenchymal stem cells, fibroblasts, osteoblasts, endothelial cells inducing an internal signal transduction pathway, thereby increasing expression of various gene sequences in cells like cell proliferation, collagen synthesis, antiapoptosis etc. thereby augmenting natural wound healing process.^{4,15}

Material and Methods

The study was conducted in the Department of Dermatology, Venereology and Leprology, ASCOMS Hospital, Jammu in collaboration with the department of Blood Transfusion Medicine, ASCOMS Hospital from Jan. 2015 to Dec. 2015. The study was approved from the ethical committee of our institution. Patients in the age group of 20-40 years with acne scars were selected. Exclusion criteria were patients with active acne, active herpes labialis, patients on systemic retinoids, anticoagulant therapy, evidence or history of keloid scars, bleeding disorders, pregnancy or lactation, history of any facial surgery or procedure for scars and patients with unrealistic expectations, HIV or Hepatitis B or C positive patients.

Ten patients of acne scars were selected on the basis of inclusion and exclusion criteria. Type of acne scars were noted (Table 1 & figure 1).¹⁶ Photographs of local site at start, during and end of treatment were taken. The results were assessed using qualitative global scarring grading system (Table 2).¹⁷

PROCEDURE: In our institution we adopted the manual double spin method used by Arshdeep et al¹⁸ and Gonshor et al¹⁹ for preparing PRP. After taking informed written consent & with all aseptic precautions, 20 ml of venous blood was withdrawn in vacuum tubes containing an anticoagulant- citrate dextrose solution formula. It was then centrifuged at

160 g for 10 min. at 28 deg. celsius. Plasma and buffy coat were aspirated and again centrifuged at 400 g for 10 min. at 28 deg celsius. Approximately $\frac{3}{4}$ of the supernatant was discarded and platelet rich pellet was resuspended in remaining amount of plasma. PRP was thus obtained.

Facial skin was disinfected with spirit swab, then a topical anesthetic cream was applied, left for 60 minutes. The procedure site was activated by microneedling technique using a dermaroller (1.5mm). Add activator (10% Calcium chloride) to the PRP. Activated PRP was collected in 1 ml syringes. The PRP was injected into the activated site intradermally and the area was massaged to allow it to percolate through the epidermis. A total of 6 sittings were given to each patient at interval of 1 month over a period of 6 months.

Results were assessed at the end 6 months by evaluation of global photographs and patient's self satisfaction. The improvement was rated as poor, good and excellent depending upon the change in grade of acne scars by two blinded dermatologists (who did not perform the procedures) to evaluate the overall clinical improvement. An improvement by two grades was considered as excellent, 1 grade was rated as good and no upgradation on assessment was labelled as poor response. Each participant was instructed to evaluate his/her overall satisfaction with the treatment using a quartile grading system which defines 0 as unsatisfied, 1 as slightly satisfied, 2 as satisfied, or 3 as very satisfied. Side effects were recorded at each session. Post procedure, antibiotic medication for 2-3 days, sun protection and regular usage of sunscreens was advised.

The collected data was entered in excel and analysed using appropriate statistical methods with SPSS 16.0.2. The significance of the outcome of the study was assessed by calculating the 'P' value and a value less than 0.05 was taken as significant.

Results

All the patients completed the study. Age and sex distribution of patients is mentioned in Table 3. Mean age of the patients was 28.10 ± 5.065 . All of the 10 patients achieved reduction in acne scarring by 1 or 2 grades as depicted in Table 4. Excellent response was observed in 20% of the patients, good response in 80% (Fig 2). Results were found to be significant with p value <0.014.

Table 1: Morphological Classification of Acne Scar ¹⁶

Acne scar subtype	Clinical features
Icepick	narrow (< 2mm), deep, sharply marginated epithelial tracts that extend vertically to the deep dermis or subcutaneous tissue
Rolling	wider than 4-5 mm, abnormal fibrous anchoring of the dermis to the subcutis leads to superficial shadowing and a rolling or undulating appearance to the overlying skin.
Boxcar	round to oval depressions with sharply demarcated vertical edges, similar to varicella scars and are clinically wider at the surface than icepick scars and do not taper to a point at the base. They may be shallow (0.1–0.5mm) or deep (≥0.5mm) and are most often 1.5 to 4.0mm in diameter

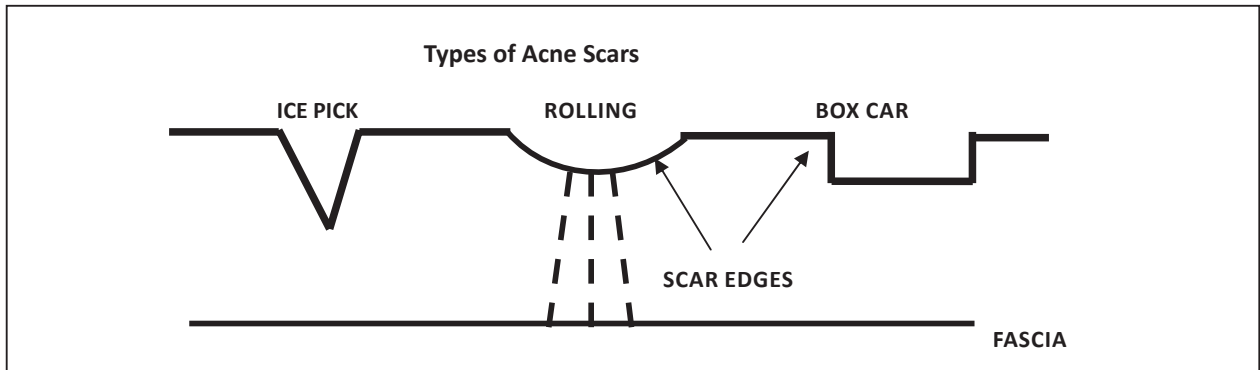


Figure 1: Subtypes of atrophic acne scars ¹⁶

Table 2: Qualitative Global Scarring Grading System (Goodman and Baron)¹⁷

Grading	Level of disease	Clinical features
1	Macular	erythematous, hyper/ hypopigmented flat marks
2	Mild	Mild atrophy or hypertrophic scars that may not be obvious at distances of 50cm or greater & may be covered adequately by make up or beard hair in men
3	Moderate	Moderate atrophy or hypertrophic scarring obvious at distances of 50cm or greater, not covered by makeup or beard hair but can be flattened by manual stretching of the skin.
4	Severe	Severe atrophy or hypertrophic scarring not flattened by manual stretching of the skin.

Table 3: Sex and age distribution of study population

Sex	Number	Percentage
Male	5	50%
Female	5	50%
Age (years)	Number	Percentage
20-30	6	60%
30 -40	4	40%

Table 4: Effect of treatment on acne scars

S.N.	Grading of Acne Scar	
	Before Treatment	After Treatment
1	4	3
2	4	3
3	3	1
4	4	3
5	3	1
6	3	1
7	2	1
8	4	3
9	2	1
10	2	1

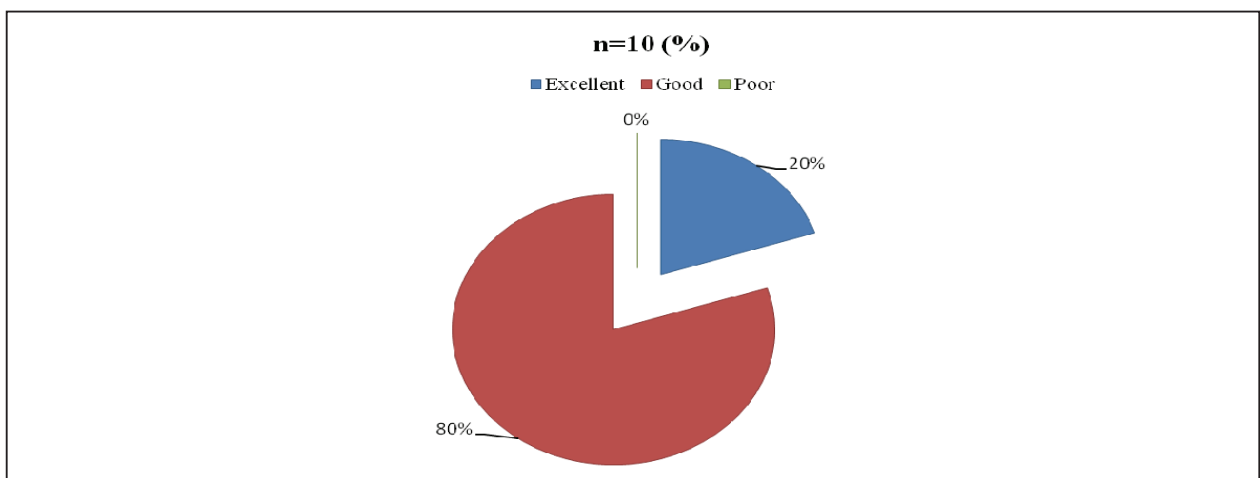


Figure 2: Grades of improvement after treatment

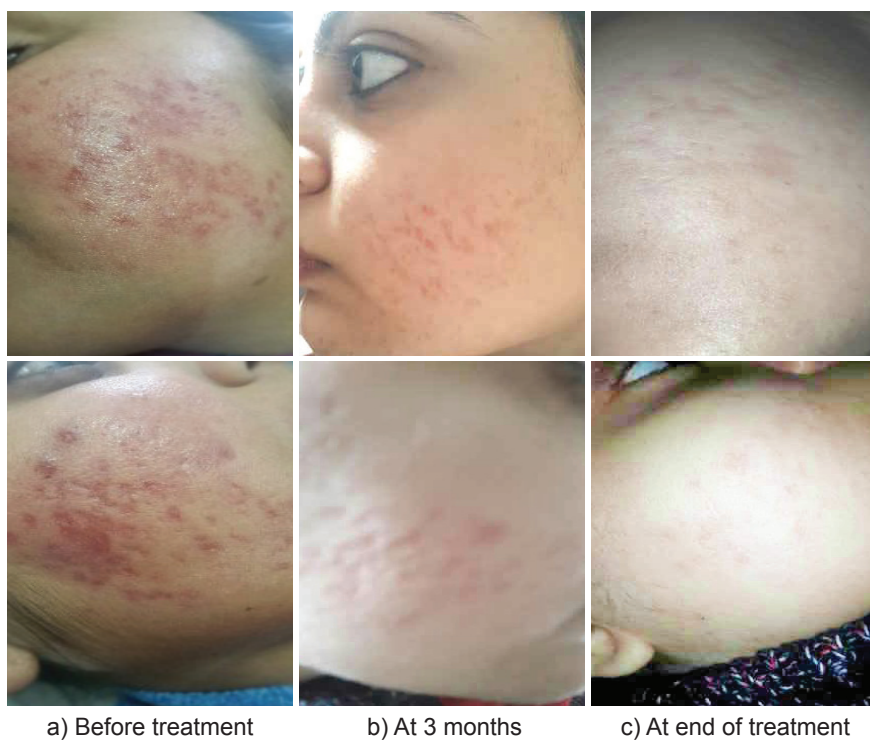

Figure 3: Serial photographs of 23 yrs old female treated with PRP and Skin Needling

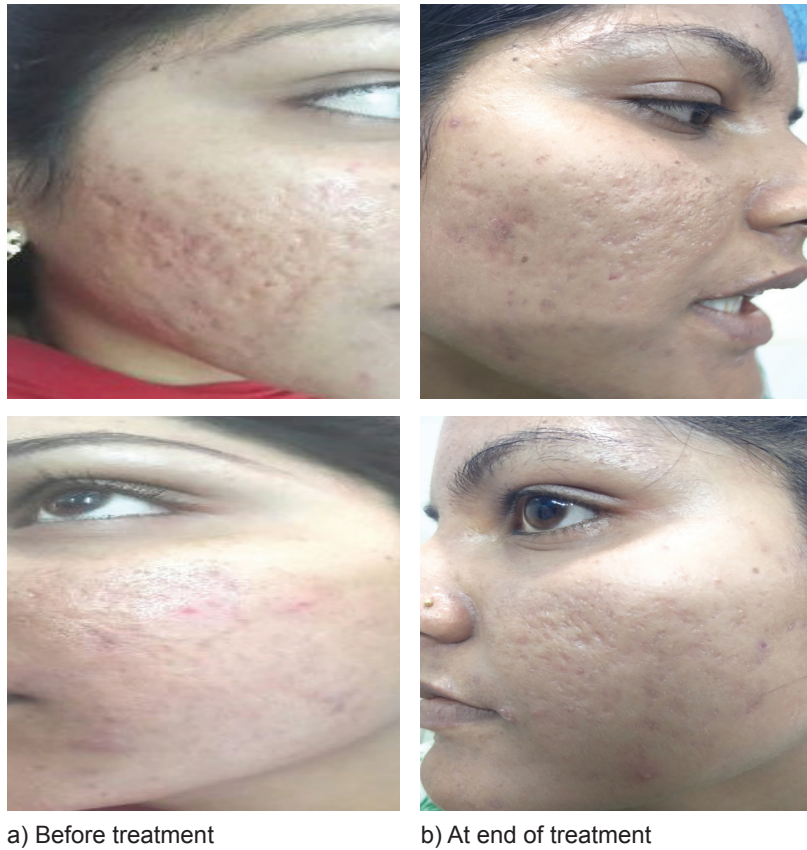

Figure 4: Serial photographs of 21 years old female treated with Skin needling and PRP

Discussion

Acne is one of the leading cause for visits to a dermatologist.²⁰ Although most cases develop in adolescence, it can frequently continue into adulthood. In one study almost 18% of women were found to have true late-onset disease, with an onset after the age of 25 years.²¹ Acne causes not only facial scarring but also it leads to significant psychosocial implications and emotional distress more so in adolescents. Many options are available for the treatment of acne scarring, including chemical peeling, dermabrasion, laser treatment, punch techniques, fat transplantation, other tissue augmenting agents, needling, subcision, and combined therapy. Various modalities have been used to treat scars, but limited efficacy and problematic side effects have restricted their application. PRP effectiveness in wound healing has prompted its use in the treatment of depressed facial scars, along with other available treatment modalities.²² The possible mechanism of PRP in the reconstruction of a depressed scar is the induction of growth factors important in tissue remodeling, which promote connective tissue healing by upregulating collagen and protein synthesis.⁹ Growth factors present in PRP promotes recovery of laser-damaged skin &

accelerates tissue remodelling with the increased synthesis of collagen.^{23,24} So, PRP holds a promising role in soft tissue augmentation. Advantages of Platelet Rich Plasma²⁵

1. PRP is autologous preparation, hence its non-antigenic.
2. It is also a low-risk option which won't cause further scarring or damage.
3. The mitogenic effects of PRP are only limited to augmentation of the normal healing process and is theoretically not mutagenic, as the growth factors released do not enter the cell or its nucleus, but only bind to the membrane receptors and induce signal transduction mechanisms.
4. Economical preparation.

Skin needling also called collagen induction therapy^{26,27} or needle dermabrasion is the technique of rolling a device comprising a barrel studded with hundreds of needles, which create thousands of micropunctures in the skin to the level of papillary to mid-dermis.^{26,28} With this technique, the rolling is usually continued until bruising occurs, which initiates the complex cascade of growth factors that finally results in collagen production²⁸⁻³⁰. Also it provides a clear channel for topical agents to be absorbed more effectively through

the top layer of skin. Results generally start to be seen after about six weeks, but the full effects can take at least three months to occur and, as the deposition of new collagen takes place slowly, the skin texture will continue to improve over a 12-month period.³⁰ The optimal scars to treat with skin needling are the rolling acne scars and superficial boxcar scars.^{26,29} This technique has many advantages:

1. It is safe in all skin types and carry the lowest risk of postinflammatory hyperpigmentation when compared to laser resurfacing, chemical peels, or dermabrasion.^{26,30}
2. The treatment does not result in a line of demarcation between treated and untreated skin.
3. The recovery period of 2 to 3 days is significantly shorter than other resurfacing procedures.
4. It is much less expensive²⁶

In our study, a statistically significant improvement was noted by combining PRP with skin needling (p value <0.014). This finding could be attributed to the synergistic effects of both modalities on all types of atrophic acne scars. None of our patients showed any permanent pigmentary or textural changes. The only side effects were redness and swelling of patients' facial skin after each session of treatment, which subsided in 2 to 3 days.

In conclusion, the current study offers different, effective and safe therapeutic option for the treatment of atrophic acne scars. This technique is affordable and is most likely useful in areas where there is limited access to laser technology.

Acknowledgement: Dr. Kumkum Sharma, HOD, Deptt of blood transfusion medicine for providing the technical support for preparing PRP.

References

1. Ghodsi SZ, Orawa H, and Zouboulis CC. Prevalence, severity, and severity risk factors of acne in high school pupils: a community-based study. *J Invest Dermatol* 2009; 129(9): 2136-41. <https://doi.org/10.1038/jid.2009.47>.
2. Williams C and Layton AM. Persistent acne in women: implications for the patient and for therapy. *Am J Clin Dermatol* 2006; 7: 281. <https://doi.org/10.2165/00128071-200607050-00002>.
3. Capitanio B, Sinagra JL, V. Bordignon V, Fei PC, Picardo M, and Zouboulis CC, Underestimated clinical features of postadolescent acne. *J Am Acad Dermatol* 2010; 63(5): 782-8. <https://doi.org/10.1016/j.jaad.2009.11.021>.
4. Layton AM, Henderson CA, Cunliffe WJ. A clinical evaluation of acne scarring and its incidence. *Clin Exp Dermatol*. 1994; 19: 303-8. <https://doi.org/10.1111/j.1365-2230.1994.tb01200.x>
5. In Young Oh, Beom JK and Myeung NK. Depressed facial scars successfully treated with autologous platelet-rich plasma and light-emitting diode phototherapy at 830 nm. *Ann Dermatol*. 2014; 26(3): 417-8. <https://doi.org/10.5021/ad.2014.26.3.417>
6. Alster T, Zaulyanov L. Laser scar revision: a review. *Dermatol Surg* 2007;33:131-140. <https://doi.org/10.1097/00042728-200702000-00001>
7. Cooper JS, Lee BT. Treatment of facial scarring: lasers, filler, and nonoperative techniques. *Facial Plast Surg* 2009; 25: 311- 315. <https://doi.org/10.1055/s-0029-1243079>
8. Fabbrocini G, Annunziata MC, Arco VD, Vita VD, Lodi G, Mauriello MC et al. Acne Scars: Pathogenesis, Classification and Treatment. *Dermatol Res Pract*. 2010; 2010: 893080. doi: 10.1155/2010/893080. <https://doi.org/10.1155/2010/893080>
9. Ganio C, Tenewitz FE, Wilson RC, Moyles BG. The treatment of chronic nonhealing wounds using autologous platelet-derived growth factors. *J Foot Ankle Surg* 1993;32: 263-268.
10. Fabbrocini G¹, De Vita V, Monfrecola A, De Padova MP, Brazzini B, Teixeira F et al. Percutaneous collagen induction: an effective and safe treatment for post-acne scarring in different skin phototypes. *J Dermatolog Treat*. 2014; 25(2): 147-52. <https://doi.org/10.3109/09546634.2012.742949>
11. Marx RE, Garg AK. *Dental and Craniofacial Applications of Platelet Rich Plasma*. Chicago: Quintessence Publishing; 2005.(17)
12. Arshdeep M, Sendhil K. Platelet rich plasma in dermatology: Boon or bane? *Indian J Dermatol*

- Venereol. 2014; 80(1): 5-14. <https://doi.org/10.4103/0378-6323.125467>
13. Cooper JS, Lee BT. Treatment of facial scarring: lasers, filler, and nonoperative techniques. *Facial Plast Surg.* 2009; 25: 311–315. <https://doi.org/10.1055/s-0029-1243079>
 14. Marx RE. Platelet-rich plasma: evidence to support its use. *J Oral Maxillofac Surg* 2004; 62(4): 489-96. 6.
 15. De La Mata J. Platelet rich plasma. A new treatment tool for the rheumatologist? *Reumatol Clin* 2013; 9(3): 166-71. <https://doi.org/10.1016/j.reuma.2012.05.011>
 16. Sharif PS, Abdollahi M. The role of platelets in bone remodeling. *Inflamm Allergy Drug Targets* 2010; 9: 393-9. <https://doi.org/10.2174/187152810793938044>
 17. JACob CI, Dover JS, Kaminer MS, “Acne scarring: a classification system and review of treatment options,” *Journal of the American Academy of Dermatology*, 2001; 45(1): 109–117. <https://doi.org/10.1067/mjd.2001.113451>
 18. Redaelli A, Romano D, Marciano A. Face and neck revitalization with platelet-rich plasma (PRP): clinical outcome in a series of 23 consecutively treated patients. *J Drugs Dermatol* 2010; 9: 466–472.
 19. Arshdeep, Kumaran MS. Platelet-rich plasma in dermatology: Boon or a bane?. *Indian J Dermatol Venereol Leprol* 2014; 80: 5-14. <https://doi.org/10.4103/0378-6323.125467>
 20. Gonshor A. Technique for producing platelet-rich plasma and platelet concentrate: Background and process. *Int J Periodontics Restorative Dent* 2002; 22: 547-57.
 21. Dreno B, Poli F. Epidemiology of acne. *Dermatology.* 2003; 206(1): 7-10. <https://doi.org/10.1159/000067817>
 22. Goulden V, Clark SM, Cunliffe WJ. Post-adolescent acne: a review of clinical features. *Br J Dermatol.* 1997; 136(1): 66-70. <https://doi.org/10.1046/j.1365-2133.1997.d01-1144.x>
 23. Lee JW, Kim BJ, Kim MN, Mun SK. The efficacy of autologous platelet rich plasma combined with ablative carbon dioxide fractional resurfacing for acne scars: a simultaneous split-face trial. *Dermatol Surg* 2011; 37(7): 931-8. <https://doi.org/10.1111/j.1524-4725.2011.01999.x>
 24. Park KY, Kim IS, Kim BJ, Kim MN. Letter: Autologous fat grafting and platelet-rich plasma for treatment of facial contour defects. *Dermatol Surg* 2012; 38: 1572-4. <https://doi.org/10.1111/j.1524-4725.2012.02515.x>
 25. Cervelli V, Nicoli F, Spallone D, et al. Treatment of traumatic scars using fat grafts mixed with platelet-rich plasma, and resurfacing of skin with the 1540 nm nonablative laser. *Clin Exp Dermatol* 2012; 37: 55-61. <https://doi.org/10.1111/j.1365-2230.2011.04199.x>
 26. Sacchidanand S and Lakshmi DV. Platelet rich plasma therapy in trichology. *Hair and Hair Disorders: Diagnosis and Management.* 1st edition 2015: 333-339.
 27. Fife D. Practical evaluation and management of atrophic acne scars: tips for the general dermatologist. *J Clin Aesthet Dermatol.* 2011; 4: 50–57.
 28. Goodman GJ, Baron JA. The management of postacne scarring. *Dermatol Surg.* 2007; 33: 1175–1188. <https://doi.org/10.1097/00042728-200710000-00004>
 29. Leheta T, El Tawdy A, Abdel Hay R, Farid S. Percutaneous collagen induction versus full-concentration trichloroacetic acid in the treatment of atrophic acne scars. *Dermatol Surg.* 2011; 37: 207–216. <https://doi.org/10.1111/j.1524-4725.2010.01854.x>
 30. Fabbrocini G, Fardella N, Monfrecola A, et al. Acne scarring treatment using skin needling. *Clin Exp Dermatol.* 2009; 34: 874–879. <https://doi.org/10.1111/j.1365-2230.2009.03291.x>
 31. Fabbrocini G, Annunziata MC, D’Arco V, Vita VD, Lodi G, Mauriello MC, et al. Acne scars: pathogenesis, classification and treatment. *Dermatol Res Pract.* 2010; 2010: 893080. <https://doi.org/10.1155/2010/893080>