

<https://doi.org/10.3126/njdv.v19i1.34167>

Hypopigmented Mycosis Fungoides- A Case Report

Joshi A¹, Thapa DP²

¹Third year resident, Department of Dermatology, Nepal Medical College Teaching Hospital; ²Associate Professor, Department of Dermatology, Nepal Medical College Teaching Hospital, Attarkhel, Kathmandu, Nepal

Abstract

Mycosis fungoides is the most common primary cutaneous T-cell lymphoma and is recognized as one of the rare malignant skin neoplasms. Hypopigmented mycosis fungoides is a variant of mycosis fungoides, described in dark-skinned individual and Asian patients. We report a case of 32 years old Nepalese female who had presented with multiple asymptomatic hypopigmented macules over the bilateral arms, thighs, abdomen, back of trunk and buttocks. Histopathology revealed few atypical cells (small/medium-sized, cerebriform nuclei with halo) confined to epidermis with epidermotropism. Immunohistochemistry showed CD3, CD4, CD5 and CD8 positivity. The patient was managed with topical steroids, oral methotrexate and phototherapy, and she is on regular follow up. As the disease has an indolent clinical course, long term follow up is necessary. Hypopigmented mycosis fungoides is not only rare in our part of the world but also in the western literature. Awareness of hypopigmented mycosis fungoides as a rare condition and keeping it as differential diagnosis of various hypopigmented dermatological condition, not only helps the treating physician to make early diagnosis but also reduces morbidity and mortality due to such cutaneous malignancy with proper management and care.

Key words: Immunohistochemistry; Mycosis fungoides; Lymphoma, T-Cell, Cutaneous

Introduction

Mycosis fungoides (MF) is the common variant of primary cutaneous T-cell lymphoma (CTCL) and represent <1% of total number of non-Hodgkin lymphomas, associated with an indolent clinical course.^{1,2} It was first reported in 1806 by French physician Baron Jean-Louis Alibert.^{3,4} Hypopigmented MF is a rare variant and usually observed in dark-skinned individual, especially children and adolescent.¹ MF is usually difficult to diagnose in its early as symptoms and biopsy are helpful to differentiate it from other skin conditions.

Case report

A 32 years old Nepalese female patient presented to Dermatology outpatient department (OPD) with complaint of multiple asymptomatic hypopigmented lesions on the trunk and limbs since 2 years. The

lesion initially appeared over the right arm, 2-3 in numbers. After several months, the lesions gradually progressed to involve thighs, buttocks and front and back of the trunk. She had received multiple topical treatment (tacrolimus 0.1% ointment and moisturising creams) from outside but there was no improvement in the lesions. There was no similar history in the past, no history of chronic illness. There was no history of exposure to occupational chemicals, drugs, radiation or infections prior to appearance of the lesions. There was no similar history in other family members.

On examination, there were multiple well to ill-defined hypopigmented macules, of varying shape and size, present over trunk, bilateral upper limbs, thighs and

Submitted: 9th November 2020

Accepted: 12th January 2021

Published: 20th February 2021

How to cite this article

Joshi A, Thapa DP. Hypopigmented Mycosis Fungoides- A case report. Nepal Journal of Dermatology, Venereology and Leprology 2021;19(1):60-4. <https://doi.org/10.3126/njdv.v19i1.34167>.



Licensed under CC BY 4.0 International License which permits use, distribution and reproduction in any medium, provided the original work is properly cited.

Funding: No

Conflict of Interest: No

Address of Correspondence

Dr. Anisha Joshi
Resident, Department of Dermatology
Nepal Medical College Teaching Hospital
Attarkhel, Kathmandu, Nepal
E-mail: janishia27@yahoo.com

buttocks with involvement of about 20% of body surface area. Largest lesion approximately 7x8 cm was present on the thigh and smaller lesion approx. 1x1 cm over the arms. (Figure 1, 2, 3, 4) General examination was unremarkable without any lymphadenopathy. There was no sensory impairment. Mucocutaneous and systemic examination did not reveal any abnormality. Our clinical differential diagnosis was Hansen's disease (Borderline lepromatous leprosy), Post-kala-azar dermal leishmaniasis, Vitiligo vulgaris, MF (patch stage), Progressive macular hypomelanosis and Pityriasis versicolor. Skin biopsy was done which revealed focal superficial band-like and perivascular infiltrate mainly lymphocytes. Few atypical cells (small/medium-sized, cerebriform nuclei with halo) confined to epidermis with epidermotropism and dermal pigment incontinence. (Figure 5, 6) These features were consistent with MF. Periodic acid schiff (PAS) stain was negative. To further confirm the diagnosis, immunohistochemistry was sent. Immunohistochemistry showed CD3, CD4, CD5 and CD8 positivity. (Figure 7,8)

Further investigations were sent. Blood investigations like full blood count, liver function test, renal function and urine analysis were normal. Peripheral blood smear was normal with no atypical cells. Chest X-ray and CT scan abdomen and pelvis were normal.

The patient was treated with topical steroids, methotrexate and phototherapy. Topical halobetasol propionate was started twice a day application for 3 months. Then it was gradually tapered to once daily to alternate day to once a week application in 3 monthly interval. Then it was stopped.

Oral methotrexate was given, 15 mg per week for 3 months. Then it was tapered gradually as 10 mg per week to 7.5 mg per week to 5 mg per week in 3 months interval and was discontinued.

Phototherapy with narrow band ultraviolet B (NB-UVB) therapy was started at 0.250 J/cm² and was increased by 12.5% on every visit. It was given thrice a week for 3 months. After 3 months of treatment, there was marked improvement as shown in (Figure 9, 10, 11, 12) and was also gradually tapered to twice a week then once a week, alternate week per month and once a month in 3 months interval. Now she is on phototherapy once a month for maintenance. At present she is on regular follow up and symptom free. She will be followed up regularly for one year and then every year for 5-10 years.

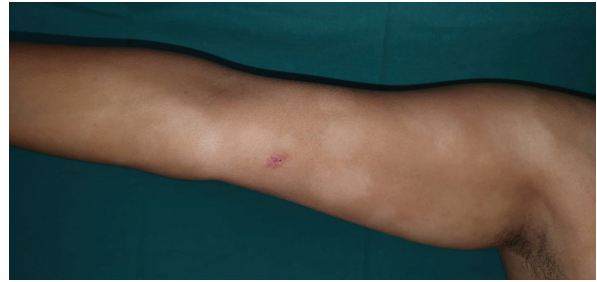

Figure 1: Multiple ill-defined hypopigmented macules over medial aspect of right arm

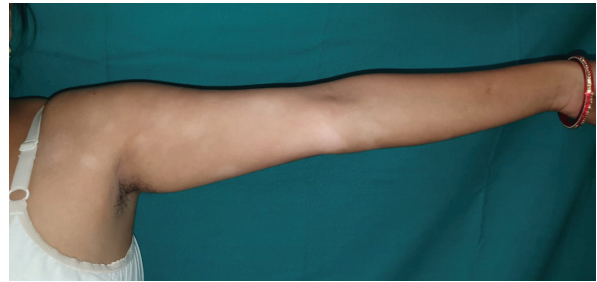

Figure 2: Multiple ill-defined hypopigmented macules on medial aspect of left arm

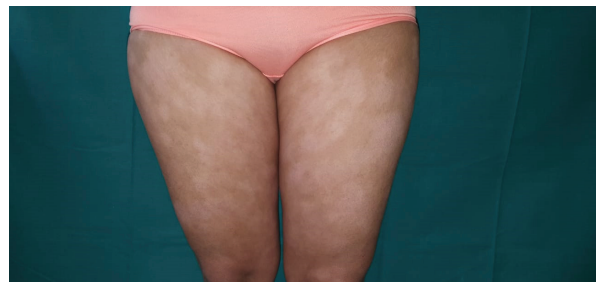

Figure 3: Multiple hypopigmented macules over the anterior aspect of the thighs

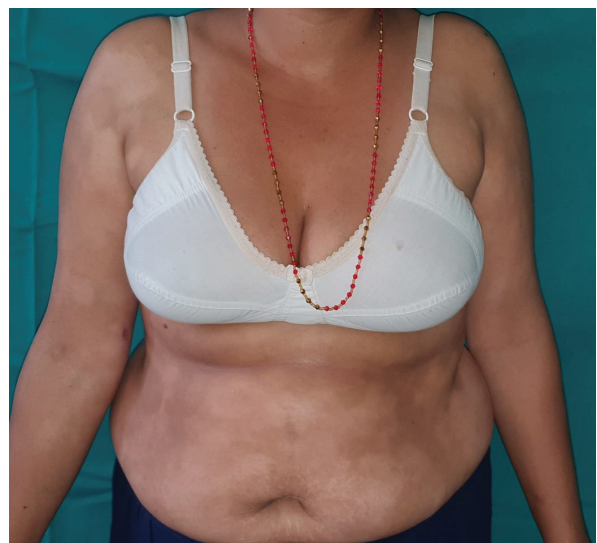

Figure 4: Multiple hypopigmented macules over the abdomen

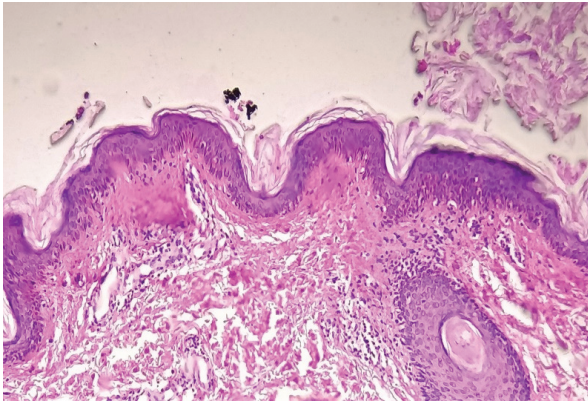


Figure 5: Hematoxylin and eosin stain, 10X. Histopathology shows focal superficial band-like and perivascular infiltrate mainly lymphocytes. Epidermotropism and dermal pigment incontinence

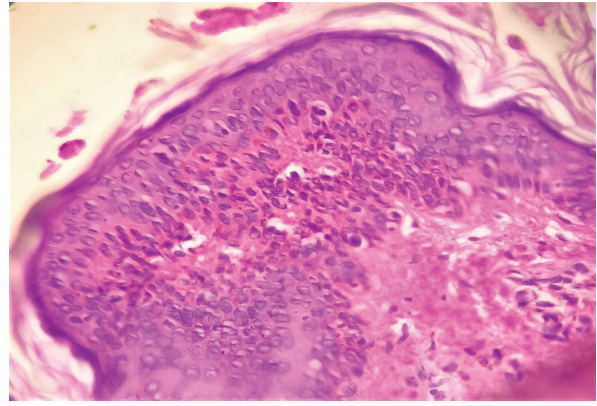


Figure 6: Hematoxylin and eosin stain, 40X. Few atypical cells (small/medium-sized, cerebriform nuclei with halo) confined to epidermis with epidermotropism and dermal pigment incontinence

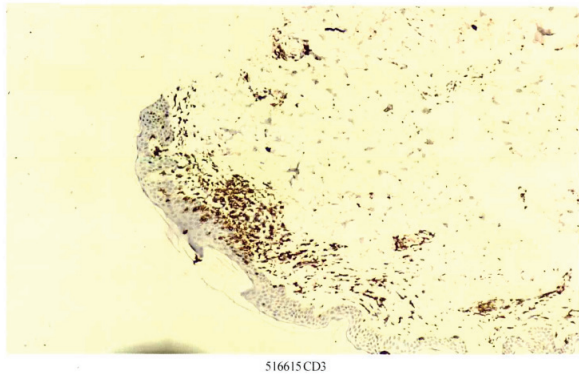


Figure 7: Immunohistochemistry showed CD3 positivity

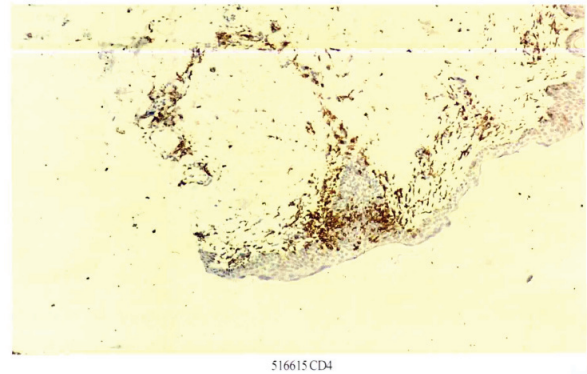


Figure 8: Immunohistochemistry showed CD4 positivity

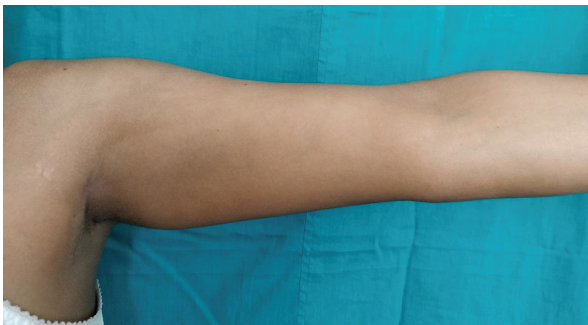

Figure 9: Post treatment improvement in the lesion over left arm

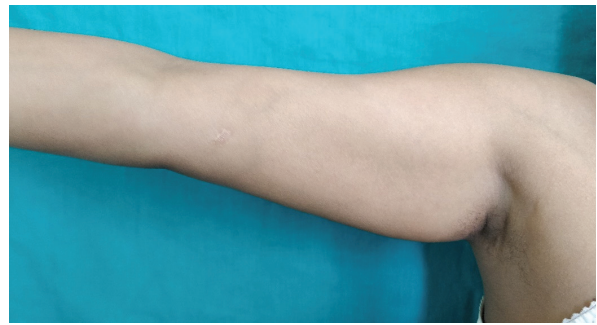

Figure 10: Post treatment improvement in the lesion over right arm

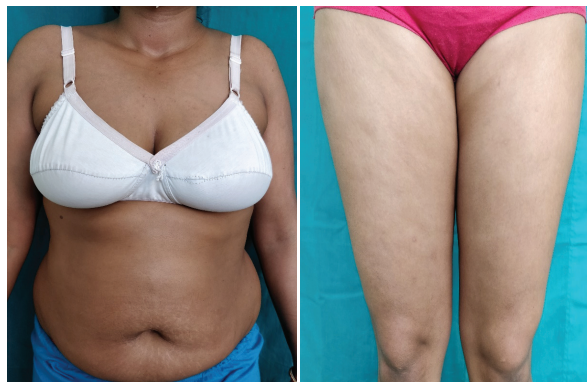

Figure 11, 12: Post treatment improvement in the abdomen and thigh region

Discussion

Mycosis fungoides is one of the primary cutaneous non-Hodgkin lymphomas, comprising 44-62% of all cases.^{4,5} It has an indolent clinical course and better prognosis when detected early. It mainly affects adults with median age 55-60 years.⁴ MF usually presents as patches, plaques, nodules or tumors. Several other atypical variants of MF have been described.⁶ Hypopigmented MF is an uncommon variant and first case was described in 1973.^{1,5} Several other clinical variants of MF have been described: hyperpigmented, ichthyosiform, pityriasis lichenoides-like, granulomatous, folliculotropic, pagetoid reticulosis, purpuric, hyperkeratotic and verrucous.⁵ Diagnosis of early stage of MF depends upon the clinicopathologic correlation.⁷

Hypopigmented MF usually have younger age of onset with female predominance and in patient with skin phototype IV-VI, which differentiate it from classic MF.^{2,5,6} They also have been observed in fair-skinned patients.² The pathogenesis of hypopigmented MF is still unclear, but hypopigmentation may be due to cytotoxic effects of T suppressor lymphocytes on melanocytes; pathomechanism similar to vitiligo.¹ Atypical lymphoid cells infiltrating the epidermis cause melanocyte degeneration and abnormal melanogenesis which results from nonspecific cell injury.⁶ It is characterized by presence of isolated hypochromic lesions or by coexistence of multiple erythematous and hypochromic lesions, chiefly distributed over trunk and proximal parts of extremities, with occasional involvement of distal extremities and head.^{2,5} The lesions are not sharply circumscribed and may be slightly dry. The presentation are usually delayed as initial lesions may be subtle and have gradual progression.⁶ Histopathologically, there is focal parakeratosis, little or no spongiosis, upper dermal lymphocytic infiltrate with coarse collagen bundles and intense epidermotropism whereas Pautrier microabscess are seldom noted.⁵ Hypopigmented MF often shows T suppressor cell CD8 positive phenotype, although CD4 positive phenotype has also been reported.¹

Differential diagnosis include leprosy, vitiligo, Post-kala-azar dermal leishmaniasis, progressive macular hypomelanosis, pityriasis versicolor and postinflammatory hypopigmentation. The clinical manifestation of all the above condition have multiple hypopigmented macules over the body. Sensory examination and wood's lamp helps to differentiate some of the condition. Histopathology of Hansen's

disease varies depending on host immune response to organism. The histopathology of leprosy shows granulomatous inflammation comprised of epithelioid histiocytes and Langhan's giant cells, surrounded by lymphocytes in periadnexal and perineural locations; granuloma are composed of macrophages, lymphocytes, epithelioid cells and there is presence of foamy macrophages and globi. Histopathology of vitiligo reveals basal hypomelanosis, sparse to mild lymphocytic inflammation in papillary dermis. In post-kalaazar dermal leishmaniasis, there is dense infiltrate of lymphocytes, histiocytes and plasma cells in upper dermis with an occasional eosinophil. In PAS stain of pityriasis versicolor reveal spores and hyphae in upper layers of stratum corneum and mild superficial, perivascular lymphocytic infiltrate.⁸ Progressive macular hypomelanosis's histopathology shows loss of epidermal pigment with no dermal abnormalities and postinflammatory hypopigmentation shows reduction in melanin pigment in basal layer, sometimes pigment-containing melanophages present in upper dermis.⁹ So histopathology is very helpful in differentiating the various condition with hypopigmented macules.

In immunohistochemical aspect, MF tumor cells are characterized by epidermotropic peripheral T lymphocytes whose phenotype is CD2⁺, CD3⁺, CD4⁺, CD5⁺, CD8⁺, CD45RO⁺, CD20⁻ and CD30⁻. The loss of CD7 expression can be observed even in early phases of disease.² Treatment modalities for hypopigmented MF include phototherapy, photochemotherapy, topical nitrogen mustard, topical carmustine and total skin electron beam therapy.^{5,6} Phototherapy, both psoralen and ultraviolet A therapy (PUVA) and NBUBV can be used. NBUBV has wide availability, better safety profile and comparable efficacy as that of PUVA.⁵ As the disease has indolent nature and high probability of recurrence, aggressive treatment generally not required but long term follow-up is essential.⁶

Conclusion

Hypopigmented MF is a rare variant of MF. There are very few cases of hypopigmented MF reported in the literature. To best of our knowledge, we report first case of hypopigmented MF from Nepal. Hypopigmented MF can be misdiagnosed as other infectious and dermatological diseases like Hansen's disease, Post-kala-azar dermal leishmaniasis, Vitiligo vulgaris etc. Therefore awareness of this type of variant of MF with great clinical suspicion of cutaneous malignancy helps dermatologists and treating physicians like medical officers, general practitioners etc who is practicing in both urban and rural areas for the early

diagnosis and referral of such patients to the higher centers for further advanced diagnostic workup with histopathology and immunohistochemistry, hence

decreasing the morbidity and mortality associated with such rare form of cutaneous malignancy.

References

- 1) Das J, Gangopadhyay A. Mycosis fungoides with unusual vitiligo-like presentation. *Indian J Dermatol Venereol Leprol* 2004; 70: 304-6.
- 2) Yamashita T, Abbade LP, Marques ME, Marques SA. Mycosis fungoides and Sezary syndrome: clinical, histopathological and immunohistochemical review and update. *An Bras Dermatol* 2012; 87: 817-30. <https://doi.org/10.1590/S0365-05962012000600001>
- 3) Akinbami AA, Osikomaiya BI, John-Olabode SO, Adediran AA, Osinaike O, Uche EI, et al. Mycosis fungoides: casereportandliteraturereview. *Clinical Medicine Insights: Case Reports* 2014; 7: 95-8. <https://doi.org/10.4137/CCRep.S15724>
- 4) Zarami BA. Mycosis fungoides: A report of two cases. *Int J Case Rep Images* 2018; 9: 100895Z01BZ2018.
- 5) Bisherwal K, Singal A, Pandhi D, Sharma S. Hypopigmented mycosis fungoides: Clinical, histological and immunohistochemical remission induced by narrow-band ultraviolet B. *Indian J Dermatol* 2017; 62: 203-6. https://doi.org/10.4103/ijd.IJD_365_16
- 6) Jagadeesan S, Eapen M, Thomas J. Asymptomatic hypopigmented macules on the trunk and limbs of a young male. *Pigment Int* 2016; 3: 52-3. <https://doi.org/10.4103/2349-5847.184266>
- 7) Khopkar U, Doshi BR, Dongre AM, Gujral S. A study of clinic pathologic profile of 15 cases of hypopigmented mycosis fungoides. *Indian J Dermatol Venereol Leprol* 2011; 77:167-73. <https://doi.org/10.4103/0378-6323.77456>
- 8) Patel AB, Kubba R, Kubba A. Clinicopathological correlation of acquired hypopigmentary disorders. *Indian J Dermatol Venereol Leprol* 2013; 79: 376-82. <https://doi.org/10.4103/0378-6323.110800>
- 9) Relyved GN, Menke HE, Westerhof. Progressive Macular Hypomelanosis. *Am J Clin Dermatol* 2007; 8: 13-9. <https://doi.org/10.2165/00128071-200708010-00002>.