

A Complex Case of Infective Endocarditis with Systemic Complications

Anmol Sharma¹, Arun Maskey¹, Parash Koirala¹, Sunil Pathak², Subash Phuyal², Pratyush Shrestha²

¹ Department of Cardiology, Shahid Gangalal National Heart Center

² Department of Neurosurgery, Upendra Devkota Memorial National Institute of Neurological and Allied Sciences

Corresponding Author:

Anmol Sharma

Department of Cardiology

Shahid Gangalal National Heart Centre

Kathmandu, Nepal

Contact: 9860283055

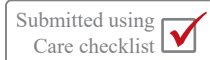
Email ID: anmol.sr72@gmail.com

ORCID ID NO: <https://orcid.org/0009-0005-3119-3743>

Cite this article as: Sharma, A., Maskey, A., Koirala, P., Pathak, S., Phuyal, S., & Shrestha, P. A Complex Case of Infective Endocarditis With Systemic Complications. *Nepalese Heart Journal*, 21(2), 51-53.

Submission Date: July 16, 2024

Accepted Date: October 3, 2024



Abstract

A 25-year-old female with a known case of small perimembranous VSD who was started on empirical anti-tubercular drugs for suspected bilateral tubercular sacroiliitis for one month presented with persistent fever and increasing shortness of breath. Transthoracic echocardiography revealed concurrent infective endocarditis (IE) affecting the aortic and mitral valves, with small perimembranous ventricular septal defect (VSD) and severe aortic and mitral regurgitation. Repeated blood cultures did not show any growth. Empirical management with intravenous ceftriaxone and gentamicin was initiated. After completing two weeks of IV Gentamicin, the patient developed severe headache, vomiting, and transient loss of consciousness. MRI Head confirmed subarachnoid hemorrhage. Emergency External ventricular drain placement ameliorated intracranial pressure-related symptoms. Digital subtraction angiography identified a mycotic aneurysm at left MCA bifurcation as a complication of IE, which was successfully managed through endovascular coiling. Repeat MRI showed subsiding SAH with areas of ischemia, most probably related to cerebral vasospasm. Her blood cultures were still negative; hence, she shifted to Intravenous Vancomycin. After a few days, the patient developed a fever with a fall in GCS. Lumbar puncture confirmed bacterial meningitis, subsequently treated with intravenous meropenem. A cardiac CT was done, which revealed a small perimembranous VSD along with a small ruptured Sinus of Valsalva draining in the right ventricle. After successful treatment of SAH and meningitis, the patient underwent dual valve replacement (aortic and mitral), VSD closure, and Ruptured sinus of Valsalva repair. Postoperative recovery was uneventful, and the patient was discharged on the fifth postoperative day.

Key words: infective endocarditis, subarachnoid hemorrhage, mycotic aneurysm, bacterial meningitis, valve replacement, ventricular septal defect

DOI: 10.3126/nhj.v21i2.70872

Introduction

We present a complex case exemplifying the intricacies of infective endocarditis (IE) management and its associated multi-system complications. This report elucidates the diagnostic and therapeutic pathways employed to address the evolving clinical presentation and underscores the importance of interdisciplinary collaboration in optimizing patient outcomes.

Case Presentation:

A 25-year-old female, a known case of small perimembranous VSD with normal PA pressure, who was started on empirical antitubercular

therapy for presumed bilateral tubercular sacroiliitis for the last month presented with persistent fever and increasing shortness of breath. Evaluation at a tertiary cardiac center revealed concurrent infective endocarditis involving the aortic and mitral valves, accompanied by a perimembranous ventricular septal defect, severe aortic and mitral regurgitation, and a ruptured sinus of Valsalva (Figure 1). Empirical treatment with intravenous ceftriaxone and gentamicin was initiated. Multiple serial blood cultures were negative, prompting a four-week course of intravenous antibiotics (ceftriaxone and gentamicin).



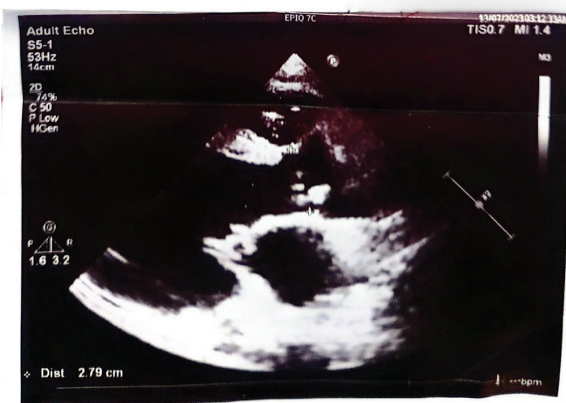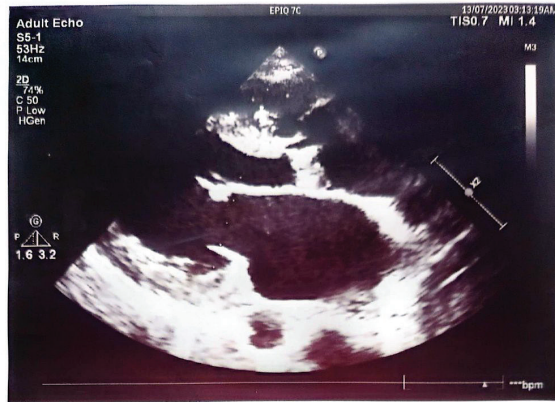


FIGURE 1: INFECTIVE ENDOCARDITIS OF AORTIC AND MITRAL VALVES

Subsequently, the patient experienced severe headaches, nausea, vomiting, and transient loss of consciousness. Subarachnoid hemorrhage (FISCHER GRADE 4) was diagnosed, and an external ventricular drain was placed for seven days for elevated intracranial pressure, which alleviated intracranial pressure-related symptoms. Digital subtraction angiography revealed a ruptured mycotic aneurysm at left MCA bifurcation as an IE-related complication, successfully managed with endovascular coiling (Figure 2). She was shifted to IV Vancomycin.

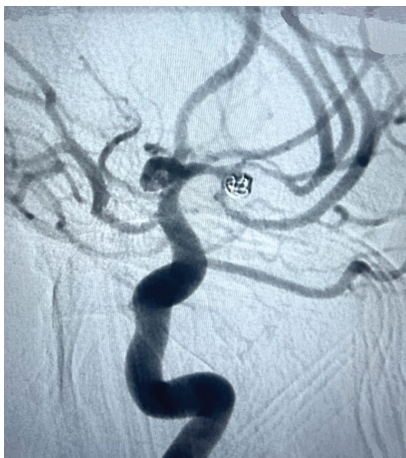


FIGURE 2: ENDOVASCULAR COILING OF A MYCOTIC ANEURYSM

Further clinical deterioration led to suspicion of bacterial meningitis, confirmed via lumbar puncture, subsequently treated with intravenous meropenem. Hence, the total duration of antibiotics was six weeks. Ischemic stroke secondary to cerebral vessel spasm was treated with nimodipine. The patient underwent dual valve replacement (aortic and mitral), closure of the ventricular septal defect, and repair of the ruptured sinus of Valsalva. The patient's preoperative GCS was E2VtM5, and postoperative GCS was E5VtM5, respectively. Postoperative recovery was uneventful, and the patient was discharged on the fifth postoperative day.

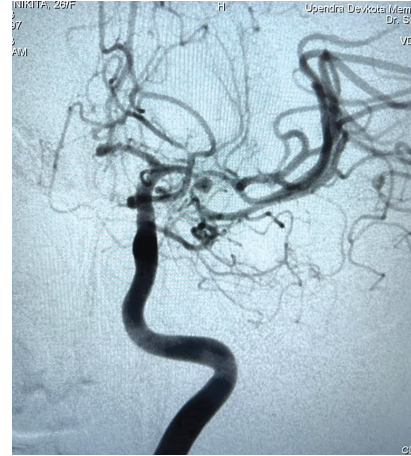

FIGURE 3: 3D IMAGE OF THE MYCOTIC ANEURYSM

Discussion:

Neurologic complications impact around 30% of infective endocarditis (IE) patients, significantly raising mortality rates. Cerebral embolism, the most prevalent problem, occurs in approximately 30% of cases and frequently results in death. Infected emboli may also lead to mycotic aneurysms, meningitis, meningoencephalitis, and brain abscesses. Mycotic aneurysms tend to develop earlier in acute IE than in subacute IE, with intracranial hemorrhage correlating to a greater chance of an aneurysm, observed in 22% of patients with bleeding against 1% without. Diagnosing aneurysms in these instances necessitates vascular imaging, especially cerebral angiography^{1,2}.

In a study from France with 198 left-sided IE patients, 55% suffered from neurologic complications. Meningitis or meningeal reactions were noted in 20.7%, stressing the importance of clinical vigilance even when cerebrospinal fluid findings are inconclusive³.

The management of intracranial infectious aneurysms (IIAs) is dictated by their size, location, and whether they've ruptured. The mortality rate for ruptured IIAs stands at 80%, compared to 30% for those unruptured. Treatment options include open surgery or endovascular procedures, with cardiac valve replacement postponed by 2 to 3 weeks^{4,5}. Endovascular methods, now the preferred choice in many cases, are frequently applied to unruptured IIAs, where antibiotics and follow-up imaging might be adequate. Surgery becomes necessary if the aneurysm persists or enlarges⁵.

Culture-negative IE is often associated with organisms like *Coxiella burnetii*, *Bartonella* species, or fungi. For acute native valve infection, vancomycin and cefepime are advised. Slower-progressing cases might demand wider coverage, including viridans group streptococci and HACEK organisms, until blood cultures can guide treatment⁶.

Many patients have surgery within the first week after admission, although early surgery (before day seven) might not decrease six-

month mortality⁷. The timing is crucial, especially in cerebrovascular complications like strokes, where delaying surgery for neurologic stabilization can enhance outcomes⁸.

This case demonstrates the complexity of managing IE and its various complications. Successful treatment hinges on effective interdisciplinary management, which comprises surgery, antibiotics, and neurovascular interventions.

Conclusion:

This case report emphasizes the importance of vigilance in managing infective endocarditis and its associated multi-system complications. The seamless coordination of various medical specialties, including cardiology, cardiac surgery, neurosurgery, neuro-intervention, microbiology, and radiology, was pivotal in managing this patient.

References:

1. Lerner PI. Neurologic complications of infective endocarditis. *Med Clin North Am.* 1985 Mar;69(2):385-98. doi: 10.1016/s0025-7125(16)31050-1. PMID: 3838785. doi: 10.1016/s0025-7125(16)31050-1
2. Salgado AV, Furlan AJ, Keys TF. Mycotic aneurysm, subarachnoid hemorrhage, and indications for cerebral angiography in infective endocarditis. *Stroke.* 1987 Nov-Dec;18(6):1057-60. PMID: 3686577. doi: 10.1161/01.str.18.6.1057.
3. Sonnevile R, Mirabel M, Hajage D, Tubach F, Vignon P, Perez P, et al and the ENDOcardite en REAnimation Study Group. Neurologic complications and outcomes of infective endocarditis in critically ill patients: the ENDOcardite en REAnimation prospective multicenter study. *Crit Care Med.* 2011 Jun;39(6):1474-81. PMID: 21358398. doi: 10.1097/CCM.0b013e3182120b41.
4. Bohmfalk GL, Story JL, Wissinger JP, Brown WE Jr. Bacterial intracranial aneurysm. *J Neurosurg.* 1978 Mar;48(3):369-82. PMID: 580294. doi: 10.3171/jns.1978.48.3.0369.
5. Zanaty M, Chalouhi N, Starke RM, Tjoumakaris S, Gonzalez LF, Hasan D, et al. Endovascular treatment of cerebral mycotic aneurysm: a review of the literature and single center experience. *Biomed Res Int.* 2013;2013:151643. PMID: 24383049; PMCID: PMC3872026. doi: 10.1155/2013/151643.
6. Baddour LM, Wilson WR, Bayer AS, Fowler VG Jr, Tleyjeh IM, Rybak MJ, et al; American Heart Association Committee on Rheumatic Fever, Endocarditis, and Kawasaki Disease of the Council on Cardiovascular Disease in the Young, Council on Clinical Cardiology, Council on Cardiovascular Surgery and Anesthesia, and Stroke Council. Infective Endocarditis in Adults: Diagnosis, Antimicrobial Therapy, and Management of Complications: A Scientific Statement for Healthcare Professionals From the American Heart Association. *Circulation.* 2015 Oct 13;132(15):1435-86. PMID: 26373316. doi: 10.1161/CIR.0000000000000296.
7. Wang A, Chu VH, Athan E, Delahaye F, Freiburger T, Lamas C, et al; ICE-PLUS Investigators. Association between the timing of surgery for complicated, left-sided infective endocarditis and survival. *Am Heart J.* 2019 Apr;210:108-116. PMID: 30802708. doi: 10.1016/j.ahj.2019.01.004.
8. Thuny F, Avierinos JF, Tribouilloy C, Giorgi R, Casalta JP, Milandre L, et al. Impact of cerebrovascular complications on mortality and neurologic outcome during infective endocarditis: a prospective multicentre study. *Eur Heart J.* 2007 May;28(9):1155-61. PMID: 17363448. doi: 10.1093/eurheartj/ehm005.