

# Our experience with cardiac MRI in a tertiary health care center in Nepal

Nirmal Prasad Neupane<sup>1\*</sup>, Kritisha Rajlawot<sup>1</sup>, Chandramani Adhikari<sup>2</sup>, Rikesh Tamrakar<sup>2</sup>, Dipanker prajapati<sup>2</sup>, Rabindra Simkhada<sup>2</sup>, Surakshya Joshi<sup>2</sup>, Birat Krishna Timilsina<sup>2</sup>, Ravi Shahi<sup>2</sup>, Parash Koirala<sup>2</sup>, Marisha Aryal<sup>3</sup>, Rabindra Bhakta Timila<sup>3</sup>, Urmila Shakya<sup>4</sup>

<sup>1</sup> Radiologist (MBBS, MD), Department of Radiodiagnosis and Imaging, Shahid Gangalal National Heart Center, Bansbari, Kathmandu, Nepal

<sup>2</sup> Cardiologist (MBBS, MD), Department of Cardiology, Shahid Gangalal National Heart Center, Bansbari, Kathmandu, Nepal

<sup>3</sup> Cardiac Surgeon, Department of Cardiac Surgery, Shahid Gangalal National Heart Center, Bansbari, Kathmandu, Nepal

<sup>4</sup> Pediatric Cardiologist, Department of Pediatric Cardiology, Shahid Gangalal National Heart Center, Bansbari, Kathmandu, Nepal

**Corresponding author:** Dr. Nirmal Prasad Neupane

Radiologist, Shahid Gangalal National Heart Center, Bansbari, Kathmandu, Nepal

**Email:** nirmal.neup@gmail.com

**ORCID ID:** 0000-0001-0863-1873

**Cite this article as:** Neupane, N. P., Rajlawot, K. ., Adhikari, C. M., Tamrakar, R., Prajapati, D., Simkhada, R., Joshi, S., Timilsena, B. K., Shahi, R., Koirala, P., Aryal, M., Timala, R. B., & Shakya, U. Our experience with cardiac MRI in a tertiary health care center in Nepal. *Nepalese Heart Journal* 2024; 21(1), 31-36

**Submission date:** 19 March 2024

**Accepted date:** 21 April 2024

## Abstract

**Background and Aim:** Cardiac Magnetic Resonance (CMR) is a crucial noninvasive imaging technique for the thorough evaluation of the heart in various cardiovascular conditions. The potential to offer quantitative data on cardiac perfusion and function make CMR an exceptional choice of imaging for providing functional and morphological information about the heart. We performed cardiac MR evaluation of patients over a period of 12 months. Our aim was to establish the common cardiac MR indications and the diagnoses in different age groups in our population.

**Method:** A retrospective analysis of patients undergoing CMR at Shahid Gangalal National Heart Center, Kathmandu, Nepal over a period of 12 months, from October 2021 to September 2022 was done. All patients who underwent cardiac MRI at our center, irrespective of age, sex, and indication were included in the study. A total number of 392 patients were included in our study who had undergone Cardiac MRI on a 3Tesla platform at our center. The respective protocols, tailored to the disease being investigated, were followed based on the indication of each patient. Data were entered in a predesigned proforma and SPSS was used for the analysis.

**Results:** The most common indication to perform CMR at our centre was found to be the myocardial viability test. Among 147 patients (37.5 % of the study population) assessed for myocardial viability, 120 (81.6 %) showed infarction in the left anterior descending (LAD) territory, 17 (11.5 %) showed infarction in the LCX territory and 10 (6.8 %) showed RCA territory infarction. The most common cardiomyopathy diagnosed with cardiac MRI at our center was hypertrophic cardiomyopathy (HCM) (15.5 %), followed by dilated cardiomyopathy (DCM) (10.0 %). Other various cardiac MR diagnoses of patients were congenital heart disease (CHD) (5.8 %), arrhythmogenic right ventricular cardiomyopathy (ARVC) (5.6 %), myocarditis (3.0 %), valvular heart disease (VHD) (3.0 %), cardiac mass/pseudo mass (2.0 %), pericarditis (1.7 %), and others (3.3 %). 48 patients that represented about 12.2 % of the total study population who underwent cardiac MRI at our centre had normal CMR findings.

**Conclusion:** Cardiac MRI is an excellent imaging modality in the evaluation of different groups of cardiovascular diseases. It does not only provide the diagnosis but also helps in evaluating the prognostic parameters in different cardiac patients. Hence, the use of CMR is encouraged in clinical practice in our setting to implement early and appropriate therapies in cardiac patients that may ultimately improve patient outcomes.

**Keywords:** Cardiac Magnetic Resonance (CMR), Viability, Hypertrophic cardiomyopathy (HCM), Dilated cardiomyopathy (DCM), Myocarditis, Arrhythmogenic right ventricular cardiomyopathy (ARVC), Congenital heart disease (CHD)

**DOI:** <https://doi.org/10.3126/nhj.v21i1.65648>

## Introduction

Magnetic resonance (MR) imaging, one of the several available radiologic modalities, is acknowledged as a promising noninvasive imaging technique with an improved spatial and temporal resolution, and an absence of ionizing radiation<sup>1</sup>. Cardiac Magnetic Resonance (CMR) is a crucial noninvasive imaging technique for the thorough evaluation of the heart in various cardiovascular

pathologies including viability evaluation, cardiomyopathies, pericardial pathologies and congenital anomalies of the heart<sup>1,2</sup>. The potential to offer quantitative data on cardiac viability, perfusion, and function make CMR an exceptional choice of imaging where the functional and morphological information of the heart can be evaluated through cine images that facilitate quantifying end-diastolic and end-systolic volumes<sup>1</sup>. In addition, CMR is helpful in

the diagnosis of valvular diseases and acquired conditions such as cardiac lesions and masses including metastases. The basic cardiac MRI sequences may generally be divided into bright-blood and black-blood sequences. The bright blood sequence is a gradient echo (GRE) based acquisition that gathers data on cardiac function and blood flow. Bright blood imaging is utilized to assess both segmental and global left ventricular (LV) function which is represented by the high signal intensity of rapidly flowing blood. This sequence aids in the measurements of blood flow, LV mass, myocardial perfusion, and coronary morphology. Black blood sequence is a spin echo (SE) based acquisition that depicts fast-moving blood as having low signal intensity. This sequence primarily aids to characterize cardiac wall, pericardium and the mediastinal anatomy. Delayed gadolinium enhancement (DGE) is another valuable sequence in which gadolinium is used as a contrast agent and delayed enhancement offers relevant information based on the specific cardiac condition, such as in the detection of myocardial viability, myocardial fibrosis, and so on. As a result, the DGE sequence is acknowledged as the gold standard imaging approach for ischemic and nonischemic cardiomyopathies<sup>1</sup>. Hence, CMR imaging is the decisive and gold standard mode of imaging technique in a wide range of cardiac conditions. The principal objective of this study was to establish the common cardiac MR indications in our setting and the CMR diagnoses in different age groups in our Nepalese population.

## Methods

Our study was a retrospective analysis of patients undergoing CMR at Shahid Gangalal National Heart Center over a period of 12 months, from 1st October, 2021 to 30th September, 2022. All patients who underwent cardiac MRI at our centre in our 3 Tesla MR platform were included in the study. Following the ethical approval of the Institutional Review Board, the data of the patients were obtained retrospectively. A total number of 392 patients were included in our study who had performed Cardiac MRI at our centre. The CMR sequences including the black blood and the bright blood images were carried out in all the patients. The short-tau inversion recovery (STIR) images were obtained from the base to the apex of the heart in the short-axis view. The delayed gadolinium enhancement (DGE) phase-sensitive inversion recovery (PSIR) sequences were obtained in short-axis, four-chamber, and vertical long-axis views. The respective protocols were followed based on the indication of each patient undergoing CMR.

### CMR features for diagnosis

For the myocardial viability test, three principal protocols were evaluated: wall motion using cine gradient echo, resting perfusion by first-pass contrast-enhanced studies, and infarction/scar by delayed gadolinium-enhanced inversion recovery imaging. All coronary artery territories were analyzed, and the affected coronary arteries and infarcted segments were localized based on the varying extent of delayed GAD enhancement in the myocardium. Bull's eye diagram was given illustrating the viable and the non-viable segments in different territories.

For the evaluation of cardiomyopathies, the ventricular volumes were evaluated along with the wall thickness, ventricular systolic function (ejection fraction), and myocardial mass. We used the diagnostic parameter of the maximal left ventricular wall thickness of  $\geq 15$  mm in the end-diastolic phase in conjunction with left ventricular outflow (LVOT) obstruction plus with or without systolic anterior motion (SAM) of the mitral valve to diagnosis hypertrophic cardiomyopathy (HCM). In the diagnosis of dilated cardiomyopathy

(DCM), ventricular dilatation associated with thinning of the ventricular wall along with the left ventricular ejection fraction was assessed. To diagnose infiltrative cardiomyopathies, T2/STIR images were examined for the presence of inflammation and edema and delayed GAD images for the scar tissue or fibrosis. The characteristic CMR features to diagnose amyloidosis used were concentric, symmetric or asymmetric thickening of the left ventricle wall, difficulty in nullifying the myocardium, elevated native T1 time and extracellular volume (ECV), disproportionate atrial enlargement with diffuse, subendocardial, or patchy enhancement patterns in LGE sequences. The non-compaction cardiomyopathy was assessed based on the ratio of noncompacted to compacted myocardium where the threshold of a ratio above 2.3, measured at end-diastole, was used.

The modified Lake Louise criteria were followed for the diagnosis of acute myocarditis wherein the myocardial edema was identified by a visible regional high T2 signal intensity on the STIR sequence. Patchy / diffuse subepicardial or mid myocardial delayed GAD enhancement was identified in these patients that represented the retention of contrast agents in the affected myocardial tissue.

The modified task force criteria were followed in the diagnosis of arrhythmogenic right ventricular cardiomyopathy (ARVC). Right ventricular dyssynchronous motion along with reduced RVEF were assessed to diagnose ARVC in patients with arrhythmia.

Acute and chronic pericarditis were diagnosed based on the pericardial thickness of  $\geq 4$  mm, depicted as a dark, low signal intensity pericardium (usually associated with significant fibrocalcific changes). The post-contrast studies were assessed for the presence of pericardial inflammation and pericardial scar shown by early and late enhancement respectively.

The stack of steady-state fast precession (SSFP) cine images of the whole thorax were used in the evaluation of CHDs. Both the vascular and valvular flow were assessed, shunts were quantified, and left as well as right ventricular myocardial function was measured.

Data were then entered in a predesigned proforma, and SPSS was applied to do the analysis.

## Results

### Study population

Out of 392 patients, 269 (68.6%) were male with age ranging from 8 to 82, and 123 (31.4%) were female with age ranging from 13 to 86 (Figure 1). The most common age group of patients referred to us for the CMR evaluation was between 51 to 60 years of age. This represented 24.5% of our study population (Figure 2).

### CMR indications and diagnoses

The most common indication to perform cardiac MRI at our centre was for viability evaluation, comprising of 37.5% of the study population (147 cases). Among the patients evaluated for viability, 114 (77.5%) were male and 33 (22.4%) were female. Among 147 patients (37.5% of the study population) assessed for myocardial viability, 120 (81.6%) showed infarction in the left anterior descending (LAD) territory, 17 (11.5%) showed infarction in the left circumflex artery (LCX) territory and 10 (6.8%) showed infarction in the right coronary artery (RCA) territory. The most common cardiomyopathy diagnosed with cardiac MRI at our

center was hypertrophic cardiomyopathy (HCM) which comprised of 61 cases (15.5%) followed by dilated cardiomyopathy (DCM) comprising of 39 cases (10.0%). Other cardiac MR diagnoses of patients were 23 (5.8%) of congenital heart disease (CHD), 22 (5.6%) arrhythmogenic right ventricular cardiomyopathy (ARVC), 12 (3.0%) valvular heart disease (VHD), 12 (3.0%) myocarditis, 8 (2.0%) cardiac mass/pseudo mass, 7 (1.7%) pericarditis and 13 (3.3%) others. About 48 (12.2%) number of patients who underwent cardiac MRI had normal CMR findings (Table 1) (Figure 3). In patients diagnosed with HCM, the most common variant was septal form of hypertrophic cardiomyopathy 27 cases (44.2%), followed by concentric form 26 cases (42.6%), apical 6 (9.8%), and basal 2 (3.2%). Out of 39 (10.0%) cases of DCM, 27 (69.2%) were ischemic and 12 (30.7%) were non-ischemic DCM. Among various congenital diseases, Ebstein's anomaly 17 (73.9%) was found to be the most common indication for cardiac MRI at our center followed by follow-up cases of tetralogy of fallot (TOF). We had 8 cases of cardiac masses in this time period who came to us for CMR evaluation. Among the 8 cases, 50% were diagnosed to have pseudomass or thrombus by CMR. Cardiac pseudo-masses seen included right atrial appendage thrombus, caseous calcification of mitral annulus (CCMA), and LV cavity apical thrombus. There were 7 cases of pericarditis representing 1.7% of the study population. Few miscellaneous conditions were grouped in other categories, which included iron overload cardiomyopathy, ventricular non compaction and subendocardial fibroelastosis amongst others (Table 1, Figure 3).

**Table 1.** Number of patients based on CMR diagnosis

S.N	CMR Diagnosis	Number of patients (%)
1.	Viability a. Left anterior descending (LAD) territory infarction b. Left circumflex artery (LCX) territory infarction c. Right Coronary Artery (RCA) territory infarction	147 (37.5) 120 (81.6) 17 (11.5) 10 (6.8)
2.	Hypertrophic Cardiomyopathy (HCM) a. Septal b. Concentric c. Apical c. Basal	61 (15.5) 27 (44.2) 26 (42.6) 6 (9.8) 2 (3.2)
3.	Dilated Cardiomyopathy (DCM) a. Ischemic b. Non-ischemic DCM	39 (10.0) 27 (69.2) 12 (30.7)
4.	Congenital Heart Disease (CHD) a. Ebstein's anomaly b. Tetralogy of fallot (TOF) c. Transposition of great arteries (TGA) d. Total anomalous pulmonary venous connection (TAPVC) e. Ventricular septal defect (VSD)	23 (5.8) 17 (73.9) 2 (8.6) 2 (8.6) 1 (4.3) 1 (4.3)

5.	Arrhythmogenic right ventricular cardiomyopathy (ARVC)	22 (5.6)
6.	Myocarditis	12 (3.0)
7.	Valvular Heart Disease (VHD)	12 (3.0)
8.	Cardiac mass/Pseudomass a. Metastases b. Cardiac mass c. Pseudomass • Right atrial appendage thrombus • Caseous calcification of mitral annulus (CCMA) • LV cavity thrombus	8 (2.0) 2 (25) 2 (25) 4 (50) 1 (25.0) 1 (25.0) 2 (50.0)
9.	Pericarditis	7 (1.7)
10.	Others a. Infiltrative cardiomyopathy b. Amyloidosis c. Non-compaction cardiomyopathy d. Iron overload e. Subendocardial fibroelastosis f. Pericarditis	13 (3.3) 5 (1.3) 3 (0.8) 2 (0.5) 1 (0.2) 1 (0.2) 1 (0.2)
11.	Normal	48 (12.2)

## Discussion

There are numerous causes of chest pain and the timely recognition of the etiology is of utmost importance as treatment and prognosis vary among different conditions. In spite of the availability of several modern therapeutic options, up to one-third of individuals with acute myocardial infarction (MI) experience clinical heart failure, which continues to be a common and major healthcare burden<sup>3,4</sup>. Following an MI, the detection of viable myocardium has significant implications to predict the possible advantages of revascularization. CMR with a good spatial resolution has been established as the gold standard for evaluating viability based on the presence and pattern of DGE that estimates myocardial scar. A viability assessment using CMR can offer crucial diagnosis and prognosis in cases of complicated coronary disease with simultaneous left ventricular (LV) dysfunction<sup>5,6</sup>. In acute care, CMR has the role to rule out inconclusive diagnoses, evaluate risk stratification for patients with coronary artery disease, and identify the risk of future cardiac events such as reinfarction or heart failure. As per the American Heart Association's guidelines, CMR may be an alternative method to examine patients planned for conventional percutaneous coronary intervention. Similarly, the European Society of Cardiology encourages non-invasive screening in patients suspected of having acute coronary syndrome but with negative cardiac biomarkers and normal or ambiguous electrocardiographic changes. In such circumstances, CMR may meet the key objective of excluding causes of acute chest pain in addition to identifying inconclusive clinical diagnoses<sup>3,7,8</sup>.

Based on gender predilection, males are at higher risk of suffering ischemic heart disease as shown by previous studies which is consistent with the result in our study. The age distribution revealed the prevalence of the disease increases with advancing age<sup>9,10</sup>. The

leading causes behind male predominance could be the lifestyle factors such as smoking, unhealthy eating habits, obesity, and social stress amongst others. Therefore, on a positive note, appropriate precautions if taken may lower the likelihood of developing ischemic heart disease. Overall, CMR can play a crucial role as an essential modality of choice to evaluate myocardial viability that can guide in management by assisting to decide the revascularization of the diseased vessel.

In the present study, 48 patients which represent about 12.2% of the study population showed normal CMR findings. Most of those cases were sent for the evaluation of unexplained arrhythmias. Few of the patients were sent with the suspicion of acute myocarditis. However, none of them showed definite arrhythmogenic foci or features of myocarditis as edema and delayed GAD enhancement. Ventricular arrhythmias may occur in patients with different structural heart diseases such as cardiomyopathies, chronic myocarditis, and healed myocardial infarction or they can be idiopathic in origin. It is essential to timely recognize ventricular arrhythmias related to cardiac causes from idiopathic ones as myocardial structural abnormalities carry the risk of causing sudden cardiac death. CMR with tissue characterization techniques can aid in the identification and characterization of the arrhythmogenic substrate in individuals with ventricular arrhythmias. Furthermore, previous studies have revealed that arrhythmia is frequently seen in men at around the age of 40, which is consistent with our findings in the form of ARVC<sup>11,12</sup>. Normal CMR findings in few of the arrhythmia patients might be related to the idiopathic arrhythmias.

The fact that HCM was frequently found among men in our study is supported by previous studies on HCM that have consistently revealed a male predominance<sup>13,14</sup>. The findings of young individuals usually having HCM with frequent involvement of interventricular septum are also consistent with earlier research<sup>15,16,17</sup>. Besides gender and age predilection, the extraordinary temporal and spatial resolution, features like tissue characterization, and the capacity to image in any desired tissue plane make CMR a crucial imaging tool guiding not only in the diagnosis but also in evaluation of the prognostic parameters<sup>17</sup>.

In every 1000 newborns, congenital heart disease (CHD) is seen in about 6-8 cases. Early diagnosis and treatment have improved the survival rate of CHD patients making them through to adulthood<sup>18</sup>. However, there are still a certain number of the adult population with CHD, who go unnoticed and present late. The role of CMR imaging is constantly growing in evaluating congenital heart diseases in both pediatric and adult patients due to its non-invasiveness and lack of ionizing radiation. Moreover, CMR has emerged as a tool of imaging for CHD patients who have had surgical repairs and require a lifelong follow-up in order to monitor interval changes allowing for serial comparisons without the need of being exposed to radiation<sup>19</sup>. Hence, by providing accurate ventricular volume, function, arterial flow, information on regurgitation, and three-dimensional contrast angiography providing additional anatomical information plus late gadolinium sequences characterizing several pathologies, CMR is the preferred imaging technique to assess any possible CHD patients including the follow-up cases of post-surgical intervention. We had limited evaluation of congenital heart diseases in the pediatric population because of unavailability of all the required MR compatible instruments and pediatric anesthesia set ups in our MR system.

Therefore, in the clinical scenario of our center (which largely

represents the scenario of the whole country), we have found CMR to be an efficient imaging modality to aid both in the diagnosis and management of patients of different cardiac conditions.

### Limitations:

This study however has some limitations. The prolonged scan time required for the imaging and the patient's ability to follow breath-holding commands led to artifacts in few of the studies thus necessitating further processing during image acquisition. Secondly, considering the fact that CMR has only recently been introduced and practiced in Nepal, this study is a pioneering effort to gather data on the prevalent cardiac conditions encountered in a national cardiac center of Nepal. There are no other centers yet in our country where the CMR is regularly practiced. This is only a single-centered study done over a period of one year. A multicenter study in a larger population is warranted in the future to have a more precise understanding of the different cardiac conditions prevalent in our Nepalese population.

### Conclusion

In conclusion, we found CMR to be an excellent imaging modality in the evaluation of different groups of cardiovascular diseases. The various methodologies of CMR such as cine-CMR to examine the morphology and function of the heart, and contrast-enhanced CMR to detect myocardial infarctions and characterize tissue non-invasively make it a unique tool that can be used alone or in combination with other imaging modalities for proper diagnosis and treatment. It does not only provide the diagnosis but also helps in evaluating the prognostic parameters in different cardiac patients. Hence, the use of CMR is encouraged in clinical practice to implement early and appropriate therapies that may ultimately improve patient outcomes.

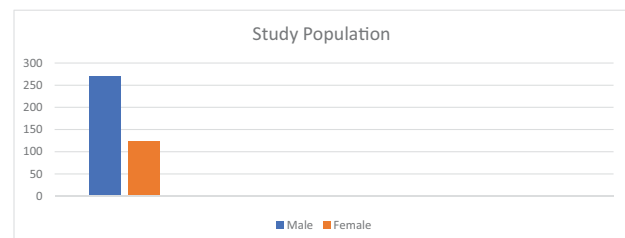


Figure 1. Distribution of the study population according to gender

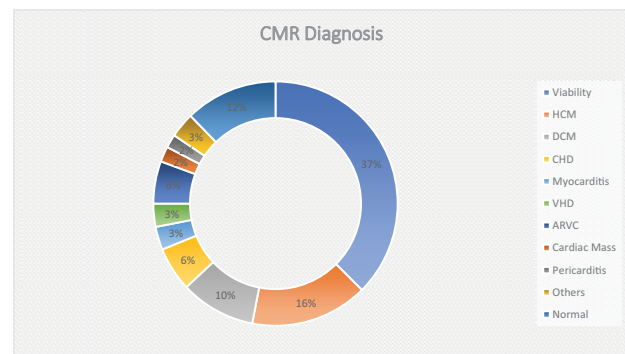


Figure 2. Distribution of the study population according to age



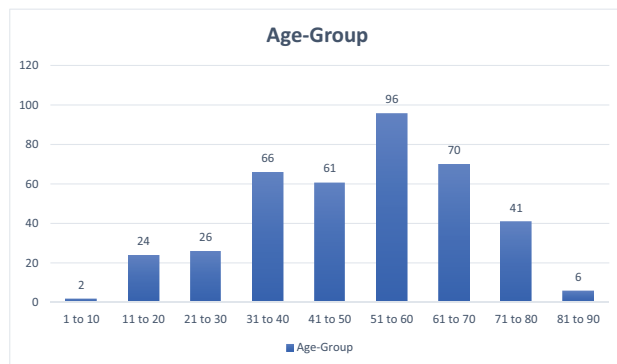


Figure 3. Distribution of the study population according to CMR diagnosis

### Funding

No funding of any kind was obtained for this study.

### Conflict of interests

Dr Marisha Aryal, Executive Editor of Nepalese Heart Journal did not participate in the editorial process of this article.

### References:

- Saeed M, Van TA, Krug R, Hettis SW, Wilson MW. Cardiac MR imaging: current status and future direction. *Cardiovasc Diagn Ther.* 2015 Aug;5(4):290-310. DOI: 10.3978/j.issn.2223-3652.2015.06.07. PMID:26331113;PMCID:PMC4536478.
- Leiner T, Strijkers G. Advances in cardiovascular MR imaging. *MAGMA.* 2018 Feb;31(1):3-6. DOI: 10.1007/s10334-018-0676-x. PMID: 29411168.
- Broncano J, Bhalla S, Caro P, Hidalgo A, Vargas D, Williamson E, Gutiérrez F, Luna A. Cardiac MRI in Patients with Acute Chest Pain. *Radiographics.* 2021 Jan-Feb;41(1):8-31. DOI: 10.1148/rg.2021200084. Epub 2020 Dec 18. PMID: 33337967.
- Garcia MJ, Kwong RY, Scherrer-Crosbie M, Taub CC, Blankstein R, Lima J, Bonow RO, Eshtehardi P, Bois JP; American Heart Association Council on Cardiovascular Radiology and Intervention and Council on Clinical Cardiology. State of the Art: Imaging for Myocardial Viability: A Scientific Statement From the American Heart Association. *Circ Cardiovasc Imaging.* 2020 Jul;13(7):e000053. DOI: 10.1161/HCI.0000000000000053. Epub 2020 Jul 13. PMID: 32833510.
- Kim RJ, Wu E, Rafael A, Chen EL, Parker MA, Simonetti O, Klocke FJ, Bonow RO, Judd RM. The use of contrast-enhanced magnetic resonance imaging to identify reversible myocardial dysfunction. *N Engl J Med.* 2000 Nov 16;343(20):1445-53. DOI: 10.1056/NEJM200011163432003. PMID: 11078769.
- Al-Sabeq B, Nabi F, Shah DJ. Assessment of myocardial viability by cardiac MRI. *Curr Opin Cardiol.* 2019 Sep;34(5):502-509. DOI: 10.1097/HCO.0000000000000656. PMID: 31394561; PMCID: PMC7546497.
- Gibler WB, Cannon CP, Blomkalns AL, Char DM, Drew BJ, Hollander JE, Jaffe AS, Jesse RL, Newby LK, Ohman EM, Peterson ED, Pollack CV; American Heart Association Council on Clinical Cardiology (Subcommittee on Acute Cardiac Care); Council on Cardiovascular Nursing, and Quality of Care and Outcomes Research Interdisciplinary Working Group; Society of Chest Pain Centers. Practical implementation of the guidelines for unstable angina/non-ST-segment elevation myocardial infarction in the emergency department: a scientific statement from the American Heart Association Council on Clinical Cardiology (Subcommittee on Acute Cardiac Care), Council on Cardiovascular Nursing, and Quality of Care and Outcomes Research Interdisciplinary Working Group, in Collaboration With the Society of Chest Pain Centers. *Circulation.* 2005 May 24;111(20):2699-710. DOI: 10.1161/01.CIR.0000165556.44271.BE. PMID: 15911720.
- Task Force for Diagnosis and Treatment of Non-ST-Segment Elevation Acute Coronary Syndromes of European Society of Cardiology, Bassand JP, Hamm CW, Ardissino D, Boersma E, Budaj A, Fernández-Avilés F, Fox KA, Hasdai D, Ohman EM, Wallentin L, Wijns W. Guidelines for the diagnosis and treatment of non-ST-segment elevation acute coronary syndromes. *Eur Heart J.* 2007 Jul;28(13):1598-660. DOI: 10.1093/eurheartj/ehm161. Epub 2007 Jun 14. PMID: 17569677.
- Khan MA, Hashim MJ, Mustafa H, Baniyas MY, Al Suwaidi SKBM, AlKatheeri R, Alblooshi FMK, Almatrooshi MEAH, Alzaabi MEH, Al Darmaki RS, Lootah SNAH. Global Epidemiology of Ischemic Heart Disease: Results from the Global Burden of Disease Study. *Cureus.* 2020 Jul 23;12(7):e9349. DOI: 10.7759/cureus.9349. PMID: 32742886; PMCID: PMC7384703.
- Nichols M, Townsend N, Scarborough P, Rayner M. Trends in age-specific coronary heart disease mortality in the European Union over three decades: 1980-2009. *Eur Heart J.* 2013 Oct;34(39):3017-27. DOI: 10.1093/eurheartj/eh159. Epub 2013 Jun 25. PMID: 23801825; PMCID: PMC3796269.
- Muser D, Santangeli P, Selvanayagam JB, Nucifora G. Role of Cardiac Magnetic Resonance Imaging in Patients with Idiopathic Ventricular Arrhythmias. *Curr Cardiol Rev.* 2019;15(1):12-23. doi: 10.2174/1573403X14666180925095923. PMID: 30251607; PMCID: PMC6367696.
- Nucifora G, Muser D, Masci PG, Barison A, Rebellato L, Piccoli G, Daleffe E, Toniolo M, Zanuttini D, Facchin D, Lombardi M, Proclemer A. Prevalence and prognostic value of concealed structural abnormalities in patients with apparently idiopathic ventricular arrhythmias of left versus right ventricular origin: a magnetic resonance imaging study. *Circ Arrhythm Electrophysiol.* 2014 Jun;7(3):456-62. doi: 10.1161/CIRCEP.113.001172. Epub 2014 Apr 25. PMID: 24771543.
- Siontis KC, Ommen SR, Geske JB. Sex, Survival, and Cardiomyopathy: Differences Between Men and Women With Hypertrophic Cardiomyopathy. *J Am Heart Assoc.* 2019 Nov 5;8(21):e014448. DOI: 10.1161/JAHA.119.014448. Epub 2019 Oct 30. PMID: 31663428; PMCID: PMC6898853.
- Trongtorsak A, Polpichai N, Thangjui S, Kewcharoen J, Yodsuan R, Devkota A, Friedman HJ, Estrada AQ. Gender-Related Differences in Hypertrophic Cardiomyopathy: A Systematic Review and Meta-Analysis. *Pulse (Basel).* 2021 Aug 2;9(1-2):38-46. DOI: 10.1159/000517618. PMID: 34722354; PMCID: PMC8527921.
- Amano Y, Kitamura M, Takano H, Yanagisawa F, Tachi M, Suzuki Y, Kumita S, Takayama M. Cardiac MR Imaging

- of Hypertrophic Cardiomyopathy: Techniques, Findings, and Clinical Relevance. *Magn Reson Med Sci*. 2018 Apr 10;17(2):120-131. DOI: 10.2463/mrms.rev.2017-0145. Epub 2018 Jan 18. PMID: 29343659; PMCID: PMC5891337.
16. Hansen MW, Merchant N. MRI of hypertrophic cardiomyopathy: part I, MRI appearances. *AJR Am J Roentgenol*. 2007 Dec;189(6):1335-43. DOI: 10.2214/AJR.07.2286. PMID: 18029869.
  17. Morgan RB, Kwong R. Role of Cardiac MRI in the Assessment of Cardiomyopathy. *Curr Treat Options Cardiovasc Med*. 2015 Nov;17(11):53. doi: 10.1007/s11936-015-0410-1. PMID: 26446716.
  18. Ntsinjana HN, Hughes ML, Taylor AM. The role of cardiovascular magnetic resonance in pediatric congenital heart disease. *J Cardiovasc Magn Reson*. 2011 Sep 21;13(1):51. DOI: 10.1186/1532-429X-13-51. PMID: 21936913; PMCID: PMC3210092.
  19. Partington SL, Valente AM. Cardiac magnetic resonance in adults with congenital heart disease. *Methodist Debaquey Cardiovasc J*. 2013 Jul-Sep;9(3):156-62. doi: 10.14797/mdcj-9-3-156. PMID: 24066199; PMCID: PMC3782323.