

Bi-atrial Thrombi in a Structurally and Functionally Normal Heart; Ticking Time Bomb

Rajib Rajbhandari¹, Jageshwar Prasad Shah¹, Sarbagya Manandhar¹, Arya Pradhan¹,
Rebika Dongol¹

¹ Department of Cardiology B and B hospital, Lalitpur, Nepal

Corresponding Author: Rajib Rajbhandari
Department of Cardiology B and B hospital, Lalitpur, Nepal
Email: rajibrbhandari@yahoo.com
ORCID ID NO: 0000-0002-2549-0363

Cite this article as: Rajbhandari R, Shah JP, Manandhar S, et al. Bi-atrial Thrombi in a Structurally and Functionally Normal Heart; Ticking Time Bomb. Nepalese Heart Journal 2023; Vol 20(1), 65-66

Submission date: 12th January, 2023
Accepted date: 15th March, 2023

Abstract

We report a case of bi-atrial thrombi traversing the atrioventricular valves in a 72-year-old female with multiple thromboembolic phenomena. Right atrial thrombus can be seen in patients who are immobilized for long period of time and those with deep vein thrombosis and pulmonary embolism. And the left atrial thrombus may present in a case of atrial fibrillation but not common in patients with sinus rhythm. This patient is unique having thrombus in both the atria. She initially presented with ischemic stroke. Echocardiography revealed bi-atrial clots. Later, she developed pulmonary embolism followed by acute right upper limb ischemia. The patient refused all invasive treatments and was managed with anticoagulants only. The patient responded well to therapy with complete thrombus resolution without any significant complications.

Keywords: Bi-atrial thrombus, Systemic embolization, Anticoagulation

DOI: <https://doi.org/10.3126/njh.v20i1.55051>

Introduction

Left Atrial thrombus is relatively common in patients with atrial fibrillation¹ or valvular heart diseases such as mitral stenosis.² However, it is a rare finding in patients with a structurally and functionally normal heart. It usually leads to ischemic stroke, acute limb ischemia, bowel ischemia, and other systemic embolisms.

Right atrial thrombus is an underdiagnosed entity. They are known for their propensity to pass clots to the pulmonary vasculature and their tendency to cause paradoxical stroke through shunts.^{3,4}

Simultaneous bi-atrial thrombus is not a common phenomenon. However, this we do find in patients with coagulopathies and intracardiac shunts.⁵

Case Presentation

A 72-year-old female patient presented to the emergency department with features suggestive of an ischemic stroke. MRI of the brain revealed a right parieto-occipital infarct. She was under medication for hypertension, type 2 diabetes mellitus and dyslipidemia. She had no history of atrial fibrillation or any structural heart disease. However, the patient had been bedridden due to recent spinal surgery.

On presentation, she had weakness on the left side of her body and decreased level of consciousness. The patient was admitted to the intensive care unit and managed conservatively. Electrocardiography revealed sinus tachycardia with non-specific changes. Transthoracic echocardiography showed clots in the right atrium measuring 3.3x1.1 cm and in the left atrium measuring 2.7 X1.3 cm. After two days of conservative treatment with enoxaparin

overlapping with novel oral anti-coagulation, she complained of dyspnea and chest pain. Urgent cardiac CT confirmed bi-atrial thrombi with pulmonary embolism resulting in right pulmonary infarction. The patient was advised for thrombolysis with possibility of need for mechanical thrombectomy. But the patient relatives refused to give consent for any invasive treatment so she was managed conservatively only with anticoagulants. A few days later, the patient complained of coldness in the right upper limb, and the right radial pulse was not palpable. Arterial Doppler revealed a significant blockage in the right brachiocephalic artery, later confirmed by Digital Subtraction Angiography. Again, the patient was continued on anticoagulants only. Eventually she responded well to therapy with complete resolution of the thrombi in both the atria in 20 days which was observed in echocardiography.

Investigation: Her kidney and liver functions, blood counts and hemoglobin were in normal range. Bleeding profile (bleeding time, clotting time, INR) were in normal range. D-dimer was high (1.5mcg/ml). Protein C level was 35 IU/dL (significantly lower than the normal value of (65-135IU/dL). Troponin-I level was also high (1.5 ng/ml) due to pulmonary embolism. ABG analysis showed normal PaO₂ level. Chest X-ray showed nonspecific patches at bilateral bases of lungs which was present in her old X-ray. ECG showed RBBB in sinus rhythm similar to her previous ECG. Echocardiography showed large biatrial clot traversing through the AV valves. There was mild mitral and tricuspid regurgitation.

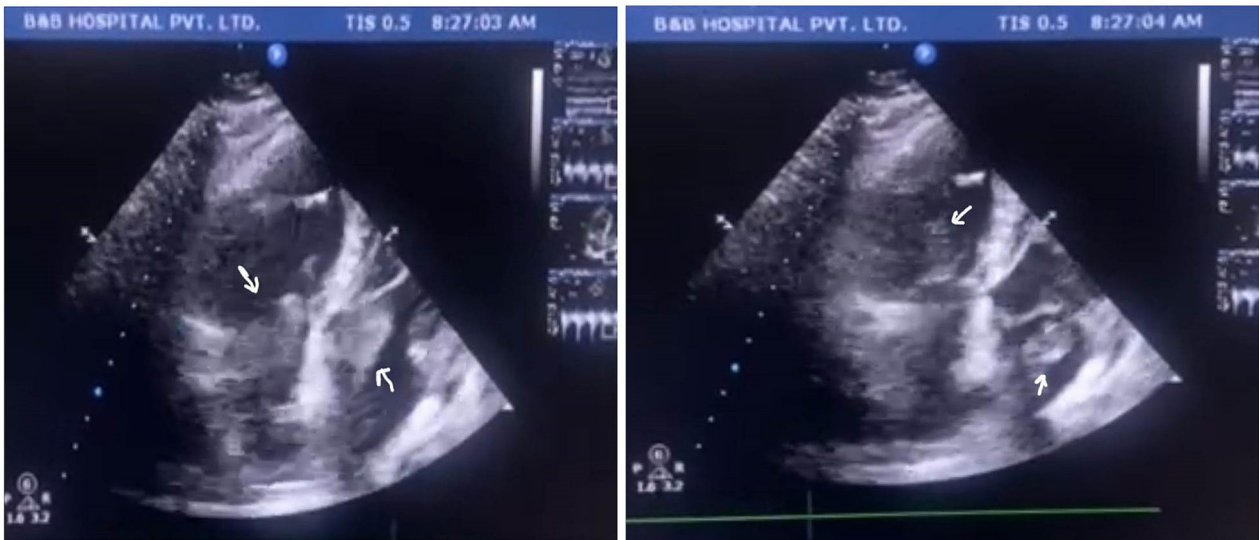


Figure 1: Bi-atrial thrombus traversing through AV valves

Discussion

Most systemic emboli (80%) arise from intracardiac mural thrombi; two-thirds are associated with left ventricular infarcts, and another 25% with dilated left atria (e.g., mitral valve disease). The remainder originates from aortic aneurysms, ulcerated atherosclerotic plaques, and fragmented valvular vegetations or the venous system (paradoxical emboli); 10% to 15% of systemic emboli are of unknown origin.

Our patient most likely had a hypercoagulable state, due to protein C protein S deficiency state. We ruled out other common primary causes such as antithrombin III deficiency. Her serum markers for CA-125 were raised, but she had no symptoms and clinical findings suggestive of breast or endometrial carcinoma. Other conditions that could induce a hyper-coagulable state, such as antiphospholipid syndrome, hyper-estrogenic state, sickle cell anemia, cardiac prosthesis, and smoking, were absent.

Although right atrial thrombus is treated with anticoagulants, thrombolytic therapy or surgical thrombectomy, proper management of atrial thrombosis is not yet definitive and it depends upon the hemodynamic stability of the patient and the resources available⁶. Anticoagulants and mechanical thrombectomy remain the cornerstones of treatment.^{7,8} For the selection of treatment, in this case we considered the patient's age, comorbidities, prognosis, and wish of patient and their relatives.

Conclusion

After managing this case of bi-atrial thrombi, we learned that with early diagnosis, close monitoring, and adequate anticoagulation, the outcome could be life-saving. We are glad to report that the patient recovered without grave consequences and is in regular follow-up since then. She is currently being treated with novel oral anticoagulants and she is doing well.

References

1. Lurie A, Wang J, Hinnegan KJ, McIntyre WF, Belley-Côté EP, Amit G, Healey JS, Connolly SJ, Wong JA. Prevalence of Left Atrial Thrombus in Anticoagulated Patients With Atrial Fibrillation. *J Am Coll Cardiol*. 2021 Jun 15;77(23):2875-2886. doi: 10.1016/j.jacc.2021.04.036.
2. Kronzon I, Tunick PA, Glassman E, Slater J, Schwinger M, Freedberg RS. Transesophageal echocardiography to detect atrial clots in candidates for percutaneous transseptal mitral balloon valvuloplasty. *J Am Coll Cardiol*. 1990 Nov;16(5):1320-2. doi: 10.1016/0735-1097(90)90572-7.
3. Benjamin MM, Afzal A, Chamogeorgakis T, Feghali GA. Right atrial thrombus and its causes, complications, and therapy. *Proc (Bayl Univ Med Cent)*. 2017 Jan;30(1):54-56. doi: 10.1080/08998280.2017.11929526.
4. Selwanos, P.P.S., Ahmed, A.O., El Bakry, K.M. et al. Management of a huge right atrial thrombus in a patient with multiple comorbidities. *Egypt Heart J* 72, 79 (2020). doi:10.1186/s43044-020-00112-x
5. Sattar A, Win TT, Schevchuck A, Achrekar A. Extensive biatrial thrombus straddling the patent foramen ovale and traversing into the left and right ventricle. *BMJ Case Rep*. 2016 Nov 21;2016:bcr2016216761. doi: 10.1136/bcr-2016-216761.
6. Sattar A, Win TT, Schevchuck A, Achrekar A. Extensive biatrial thrombus straddling the patent foramen ovale and traversing into the left and right ventricle. *BMJ Case Rep*. 2016 Nov 21; 2016:bcr2016216761. doi: 10.1136/bcr-2016-216761.
7. Mohan B, Chhabra ST, Gulati A, Mohan Mittal C, Mohan G, Tandon R, Kumbkarni S, Aslam N, Sood NK, Wander GS. Clinical and echocardiographic diagnosis, follow up and management of right-sided cardiac thrombi. *Indian Heart J*. 2013 Sep-Oct;65(5):529-35. doi: 10.1016/j.ihj.2013.08.015.
8. Kandpal B, Garg N, Anand KV, Kapoor A, Sinha N. Role of oral anticoagulation and inoue balloon mitral valvulotomy in presence of left atrial thrombus: a prospective serial transesophageal echocardiographic study. *J Heart Valve Dis*. 2002 Jul;11(4):594-600. PMID: 12150310