

Verapamil for treatment of Fetal Supraventricular Tachycardia

Amit Kumar Singh¹, Murari Thakur², Ruby Singh², Jitendra Mandal³.

¹ Shahid Gangalal National Heart Centre, Janakpur Branch, Janakpur, Nepal,

² Department of Gynaecology, Provincial Hospital, Madhesh Province, Nepal

³ Department of Radiology, Provincial Hospital, Madhesh Province, Nepal

Corresponding Author: Amit Kumar Singh

Shahid Gangalal National Heart Centre, Janakpur Branch, Janakpur, Nepal

Email: dramitsgnhc@gmail.com

ORCID ID NO: 0000-0003-4496-0436

Cite this article as: Singh A. K., Thakur M, Singh R., et al. Verapamil for treatment of Fetal Supraventricular Tachycardia Nepalese Heart Journal 2023; Vol 20(1), 57-59

Submission date: 5th March, 2023

Accepted date: 5th April, 2023

Abstract

Fetal arrhythmia is reported to affect 1-2% of pregnancies.¹ Besides digoxin not many drugs have been tried in treating such cases. After confirming 1:1 conduction between atrium and ventricle, no structural heart disease of fetus and normal echocardiography and ECG of mother, verapamil was given in the treatment of fetal supraventricular tachycardia. The drug crossed placenta to revert fetus SVT to sinus rhythm without harming mother. The treatment helped fetus against possible complications.

Keywords: Verapamil, Fetal supraventricular tachycardia

DOI: <https://doi.org/10.3126/njh.v20i1.55042>

Introduction

Fetal supraventricular tachycardia is a less talked phenomenon. It's a less reported abnormality in fetus although 1-2% of the pregnancies seem to be affected with fetal arrhythmia.¹ Diagnosis for the arrhythmia is relied on some basic factors seen in fetal echocardiography. Such arrhythmia may lead to mortality of fetus if untreated. Early detection and treatment help in improving the fetal outcome. Verapamil in suspected narrow complex tachycardia may be a good option in the treatment.

Case Report

This is a case of a 23 years old lady with 4th gravida presenting in 29 weeks of her pregnancy. The case was referred for fetal echo for fetus having tachycardia of 232bpm, moderate pericardial effusion and mild ascites. The fetus underwent fetal echocardiography. It showed situs solitus, levocardia, normal cardiac angle, normal 4 chamber view, 3 vessel view and normal flow direction in left sided aortic arch. Hydrops fetalis was present. The fetus heart rate was found to be 231bpm. In echocardiography, M-mode was placed through atrium and ventricle simultaneously. It showed same rate for both the chambers denoting it to be supraventricular tachycardia (Fig no. 1). The findings ruled out possibility of atrial fibrillation or atrial flutter with differential conduction. We were left with possible diagnosis of AVNRT, AVRT, Atrial tachycardia.

The parents were counselled for the poor prognosis of the child as the fetus had developed hydrops fetalis as mortality of one third was observed in fetus developing hydrops fetalis^{1,2} They were given

option for trial of therapeutics in mother to hope for recovery of the fetus. The mother underwent echocardiography to rule out possible maternal heart disease. She also underwent 12 lead ECG to rule out contraindication for verapamil like atrial fibrillation and WPW syndrome. She was first given trial of metoprolol succinate 50 mg and the fetus was observed during 2 weeks period. There was little or no response in the fetal heart rate or pericardial effusion. The mother was counselled for oral verapamil considering the tachycardia being AV nodal dependent tachycardia. She was prescribed 120mg verapamil once daily. Mother was observed for any bradycardia or heart failure. The fetus was observed over 4 weeks. She was continuously called every week by her radiologist to look for heart rate and her gynecologist for maternal wellbeing. In two weeks', the heart rate came down to 139bpm. Five chamber view in echocardiography showing both mitral inflow and aortic outflow was taken. Pulse wave doppler was placed at interphase of mitral inflow and aortic outflow region. It showed both E wave and A wave spectral doppler in mitral inflow area which was followed by aortic spectral doppler denoting sinus rhythm. Ejection fraction was estimated to be 60% (Fig no. 2). Pericardial effusion and ascites settled down. The fetus underwent normal delivery. After delivery the neonate underwent ECG showing normal sinus rhythm. The neonate underwent echocardiography showing structurally normal heart with left ventricular ejection fraction of 65%. Parents were made aware of possible SVT in the neonate upcoming life as in one of the studies it was found that half of the fetus had SVT in neonatal life.³

Discussion

Fetal arrhythmia has to be diagnosed on basis of echocardiography. Proper correlation between rate of atrium and ventricle, regularity in rhythm helps in making diagnosis for the type of arrhythmia. In four chamber view M-mode of echocardiogram is taken through atrium and ventricle. The same rate of atrium and ventricle makes the diagnosis of SVT with 1:1 conduction between atrium and ventricle.⁴ To confirm sinus rhythm, spectral doppler in 5 chamber view is taken placing cursor in the interphase of mitral inflow and aortic outflow. Presence of both E wave and A wave of mitral inflow confirms sinus rhythm and following one aortic outflow spectral doppler confirms 1:1 conduction between atrium and ventricle. Bradycardia with higher rate of atrium as compared to ventricle with bradycardia denotes heart block of 2nd and 3rd degree. Tachycardia with higher rate of atrium as compared to ventricle denotes atrial flutter with fixed conduction if regular and atrial fibrillation if irregular or atrial flutter with variable conduction. If the ventricle rate is higher as compared to atrium, ventricular rhythm is suspected. Having close observation towards mother health various therapeutics options maybe tried considering the possible diagnosis of the child arrhythmia. Fetal supraventricular tachycardia has been treated with digoxin.^{5,6} There are other anti-arrhythmic drugs tried too for the treatment of SVT like sotalol and amiodarone.^{7,8} Because of non-availability of digoxin, choice of verapamil was given to the mother. As per the echocardiography evaluation, diagnosis of AVNRT or AVRT was made. In case of adult, verapamil is treatment of choice for AVRT and AVNRT to maintain patient in sinus rhythm. As verapamil readily crosses the placenta and this aspect was used to treat SVT.⁹

Conclusion

Fetal echocardiography can meticulously detect fetal supraventricular tachycardia. M-mode and spectral doppler can help getting defined the type of SVT. Verapamil after screening mother's heart can be used in treatment in suspected SVT other than atrial fibrillation and atrial flutter.

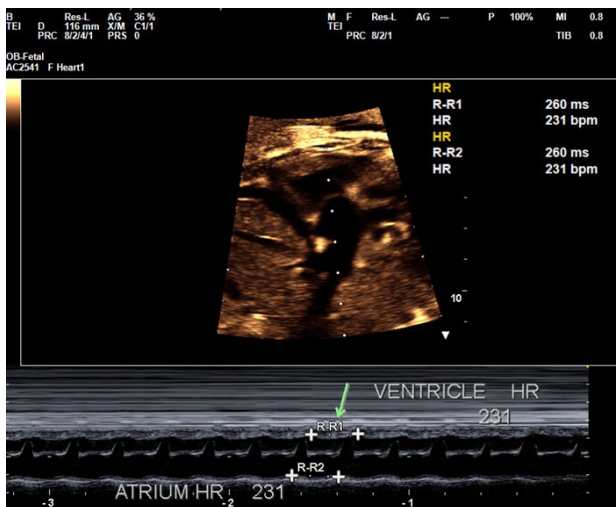


Figure 1. M-mode of SVT atrium HR: atrium rate, ventricle HR: ventricle rate

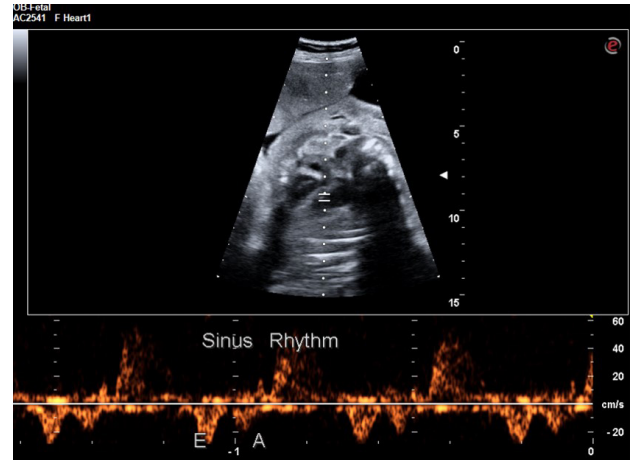


Figure 2. Mitral inflow and aortic outflow view. Mitral spectral doppler showing E wave and A wave followed by aortic outflow doppler

References

1. Bartin R, Maltret A, Nicloux M, Ville Y, Bonnet D, Stirnemann J. Outcomes of sustained fetal tachyarrhythmias after transplacental treatment. *Heart Rhythm* O2 2021;2(2):160–167.
2. O'Leary ET, Alexander ME, Bezzerides VJ, et al. Low mortality in fetal supraventricular tachycardia: Outcomes in a 30-year single-institution experience. *J Cardiovasc Electrophysiol* [homepage on the Internet] 2020 [cited 2023 May 11];31(5):1105–1113. Available from: <https://pubmed.ncbi.nlm.nih.gov/32100356/>
3. Demirci O, Tosun Ö, Bolat G. Prenatal diagnosis and management of fetal supraventricular tachyarrhythmia and postnatal outcomes. *J Gynecol Obstet Hum Reprod* [homepage on the Internet] 2022 [cited 2023 May 11];51(3). Available from: <https://pubmed.ncbi.nlm.nih.gov/35063720/>
4. Jaeggi E, Fouron JC, Fournier A, Doesburg N van, Drblik SP, Proulx F. Ventriculo-atrial time interval measured on M mode echocardiography: a determining element in diagnosis, treatment, and prognosis of fetal supraventricular tachycardia. *Heart* [homepage on the Internet] 1998 [cited 2022 Oct 15];79(6):582–587. Available from: <https://pubmed.ncbi.nlm.nih.gov/10078085/>
5. Zoeller BB. Treatment of Fetal Supraventricular Tachycardia. *Current Treatment Options in Cardiovascular Medicine* 2017 19:1 [homepage on the Internet] 2017 [cited 2022 Nov 10];19(1):1–9. Available from: <https://link.springer.com/article/10.1007/s11936-017-0506-x>
6. Husain A, Hubail Z, Banna R al. Fetal supraventricular tachycardia, treating the baby by targeting the mother. 2013 [cited 2022 Nov 10]; Available from: <http://group.bmj.com/group/rights-licensing/permissions>.

7. Pradhan M, Manisha, Singh R, Kapoor A. Amiodarone in treatment of fetal supraventricular tachycardia. A case report and review of literature. *Fetal Diagn Ther* [homepage on the Internet] 2006 [cited 2023 May 11];21(1):72–76. Available from: <https://pubmed.ncbi.nlm.nih.gov/16354980/>
8. Heijden LB Van Der, Oudijk MA, Manten GTR, Heide H Ter, Pistorius L, Freund MW. Sotalol as first-line treatment for fetal tachycardia and neonatal follow-up. *Ultrasound Obstet Gynecol* [homepage on the Internet] 2013 [cited 2023 May 11];42(3):285–293. Available from: <https://pubmed.ncbi.nlm.nih.gov/23303470/>
9. Adenosine in the treatment of maternal paroxysmal supraventricular tachycardia - PubMed [Homepage on the Internet]. [cited 2022 Nov 7]; Available from: <https://pubmed.ncbi.nlm.nih.gov/1495712/>