

# Coronary Angiography and Percutaneous coronary Intervention in Anomalous Origin of Right Coronary Artery Arising from the Left Sinus of Valsalva.

Chandra Mani Poudel<sup>1</sup>, Ratna Mani Gajurel<sup>1</sup>, Hemant Shrestha<sup>1</sup>, Surya Devkota<sup>1</sup>, Sanjeev Thapa<sup>1</sup>, Rajaram Khanal<sup>1</sup>, Smriti Shakya<sup>1</sup>, Bhawani Manandhar<sup>1</sup>, Vijay Yadav<sup>1</sup>

<sup>1</sup> Manmohan Cardiothoracic Vascular and Transplant Centre, Department of Cardiology, Institute of Medicine, Kathmandu, Nepal.

**Corresponding Author:** Chandra Mani Poudel

Manmohan Cardiothoracic Vascular and Transplant Centre, Department of Cardiology, Institute of Medicine, Kathmandu, Nepal. Telephone number: +977-9851137220.

**E-mail:** chandra\_poudel@yahoo.com

**ORCID ID NO:** 0000-0003-3643-3193

**Cite this article as:** Poudel CM, Gajurel RM, Shrestha H, Devkota S. Coronary Angiography and Percutaneous coronary Intervention in Anomalous Origin of Right Coronary Artery Arising from the Left Sinus of Valsalva. Nepalese Heart Journal 2022; 19(2), 33-36

**Submission date:** 5th June, 2022

**Accepted date:** 25th August, 2022

## Abstract

**Background and Aims:** To assess the difficulties encountered while performing coronary angiography and percutaneous coronary intervention in anomalous right coronary artery arising from the left sinus of Valsalva.

**Methods:** Between January 2016 and December 2020, a total of 23 patients underwent coronary angiography and eight underwent percutaneous coronary intervention for an angiographic significant lesion in the anomalous right coronary artery arising from the left sinus of Valsalva. The vascular approach, usage of catheters, fluoroscopic time, and the amount of contrast used were also assessed.

**Results:** Among 6000 coronary angiography and 1500 percutaneous coronary intervention performed, 33 patients (0.55%) had right coronary artery arising from the left sinus of Valsalva. Altogether, 14 patients had type-A, seven had Type-B, eight had Type-C, and four had Type-D anomalous right coronary artery arising from the left sinus of Valsalva. Coronary Angiography was accomplished with the Tiger catheter in 13 patients, Judkins left JL in 8 patients, and Extra-backup (XB3) in one patient. In the percutaneous coronary intervention group, cannulation was done with Judkins left (JL), Amplatz left (AL), and XB in five, two, and one patient respectively and among five type-A patients, four were cannulated with JL and one with XB; one Type-B with JL4; and two Type-C with AL2. The mean fluoroscopic time and contrast volume consumption for coronary angiography and percutaneous coronary intervention were 9.9 minutes and 47 minutes respectively and 63ml and 229 ml respectively.

**Conclusion:** Coronary angiography and percutaneous coronary intervention of anomalous right coronary artery arising from the left sinus of Valsalva is difficult due to inappropriate selection of catheter and is associated with a higher both mean fluoroscopic time and contrast volume. Radial route is equally effective for successful procedure.

**Keywords:** Anomalous origin of right coronary artery arising from left sinus of Valsalva, coronary angiogram, percutaneous coronary intervention.

**DOI:** <https://doi.org/10.3126/njh.v20i2.48952>

## Introduction

As evidenced by an earlier coronary angiographic series from the various centers, the reported incidence of anomalous origin of the right coronary artery (ARCA) from the left sinus of Valsalva (LSOV) varied between 0.02 and 0.17%.<sup>1</sup> Anomalous origin of coronary arteries is a rare entity reported to be present in 0.2–1.2% of patients undergoing percutaneous coronary intervention (PCI).<sup>2,3</sup> Anomalous origin of right coronary artery has also been documented to originate from the pulmonary artery, left ventricular outflow tract, left main coronary artery, non-coronary sinus of Valsalva, and above the sinus of Valsalva. Its presence is associated with chest pain, syncope, or recurrent ischemia in a young patient that mandates surgical correction.<sup>4</sup> In addition, this anomaly may be associated with an increased risk of developing coronary artery disease.<sup>5</sup>

The angiographic classification of ARCA is based upon its origin and orientation around the left sinus of Valsalva. The classification was first described by Sarkar et al<sup>4</sup> as shown

below in the Figure 1. An unusual location and the course of this coronary anomaly establish a sizeable technical challenge to the interventional cardiologists. A systematic approach is required to evaluate the coronary anatomy in order to avoid the complications. To be more specific, an appropriate selection of the diagnostic and guiding catheters is pivotal for successful selective angiography that will eventually pave the pathway for successful deployment of the coronary stents. We, thus, aim to report the technical difficulties that came across while performing CAG and PCI in patients with ARCA arising from LSOV.

## Methods

**Study Population:** A retrospective data of the patient who had undergone CAG and PCI between January 2016 and December 2020 were collected from the catheterization laboratory records of the Manmohan Cardiothoracic Vascular and Transplant Center (MCVTC), Kathmandu, Nepal.

The two interventional cardiologists independently assessed the origin and takeoff of the RCA within the aortic sinus. The approach was either radial or femoral. A non-ionic low osmolar contrast agent (Iohexol) was used. All diagnostic angiograms were performed with either 5French or 6French catheters. The sheath was upgraded to 6French as necessitated by angiographic findings prior to the start of the PCI. After angiography of the left coronary system, an initial attempt was made to engage the right coronary artery in the left anterior oblique (LAO) projection using the Tiger catheter from the right radial route and Judkins right (JR4) catheter from the right femoral route. If not successful, serial catheter was changed till cannulation of the RCA. In condition that RCA was not successfully engaged, a test injection was given in the right aortic sinus root followed by the left sinus to visualize the RCA origin in the 30°–35° LAO projection. The aortogram was done in order to define the shape and size of the aorta and for showing the position and orientation of the right coronary ostium. The angiographic classification of ARCA was done according to the earlier classification described by Sarkar et al.<sup>4</sup> In the LAO view, the left ventricular outflow tract and aorta looked like a cylinder with a bulge in the middle due to aortic sinuses. An imaginary line was drawn at the upper edge of the bulge in order to divide the aortic sinus and the ascending aorta. A similar imaginary line was drawn along the lower edge of this bulge that divided the aortic cusps from the left ventricular outflow tract. A final imaginary line was drawn along the long axis of the ascending aorta intersecting the sinus, aorta, and aortoventricular planes perpendicularly. The origin of the anomalous RCA was eventually described as: A. Origin from the aorta above the sinotubular plane; B. Origin just below the ostium of the left coronary artery (LCA); C. Origin below the sinotubular plane between the midline and the origin of left coronary artery; D. Origin along the midline. The procedural details such as the puncture site, type of the catheter used, fluoroscopic-time, and the contrast volume were also assessed.

## Results

A total of 6000 CAG and 1500 PCI were performed in the MCVTC between January 2016 and December 2020. Among them, a total of 33 patients were found to have ARCA from LSOV. Altogether, 14 patients had type-A ARCA, seven had type-B, eight had type-C, and the remaining four patients had type-D. Those who underwent CAG, the vascular access site was right radial for 15 patients, right femoral for seven patients and one patient had to shift the access site from radial to femoral due to radial artery spasm. Selective angiograms were successful with the Tiger catheter in 13 patients, JL in eight patients, XB3 in one patient, and a non-selective angiogram was done in one patient. The mean fluoroscopic time for coronary angiography with ARCA arising from LSOV was 9.9 min (range: 2-26 min) and the mean amount of contrast used for angiography was 63ml (range: 30-200ml). The mean fluoroscopic time and contrast volume of coronary angiography taken from hospital data without RCA anomaly was 8 min and 54ml respectively. The coronary angiographic details of 23 patients are shown in Table 1.

Out of 33 patients, 10 patients had angiographically significant coronary artery disease ( $\geq 70\%$  stenosis) and eight of them underwent successful PCI but two of them had a PCI attempted. The vascular access sites were right radial for six patients, right femoral for two patients, and two patients had a shift to right femoral from right radial route. The ARCA cannulation was successful in only eight patients. Amongst the successfully cannulated cohorts, five of them were cannulated with Judkins left [two patients with JL3 (Figure 2), two patients with JL5, and one patient with JL 4], two patients with AL2, and one patient with Extra back up (XB3). Out of five type A ARCAs, four patients were successfully cannulated with JL (two with JL3 and two with JL 5) and one with XB. One patient with type B and two patients with Type C ARCA were successfully cannulated

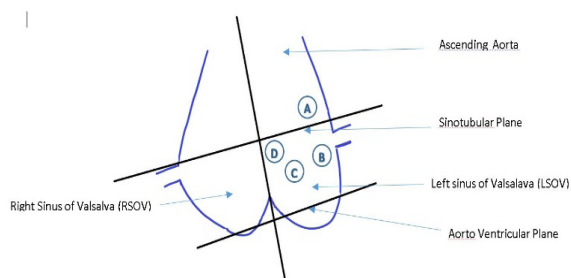
with JL4 and AL2 respectively. The mean fluoroscopic time for PCI of ARCA arising from LSOV was 47 minutes (range: 21-83 min) and the mean amount of contrast used was 229 ml (range: 150-300ml). The mean fluoroscopic time and contrast volume for PCI of RCA without anomaly, taken from hospital data was 22min and 150ml respectively. The details of PCI in 10 ARCA patients are shown in Table 2.

**Table 1:** Coronary angiographic details of the anomalous RCA arising from the Left sinus

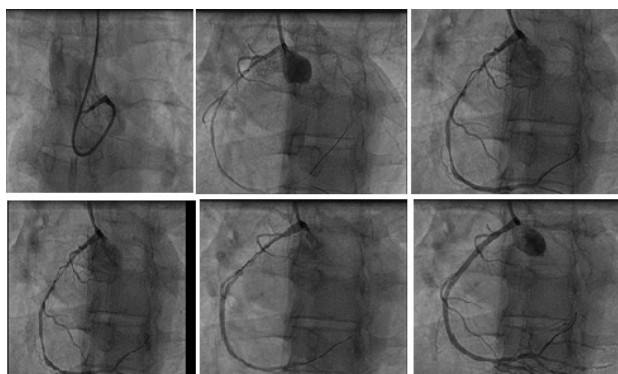
S.No.	Type of coronary anomaly (ARCA arising from left sinus)	Number of time catheters changed	Successfully cannulated catheter	Route / Sheath
1	Type C	2	JL4	Right Femoral /6F
2	Type D	1	Tiger 5F	Right Radial/5F
3	Type A	1	Tiger 5F	Radial /6F
4	Type B	3	JL4	Right femoral/6F
5	Type A	1	Tiger 5F	Right radial/5F
6	Type B	1	Tiger 5F	Right radial /6F
7	Type C	1	JL4	Right femoral/6F
8	Type C	1	JL3.5	Right radial/6F
9	Type A	1	Tiger 5F	Right radial/5F
10	Type D	1	Tiger 5F	Right radial/6F
11	Type B	1	Tiger 5F	Right radial/5F
12	Type C	1	JL 3.5	Right femoral/6F
13	Type A	1	Tiger 5F	Right radial/5F
14	Type D	1	Non selective	Right femoral/6F
15	Type A	3	XB3	Right Radial to Right femoral/6F
16	Type B	2	JL4	Right femoral/6F
17	Type A	1	Tiger 5F	Right Radial/5F
18	Type A	2	JL 5F	Right femoral/5F
19	Type A	1	Tiger 5F	Right radial/5F
20	Type B	1	Tiger 5F	Right radial /6F
21	Type B	2	JL4 6F	Right femoral /6F
22	Type C	1	Tiger 5F	Right Femoral/5F
23	Type A	1	Tiger 5F	Right Radial /5F

**Table 2:** Percutaneous coronary Intervention of anomalous RCA arising from Left sinus

S.No.	Types of coronary anomaly	Number of time catheter changed	Successfully cannulated catheter	Route
1	Type C	4	AL2	Right femoral/6F
2	Type A	3	JL5	Right radial(6F)
3	Type B	3	JL4	Right radial(6F)
4	Type A	3	JL5	Right radial(6F)
5	Type A	2	JL3	Right radial/6F
6	Type D	9	Attempted	Right radial to Rt femoral
7	Type C	5	AL2	Right femoral/6F
8	Type A	3	XB3	Right radial
9	Type A	2	JL3	Right Radial
10	Type C	8	Attempted	Right radial/ Right femoral



**Figure 1:** Reproduced with permission: Coronary angiographic classification of ARCA arising from LSOV<sup>4</sup>



**Figure 2:** Type A Anomalous RCA arising from left sinus being engaged with JL 3

**Discussion**

Anomalous RCA arising from LSOV is relatively an uncommon entity. The incidence in our study was 0.55% which is similar to other reported incidence ranging between 0.02 and 0.17%.<sup>1</sup> The coronary intervention in this type of vessel is difficult. The challenging task is selective cannulation of anomalous artery which is laborious and time consuming.<sup>4</sup> It is because of the anatomical variation of the origin of the coronary artery. A detailed knowledge regarding the anatomy and its variations is necessary for appropriate selection of the catheter during the procedure.<sup>6</sup> It includes both the diagnostic angiography and the therapeutic PCI. A slit like orifice is made by the acute angle of the origin of ARCA with the aorta. This prevents selective cannulation, coaxial alignment, and adequate guide catheter support which is crucial for PCI.<sup>6</sup> Very few case reports and case series has been reported in literature regarding the successful PCI of the significant coronary artery disease of ARCA arising from LSOV.<sup>7-11</sup> A study conducted by Sarkar et al<sup>4</sup> has reported the largest case series of ARCA originating from the LSOV who had undergone PCI for significant stenosis.

The engagement of the anomalous vessel with the catheter is an important step during PCI. Different types of guiding catheters have been tried multiple times for the success. These include a short and a long variety of Judkins left catheter,<sup>7</sup> Amplatz left catheter, Extra backup(EBU), Voda left, Femoral Curved left(FCL),<sup>8</sup> and a modified form of AL1 consisting of a right angled deviation of the tip (Leya catheter) which is similar to this study.<sup>12</sup> In most of the case reports of ARCA intervention, the femoral approach was carried out. A study conducted by Lorinet al<sup>13</sup> published two cases of stenting of ARCA by the use of a 6F Judkins left (JL5) guiding catheter through right radial access after having been unable to cannulate through the femoral artery. The majority of approach was right radial in our study and only four patients underwent a right femoral approach. The access site was changed to femoral route from the radial route in two patients ascribed to the development of radial artery spasm. In two patients, a right femoral approach was preferred because of the absent right radial pulse. Our study depicted that the radial approach for PCI of anomalous RCA arising from the LSOV was equally effective. The selection of the guide catheter is effected by various angiographic factors that include configuration of the anomalous artery ostium, aortic root dimensions and the lesion location.<sup>4,6</sup> The major problem faced during PCI of anomalous RCA is an inappropriate alignment of the guide catheter with the proximal part of the artery.<sup>12</sup> As shown by various other studies, our study too depicted that successful cannulation of Type A ARCA arising from the LSOV was possible with the JL catheter with a larger secondary curve.<sup>6,10</sup> This larger curve prevents the catheter from automatically engaging the left coronary ostium and thus, allows for a selective cannulation of ARCA without difficulty. Importantly, this technique provides an excellent support for the delivery of coronary balloons and stents.<sup>4</sup> The EBU and VL catheters were most successful in engaging the type B ARCA in most studies.<sup>6,7</sup> The large curve of the EBU catheter sits well in the aortic root and provides adequate support for type B-ARCA.<sup>12</sup> In our study, we found only one type-B ARCA with significant stenosis with successful cannulation by JL<sup>4</sup>. In most case series, Amplatz left catheter was the catheter of choice for engaging aberrant RCA that originates from the midline of the aortic root which was similar to our study<sup>14</sup>. We also used AL during cannulation of Type C ARCA. We could not cannulate one Type C and one Type D ARCA despite attempting with the entire available catheters.

The anatomical factors, type of catheters selected, guiding catheter seating and back up support, operator preference, familiarity of the catheter and institutional availability affect the success of PCI.<sup>13</sup> At times, a modification in the type of guiding catheter is required. The amount of the contrast used and the fluoroscopic time during CAG and PCI of ARCA was high as compared to RCA

without anomaly in this study which is similar to other studies.<sup>4,6</sup> The previously mentioned classification system<sup>4,6</sup> provides a simple and effective guideline for the interventional cardiologist to successfully cannulate the anomalous vessel at the cost of reduced contrast volume and radiation exposure which would eventually increase the chance of technical success rate.

### Conclusion

ARCA from LSOV is a rare anomaly and performing CAG and PCI of it is difficult and exigent that requires a stepwise approach. An appropriate guide catheter selection in regards to anatomy of the anomalous vessel is a key factor for successful PCI in the ARCA arising from LSOV. PCI in ARCA arising from LSOV is associated with a higher mean fluoroscopic time and contrast volume consumption. Radial route is equally effective for successful procedure.

### Disclosure

The authors report no conflicts of interest in this work.

### Funding

This research work did not receive any specific grant from funding agencies in the public, commercial, or not-for-profit sectors.

### References

1. Yamanaka O, Hobbs RE. Coronary artery anomalies in 126,595 patients undergoing coronary arteriography. Catheterization and cardiovascular diagnosis. 1990;21(1):28-40. <https://doi.org/10.1002/ccd.1810210110>
2. Kimbiris D, Iskandrian AS, Segal BL, Bemis CE. Anomalous aortic origin of coronary arteries. Circulation. 1978;58(4):606-15. <https://doi.org/10.1161/01.CIR.58.4.606>
3. Click RL, Holmes DR, Vlietstra RE, Kosinski AS, Kronmal RA. Anomalous coronary arteries: location, degree of atherosclerosis and effect on survival-a report from the Coronary Artery Surgery Study. Journal of the American College of Cardiology. 1989;13(3):531-7. [https://doi.org/10.1016/0735-1097\(89\)90588-3](https://doi.org/10.1016/0735-1097(89)90588-3)
4. Sarkar K, Sharma SK, Kini AS. Catheter selection for coronary angiography and intervention in anomalous right coronary arteries. Journal of interventional cardiology. 2009;22(3):234-9. <https://doi.org/10.1111/j.1540-8183.2009.00463.x>
5. Jim M-H, Siu C-W, Ho H-H, Miu R, Lee S. Anomalous origin of the right coronary artery from the left coronary sinus is associated with early development of coronary artery disease. The Journal of invasive cardiology. 2004;16(9):466-8.
6. Uthayakumaran K, Subban V, Lakshmanan A, Pakshirajan B, Solirajaram R, Krishnamoorthy J, et al. Coronary intervention in anomalous origin of the right coronary artery (ARCA) from the left sinus of valsalva (LSOV): a single center experience. indian heart journal. 2014;66(4):430-4. <https://doi.org/10.1016/j.ihj.2014.05.029>
7. Topaz O, Disciascio G, Goudreau E, Cowley MJ, Nath A, Kohli RS, et al. Coronary angioplasty of anomalous coronary arteries: notes on technical aspects. Catheterization and cardiovascular diagnosis. 1990;21(2):106-11. <https://doi.org/10.1002/ccd.1810210213>
8. Musial B, Schob A, Marchena ED, Kessler KM. Percutaneous transluminal coronary angioplasty of anomalous right coronary artery. Catheterization and cardiovascular diagnosis. 1991;22(1):39-41. <https://doi.org/10.1002/ccd.1810220109>
9. Charney R, Spindola-Franco H, Grose R. Coronary angioplasty of anomalous right coronary arteries. Catheterization and cardiovascular diagnosis. 1993;29(3):233-5. <https://doi.org/10.1002/ccd.1810290312>
10. Cohen MG, Tolleson TR, Peter RH, Harrison JK, Sketch Jr MH. Successful percutaneous coronary intervention with stent implantation in anomalous right coronary arteries arising from the left sinus of valsalva: a report of two cases. Catheterization and cardiovascular interventions. 2002;55(1):105-8. <https://doi.org/10.1002/ccd.10062>
11. Oral D, Dagalp Z, Pamir G, Alpman A, Ömürlü K, Erol Ç, et al. Percutaneous Transluminal Coronary Angioplasty of Anomalous Coronary Arteries Case Reports. Angiology. 1996;47(1):77-82. <https://doi.org/10.1177/000331979604700112>
12. Qayyum U, Leya F, Steen L, Sochanski M, Grassman E, Cho L, et al. New catheter design for cannulation of the anomalous right coronary artery arising from the left sinus of valsalva. Catheterization and cardiovascular interventions. 2003;60(3):382-8. <https://doi.org/10.1002/ccd.10650>
13. Lorin J, Robin B, Lochow P, Lorenzo A, Sedlis S. The right radial approach for stenting of lesions in the right coronary artery with anomalous take-off from the left sinus of valsalva. The Journal of Invasive Cardiology. 2000;12(9):478-80.
14. Yip H, Chen M, Wu C, Yeh K, Fu M, Hang C, et al. Primary angioplasty in acute inferior myocardial infarction with anomalous-origin right coronary arteries as infarct-related arteries: focus on anatomic and clinical features, outcomes, selection of guiding catheters and management. The Journal of invasive cardiology.