

# Severe Coarctation of Aorta in a Young Female with Extensive Collaterals Presenting with Secondary Hypertension

Bishal KC<sup>1</sup>, Sachin Dhungel<sup>1</sup>, Samir Gautam<sup>1</sup>, Mazhar Khan<sup>1</sup>, Aziz Ullah<sup>2</sup>

<sup>1</sup> Department of Cardiology, Gautam Buddha Community Heart Hospital, Butwal, Rupandehi, Nepal

<sup>2</sup> Department of Radiology, Gautam Buddha Community Heart Hospital, , Butwal, Rupandehi, Nepal

**Corresponding author:** Bishal KC

Department of Cardiology, Gautam Buddha Community Heart Hospital, Butwal, Rupandehi, Nepal

**Email:** bishalk@gmail.com

**ORCID ID No:** 0000-0002-9028-8209

**Cite this article as:** KC B, Dhungel S, Gautam S, et al. Severe Coarctation of aorta in a young female with extensive collaterals presenting with secondary hypertension. *Nepalese Heart Journal* 2022; 19(2), 55-58

**Submission date:** 20th June, 2022

**Accepted date:** 28th August, 2022

## Abstract

Coarctation of aorta is a common condition usually diagnosed during childhood. During adulthood they are usually diagnosed during evaluation of secondary hypertension or resistant hypertension. We report a case of young female who was asymptomatic and found to have high blood pressure during routine clinical evaluation. During physical examination she had absent femoral pulses which lead to suspicion of presence of coarctation. She underwent surgical procedure with interposition graft. After follow up of one year she is doing well and her blood pressure under control with a single medication.

**Keywords:** Coarctation of aorta, secondary hypertension, Aortogram

**DOI:** <https://doi.org/10.3126/njh.v20i2.48872>

## Introduction

Coarctation of aorta is relatively common condition and accounts for 5-7% of all congenital heart disease.<sup>1</sup> The average prevalence is 1 in 2500 live birth and is considered fifth common type of congenital heart disease with male preponderance.<sup>2</sup> Most cases are usually detected during childhood but can remain asymptomatic till adulthood where they are detected during routine evaluation of hypertension.<sup>3,4,5</sup> This case report highlights the fact that we must be aware of secondary hypertension while evaluating the patients with hypertension.

## Case report

A 24 year old lady presented with complaint of high blood pressure for last 7 years and undergoing treatment in local hospital. She didn't complain of any chest pain or shortness of breath. However she complained of occasional headache. On evaluation she had high blood pressure and was prescribed with medications but the blood pressure was not under control.

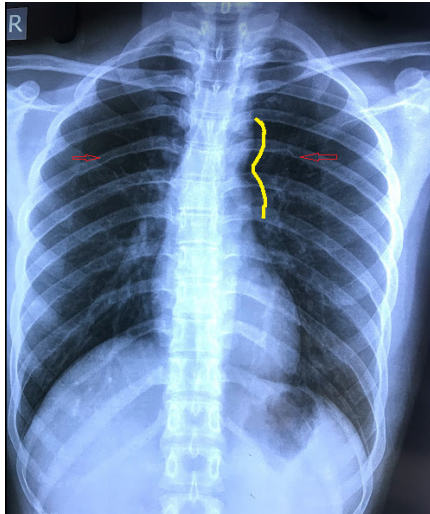
On examination she was moderately built lady. Blood pressure was 190/110 mmHg on right arm and 190/100mmHg on left arm. Her pulse rate was 100 beats per minute and there was no radio-

radial delay but femoral pulses were not palpable bilaterally. There was no renal or abdominal bruits. The precordial, respiratory and neurological system examinations were normal. There were no features of hypo- or hyperthyroidism and Cushing's disease.

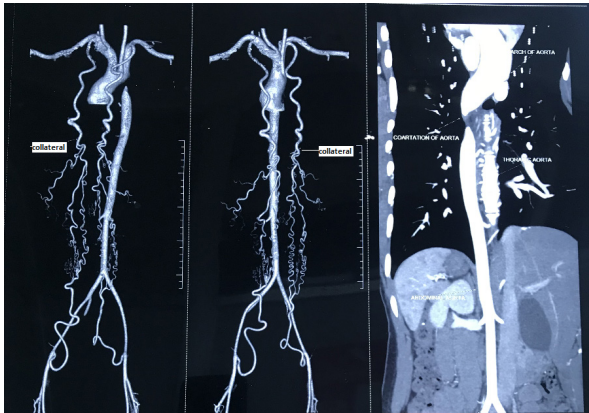
Routine lab investigations were within normal limits. Her ECG showed left ventricular hypertrophy. Echocardiogram revealed tricuspid aortic valve with narrowing of post ductal aortic region without significant gradient. Ultrasound of abdomen showed monophasic flow of the abdominal aorta suggestive of proximal narrowing. Chest X ray showed bilateral rib notching and focal indentation of the distal aortic arch consistent with coarctation of aorta. (Figure 1)

CT Aortogram was done which showed evidence of post ductal coarctation of aorta extending for a length of 11.5mm. There were extensive collateral channels along bilateral scapula, intercostal vessels, anterior thoracic artery, internal mammary vessels and epigastric vessels. (Figure 2.)

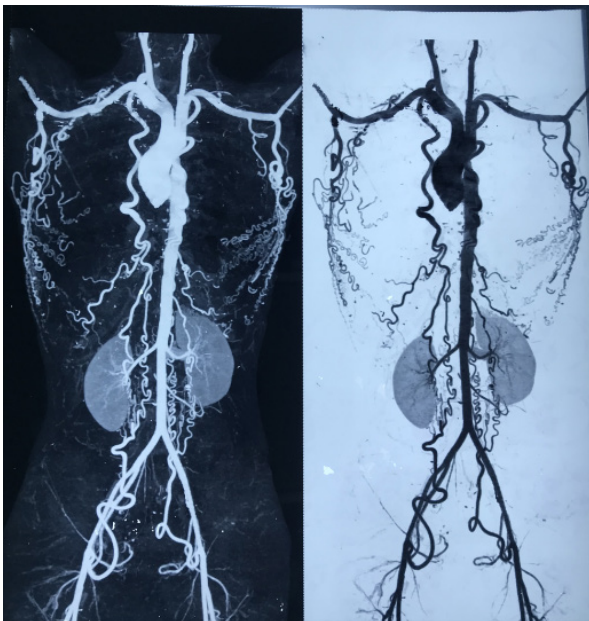
She was referred for surgical consultation. She underwent coarctation repair with interposition graft. Post-operative period was uneventful with full recovery. After a year of follow up her BP is 120/80mmHg maintained with amlodipine 5mg once daily.



**Figure 1:** chest X-ray showing the “figure 3 sign” formed by the aortic knob, the stenotic segment and the post stenotic dilatation of aorta suggesting CoA (yellow line). The red arrow shows the notching in the inferior border of the ribs bilaterally caused by the presence of dilated intercostal collateral arteries.



**Figure 2:** CT angiogram showing extensive collaterals and the site of coarctation



**Figure 3:** CT angiogram showing the collaterals from the subclavian artery to the epigastric vessels via the intercostal vessels

## Discussion

Coarctation is the focal narrowing of aorta most commonly found just distal to the left subclavian and opposite to the opening of ductus arteriosus (juxtaductal).<sup>6</sup> Coarctation may be seen in isolation or with additional cardiac lesions, such as bicuspid aortic valve, ventricular septal defect, patent ductus arteriosus, transposition of the great arteries, atrioventricular canal defects, or left-sided obstructive heart defects, including hypoplastic left heart syndrome.<sup>7,8,9,10</sup> Exact cause of coarctation is still not known however there are two theories which are widely accepted. They are hemodynamic and ductal tissue theory.<sup>11,12</sup> Nonetheless the etiology includes the genetic, environmental factors and arteriopathy.

Clinical presentation depends upon the age at diagnosis and associated cardiac anomalies. In adults the common presenting complaints hypertension but are usually asymptomatic unless there are other complications of hypertension like epistaxis, headache, heart failure and aortic dissection.

The cause of hypertension in coarctation is thought to be multifactorial. Malfunctioning of individual system occurring as a single entity or working in conjunction to raise the blood pressure such as autonomic nervous system imbalance<sup>13</sup>, abnormal vascular function<sup>14,15</sup> and hyper activation of the rennin–angiotensin system. Coarctation causes abnormal blood pressure with hypertension in upper extremities and normal blood pressure in lower extremities if the site of coarctation is distal to origin of left subclavian artery. If the site is proximal to the origin there is discrepancy in blood pressure in bilateral arm with high BP in right arm than the left arm. Despite this obstruction regional flow is maintained by the autoregulatory vasoconstriction in the hypertensive areas and by vasodilation in the hypotensive areas.<sup>16</sup>

Patient with coarctation is at risk of developing various complication of accelerated hypertension such as atherosclerosis, CVA, LV dysfunction and endocarditis. Overall survival has improved following the timely diagnosis and treatment.

If coarctation is suspected blood pressure must be measured in bilateral arm as well as lower extremities. The blood pressure in upper extremity is usually 20mmHg higher than the lower and if the difference is more than 35mmHg, the presence of coarctation is likely. All peripheral pulses must be palpated and in severe case the femoral pulse can be absent like in our case.

Change in electrocardiogram depends upon how long there has been high blood pressure and the common finding is left ventricular hypertrophy. In chest X ray, the cardiac silhouette is usually normal. Notching of posterior one-third of the third to eighth ribs due to erosion by the large collateral arteries are seen. Classic figure of three sign can be seen due to indentation of the aortic wall at the site of coarctation with pre- and post-coarctation dilatation. (Figure 1).

Computed tomography angiography (CTA) identifies the presence, site and severity of coarctation as well as collateral vessels. (Figure 2,3).

### Management:

In children and adults, the common indications of intervention are as follows.<sup>17,18,19,20</sup>:

Resting CoA gradient >20 mmHg

Presence of significant collaterals radiologically

Hypertension secondary to coarctation of aorta

### Type of surgical procedure:

The main goal is to remove the stenosis. Choice of surgical intervention depends upon the age group with neonates and >4 months balloon angioplasty being the choice. Infants with CoA who are  $\geq 4$  months old and for children who weigh <25 kg, the decision regarding balloon angioplasty versus surgical repair is determined by the expertise of the center and the underlying morphology of the coarctation. The choice also depends upon the morphological characteristic of stenosed segment like length, location of ductus, status of collateral circulation.<sup>21</sup> Gross described the resection and graft interposition in 1951.<sup>22</sup> This technique particularly for patients with aneurysms, long-segment coarctation or post-recovery aneurysms, and adult patients with diffuse collateral circulation and coarctation.

Patients with coarctation of aorta has better blood pressure control with surgical correction but why some patients as in our case continues to have high blood pressure is still not known.<sup>23</sup>

### Conclusion:

Coarctation of aorta is not uncommon finding in adult presenting with hypertension. Careful clinical evaluation and appropriate use of diagnostic technique can lead to diagnosis and complete management of this potentially treatable cause of secondary hypertension.

### Conflict of interest:

The authors declare no conflicts of interest regarding the publication of this paper.

### References:

1. Pádua LM, Garcia LC, Rubira CJ, de Oliveira Carvalho PE. Stent placement versus surgery for coarctation of the thoracic aorta. *Cochrane database of systematic reviews*. 2012(5). <https://doi.org/10.1002/14651858.CD008204.pub2>
2. Van Der Linde D, Konings EE, Slager M. a., Witsenburg, M., Helbing, W. a., Takkenberg, JJM & Roos-Hesselink, JW Birth prevalence of congenital heart disease worldwide: A systematic review and meta-analysis. *J. Am. Coll. Cardiol.* 2011;58(21):2241-7. <https://doi.org/10.1016/j.jacc.2011.08.025s>
3. Baumgartner H. The Task Force on the Management of Grown-up Congenital Heart Disease of the European Society of Cardiology (ESC): ESC Guidelines for the management of grown-up congenital heart disease (new version 2010). *Eur Heart J.* 2010;31:2915-57. <https://doi.org/10.1093/eurheartj/ehq249>
4. Cicek D, Haberal C, Ozkan S, Muderrisoglu H. A severe coarctation of aorta in a 52-year-old male: a case report. *International journal of medical sciences*. 2010;7(6):340. <https://doi.org/10.7150/ijms.7.340>
5. Meller SM, Fahey JT, Setaro JF, Forrest JK. Multi-Drug-Resistant Hypertension Caused by Severe Aortic Coarctation Presenting in Late Adulthood. *The Journal of Clinical Hypertension*. 2015 Apr;17(4):313-6. <https://doi.org/10.1111/jch.12495>
6. Anderson RH, Lenox CC, Zuberbuhler JR. Morphology of ventricular septal defect associated with coarctation of aorta. *Br Heart J.* 1983;50:176-181. <https://doi.org/10.1136/hrt.50.2.176>
7. Shinebourne EA, Tam AS, Elseed AM, Paneth M, Lennox SC, Cleland WP. Coarctation of the aorta in infancy and childhood. *Br Heart J.* 1976;38:375-380. <https://doi.org/10.1136/hrt.38.4.375>
8. Shone JD, Sellers RD, Anderson RC, Adams P, Lillehei CW, Edwards JE. The developmental complex of "parachute mitral valve," supraaortic ring of left atrium, subaortic stenosis, and coarctation of aorta. *Am J Cardiol.* 1963;11:714-725. [https://doi.org/10.1016/0002-9149\(63\)90098-5](https://doi.org/10.1016/0002-9149(63)90098-5)
9. Warnes CA. Bicuspid aortic valve and coarctation: two villains part of a diffuse problem. *Heart.* 2003;89:965-966. <https://doi.org/10.1136/heart.89.9.965>
10. Becker AE, Becker MJ, Edwards JE. Anomalies associated with coarctation of aorta: particular reference to infancy. *Circulation.* 1970;41:1067-1075. <https://doi.org/10.1161/01.CIR.41.6.1067>
11. Elzenga NJ, Gittenberger-de Groot AC. Localised coarctation of the aorta. An age dependent spectrum. *Heart.* 1983 Apr 1;49(4):317-23. <https://doi.org/10.1136/hrt.49.4.317>
12. Ho SY, Anderson RH. Coarctation, tubular hypoplasia, and the ductus arteriosus. Histological study of 35 specimens. *Heart.* 1979 Mar 1;41(3):268-74. <https://doi.org/10.1136/hrt.41.3.268>
13. Johnson D, Perrault H, Vobecky SJ, Trudeau F, Delvin E, Fournier A, Davignon A. Resetting of the cardiopulmonary baroreflex 10 years after surgical repair of coarctation of the aorta. *Heart.* 2001 Mar 1;85(3):318-25. <https://doi.org/10.1136/heart.85.3.318>
14. de Divitiis M, Rubba P, Calabrò R. Arterial hypertension and cardiovascular prognosis after successful repair of aortic coarctation: a clinical model for the study of vascular function. *Nutrition, metabolism and cardiovascular diseases.* 2005 Oct 1;15(5):382-94. <https://doi.org/10.1016/j.numecd.2005.08.002>
15. de Divitiis M, Pilla C, Kattenhorn M, Zadinello M, Donald A, Leeson P, Wallace S, Redington A, Deanfield JE. Vascular dysfunction after repair of coarctation of the aorta: impact of early surgery. *Circulation.* 2001 Sep 18;104(suppl\_1):I-165. <https://doi.org/10.1161/hc37t1.094900>
16. Tobian L. A viewpoint concerning the enigma of hypertension. *The American journal of medicine.* 1972 May 1;52(5):595-609. [https://doi.org/10.1016/0002-9343\(72\)90051-4](https://doi.org/10.1016/0002-9343(72)90051-4)
17. Stout KK, Daniels CJ, Aboulhosn JA, et al. 2018 AHA/ACC Guideline for the Management of Adults With Congenital Heart Disease: A Report of the American College of Cardiology/American Heart Association Task Force on Clinical Practice Guidelines. *J Am Coll Cardiol* 2019; 73:e81. <https://doi.org/10.1016/j.jacc.2018.08.1029>

18. Attenhofer Jost CH, Schaff HV, Connolly HM, et al. Spectrum of reoperations after repair of aortic coarctation: importance of an individualized approach because of coexistent cardiovascular disease. *Mayo Clin Proc* 2002; 77:646. <https://doi.org/10.4065/77.7.646>
19. Rao PS, Galal O, Smith PA, Wilson AD. Five- to nine-year follow-up results of balloon angioplasty of native aortic coarctation in infants and children. *J Am Coll Cardiol* 1996; 27:462. [https://doi.org/10.1016/0735-1097\(95\)00479-3](https://doi.org/10.1016/0735-1097(95)00479-3)
20. Yetman AT, Nykanen D, McCrindle BW, et al. Balloon angioplasty of recurrent coarctation: a 12-year review. *J Am Coll Cardiol* 1997; 30:811. [https://doi.org/10.1016/S0735-1097\(97\)00228-3](https://doi.org/10.1016/S0735-1097(97)00228-3)
21. Yin K, Zhang Z, Lin Y, Guo C, Sun Y, Tian Z, Xie Q, Wang C. Surgical management of aortic coarctation in adolescents and adults. *Interactive Cardiovascular and Thoracic Surgery*. 2017 Mar 1;24(3):430-5. <https://doi.org/10.1093/icvts/ivw353>
22. Van Heurn LW, Wong CM, Spiegelhalter DJ, Sorensen K, De Leval MR, Stark J, Elliott MJ. Surgical treatment of aortic coarctation in infants younger than three months: 1985 to 1990: success of extended end-to-end arch aortoplasty. *The Journal of thoracic and cardiovascular surgery*. 1994 Jan 1;107(1):74-86. [https://doi.org/10.1016/S0022-5223\(94\)70456-2](https://doi.org/10.1016/S0022-5223(94)70456-2)
23. Rajbanshi BG, Joshi D, Pradhan S, Gautam NC, Timala R, Shakya U, Sharma A, Biswakarma G, Sharma J. Primary surgical repair of coarctation of the aorta in adolescents and adults: intermediate results and consequences of hypertension. *European Journal of Cardio-Thoracic Surgery*. 2019 Feb 1;55(2):323-30. <https://doi.org/10.1093/ejcts/ezy228>