

# An Extraordinary Case of Infective Endocarditis at its Extreme forms of Systemic Embolisation: A Rare Case Report.

Suman Adhikari, Ratna Mani Gajurel, Chandra Mani Paudel, Surya Devkota, Smriti Shakya, Parash Koirala, Shovit Thapa, Surya Raj Pathak, Manju Sharma, Vijay Yadav

Department of Cardiology, Manmohan Cardiothoracic, Vascular and Transplant Centre, Institute of Medicine, Tribhuvan University.

## Corresponding Author:

Suman Adhikari

Department of cardiology, MCVTC, IOM, TUTH, Nepal.

**E-mail:** adhikari11613@gmail.com

**ORCID ID NO:** 0000-0001-8402-5325

**Cite this article as:** Adhikari S, Gajurel RM, Paudel CM, et al. An Extraordinary Case of Infective Endocarditis at its Extreme forms of Systemic Embolisation: A Rare Case Report. Nepalese Heart Journal 2020; Vol 17 (2), 55-57

**Submitted date:** 5<sup>th</sup> February 2020

**Accepted date:** 9<sup>th</sup> April 2020

## Abstract

The overall incidence of embolic complications in infective endocarditis (IE) ranges from 20 to 50%. It is very uncommon for a treating physician to encounter a patient having multiple manifestations of systemic embolisation. Acute coronary syndrome complicating infective endocarditis is an uncommon finding and the incidence has been found to be upto 10%. Cerebral embolism should be suspected in patients with infective endocarditis and neurological sign and symptoms. Neurologic manifestations can sometimes be the first presentation of infective endocarditis. We present the scenario of a 51-year-old diabetic male with chronic kidney disease, rheumatic heart disease with infective endocarditis leading to multiple embolic complications. Our case is notable because the patient had evidence of coronary, cerebral, splenic, hepatic and musculo-skeletal manifestations due to embolic complications of IE within a duration of one year. Our case was primarily managed by multidisciplinary approach. It is an impossible task for a cardiologist to treat such cases with showering complications where a multidisciplinary team approach is the only treatment option.

**Keywords:** Acute Coronary Syndrome; Embolisation; Infective endocarditis; Stroke.

**DOI:** <https://doi.org/10.3126/njh.v17i2.32682>

## Background

Native valve infective endocarditis is the infection of the endocardial surface of the heart referring to infection of one or multiple heart valves. This syndrome is affected by epidemiology of the infection and is more common in developing countries where rheumatic fever is still endemic and younger patients present with Infective Endocarditis (IE) involving left sided valves and its various complications. Many such patients can present with culture negative IE mainly because of exposure to antibiotics in inadequate doses and for suboptimal duration after blood culture. Embolic complications are common early in the course of the disease.<sup>1</sup> The overall incidence of embolic complications ranges from 20 to 50%,<sup>2,3</sup> The incidence of acute stroke complicating IE ranged from 10 to 23%. Both stroke and other embolic events complicating IE are more common in

younger patients. In a multicentre study about 9% of patients with IE had embolism at more than one site which comprised of central nervous system-38%, spleen-30%, renal-13%, lung-10%, peripheral artery-6%, mesenteric-2% and coronary-1%.<sup>1</sup>

## Case Report

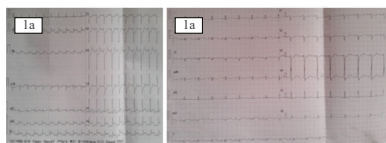
A 51-year-old diabetic male with Hypertension (HTN) and Chronic Kidney Disease (CKD) for last 4 years presented with central chest pain of three hours duration. The chest pain was squeezing in nature with radiation to left upper arm in association with sweating and nausea, typical of Myocardial Ischemia (MI). Clinically there was evidence of pansystolic murmur at apex with radiation to left axilla. Electrocardiogram (ECG) at the presentation (figure 1a) showed ST

Segment Elevation (STE) in leads II, III, aVF, V5 and V6 consistent with acute inferolateral wall STEMI and an emergency Transthoracic Echocardiography (TTE) (figure 2a) showed an evidence of Rheumatic Heart Disease (RHD) with severe mitral regurgitation (MR) with a vegetation of size 9\*6mm, mild aortic regurgitation (AR) associated with hypokinetic infero-lateral wall and ejection fraction of 45%. Patient was immediately shifted to cardiac catheterization laboratory where coronary angiography (figure 3a) revealed a large embolus in proximal left circumflex artery (LCX) with normal right coronary artery, left anterior descending artery and left main coronary artery. Subsequently thrombosuction was done from LCX establishing TIMI III flow. After thrombosuction from LCX, patient's chest pain subsided. However next day his serum creatinine started rising and he had decreased urine output resulting into features of fluid overload, which was tackled with hemodialysis after nephrologist consultation.

His past history revealed that he underwent cardiac evaluation about 9 months back when his TTE revealed evidence of RHD with moderate mitral regurgitation and mild aortic regurgitation without any vegetations. There was history of pain in the back of the neck and upper back as well about 8 months back for which he underwent an MRI scan of his spine (figure 4b) which revealed features suggestive of C5-C6 spondylodiscitis with prevertebral collection for which he was treated in the line of Pott's spine with antitubercular therapy which did not actually relieve his symptoms. On further inquiry, his history revealed that he also sustained an episode of ischemic stroke with left sided hemiparesis about 4 months ago, for which he underwent non contrast CT head (as in figure 4a) which revealed feature suggestive of ischemic infarct involving right middle cerebral artery (MCA) territory.

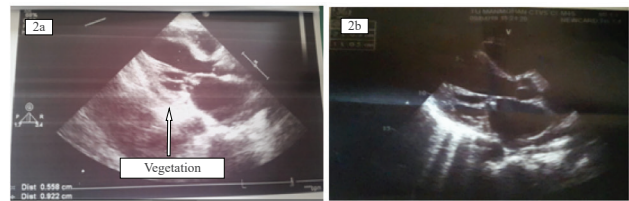
During the time period of his hospital stay when he was being treated with antibiotics for IE, he gradually started developing jaundice for which viral panels including anti HBSAg, HIV, anti-hepatitis A, anti-hepatitis C, anti-hepatitis E virus antibodies were found to be negative. His serum ALP (alkaline phosphatase) was raised along with total/direct and indirect serum bilirubin levels. His hemoglobin was 8.9 g/dl; total leucocyte count was 13600/mm<sup>3</sup>, ESR-30mm in 1<sup>st</sup> hour. His troponin I was positive. His urine routine microscopy showed albumin 3+, RBCS-2-4/hpf and pus cells-6-8/hpf. His three blood culture reports did not isolate any organisms. His contrast enhanced CT scan (CECT) of abdomen (figure 4c and 4d) showed an evidence of mycotic aneurysm (3.6\*3.2cm) of hepatic artery and obstructive biliopathy, splenomegaly with splenic infarct. For his obstructive pattern of jaundice, interventional radiology consultation was done after which he underwent coil embolization (as in figure 4e and 4f) of the hepatic artery mycotic aneurysm which gradually resulted into resolution of his symptoms caused by obstructive jaundice. We treated him with empirical antibiotics for native valve IE for eight weeks. Before discharge, cardiac surgery team reviewed the case and planned for elective mitral valve replacement after stabilization of renal function, good control of diabetes and optimal functional recovery from stroke.

**Figure 1**



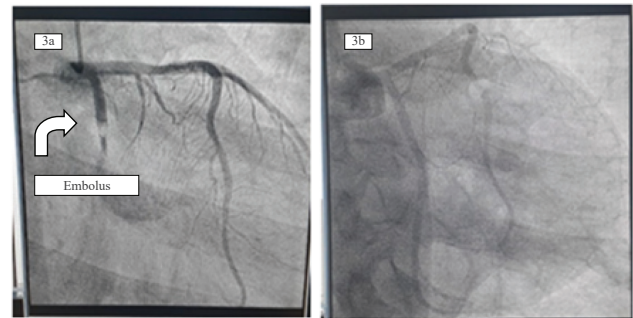1a: ECG at Presentation Showing STE in Inferior Leads and Leads V5-6 Consistent with the Proximal LCX Occlusion.  
1b: Resolution of STE after revascularization

**Figure 2a and 2b:** Transthoracic echocardiography:

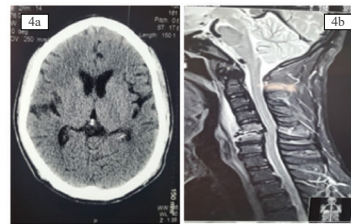


parasternal long axis view showing vegetation of size 9\*6mm attached to AML of mitral valve (before treatment) and of size 5\*3mm(after treatment) respectively.

**Figure 3a and 3b:** Coronary angiography before and after reperfusion respectively.

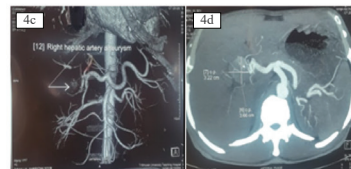

**Figure 4**

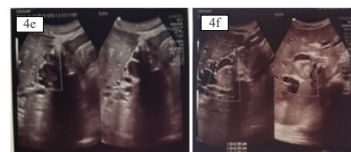

4a: Noncontrast/plain CT head showing ischemic infarct in the right side MCA territory.

4b: MRI spine showing spondylodiscitis of C5-6 vertebrae.



4c and 4d: Contrast enhanced CT scan of abdomen showing hepatic artery mycotic aneurysm measuring 3.66\*3.22 cm.



4e and 4f: Ultrasound scan showing hepatic artery mycotic aneurysm before coil embolization and obliteration of aneurysm after embolization respectively.

## Discussion

In a multicentre study which involved about 384 patients with IE, 26% had one site of embolism and 9% had multiple sites of embolism, meaning that IE with multiple embolic events involving coronary circulation, spleen, liver and CNS including vertebrae is one of the rarest clinical presentations.<sup>1</sup> Embolic myocardial infarction itself is not a common entity and its incidence lies between 1-10%. In one study involving 154 patients, coronary embolism complicating native valve IE was found in 7% of patients in a period of 6 years.<sup>4</sup> In a series carried out in Spain, ACS complicating IE was seen in

2.9% of cases.<sup>5</sup> It is associated with high mortality.<sup>6</sup> The coronary embolization in LCX is less common as compared to LAD because of its particular anatomy.<sup>7</sup>

Neurologic manifestations can sometimes be the first presentation of IE. In one study risk of stroke was quite high during four months prior to diagnosis of IE and 5 months later, and the risk was highest in the first month after diagnosis.<sup>8</sup> In our case, patient had stroke four months before diagnosis of IE. In another study that included 65 patients with IE, clinical evidence of cerebral embolism was found in 20% of patients whereas MRI evidence of cerebral embolism was found in 46 % of cases without symptoms.<sup>9</sup> In our case we detected ischemic stroke clinically as well as in radiological finding.

Mycotic aneurysm can develop in cerebral and systemic circulation in patients with IE due to arterial wall infection secondary to septic embolization. In our case patient developed mycotic aneurysm of hepatic artery. In one study involving 564 patients with documented IE, splenic abscess was found in 27 cases.<sup>10</sup> In our case, we found evidence of splenic infarct in CECT abdomen.

Back pain in a patient with IE should lower the threshold for ordering imaging study involving spine as these patients can have vertebral osteomyelitis and discitis.<sup>11</sup> In our case, MRI spine revealed evidence of C5-C6 spondylodiscitis with prevertebral collection.

One limitation of our case report is that we did not send the tissue obtained from the thrombosuction for histopathological examination. Additionally, this particular case did not have evidence of positive blood culture probably because of the fact that he received multiple antibiotics including antitubercular therapy before presenting to our centre.

### Conclusion

Though the overall incidence of embolic complications in IE ranges from 20 to 50%, it is very uncommon for a treating physician to encounter a patient having multiple manifestations of systemic embolization due to IE. Our patient had evidence of coronary, cerebral, splenic, hepatic and musculoskeletal manifestations due to embolic complications of IE. It is an impossible task for a cardiologist to treat such cases with showering complications where a multidisciplinary team approach is the only treatment option.

**Conflict of Interest:** None

### References

- Baddour LM, Freeman WK, Suri RM, Wilson WR, Cardiovascular infections. In: Zipes DP, Libby P, Bonow RO, Mann DL, Tomaselli GF et al. Braunwald's Heart Disease: A Textbook of Cardiovascular Medicine 11 th edition. Elsevier Health Sciences; 2018 Jan 9,p 1483-1509
- Baddour LM, Wilson WR, Bayer AS, et al. Infective endocarditis in adults: diagnosis, antimicrobial therapy, and management of complications: a scientific statement for healthcare professionals from the American Heart Association. *Circulation*. 2015 Oct 13;132(15):1435-86. <https://doi.org/10.1161/CIR.0000000000000296>
- Habib G, Lancellotti P, Jung B. 2015 ESC Guidelines on the management of infective endocarditis: a big step forward for an old disease
- GARVEY GJ, NEU HC. Infective endocarditis-an evolving disease: a review of endocarditis at the Columbia-Presbyterian Medical Center, 1968-1973. *Medicine*. 1978 Mar 1;57(2):105-28. <https://doi.org/10.1097/00005792-197803000-00001>
- Manzano MC, Vilacosta I, San Román JA, et al. Acute coronary syndrome in infective endocarditis. *Revista Española de Cardiología (English Edition)*. 2007 Jan 1;60(1):24-31. [https://doi.org/10.1016/S1885-5857\(07\)60102-9](https://doi.org/10.1016/S1885-5857(07)60102-9)
- Calero-Núñez S, FerrerBleda V, Corbí-Pascual M, et al. Myocardial infarction associated with infective endocarditis: a case series. *European Heart Journal-Case Reports*. 2018 Mar 23;2(1):yty032. <https://doi.org/10.1093/ehjcr/yty032>
- PRIZEL KR, HUTCHINS GM, BULKLEY BH. Coronary artery embolism and myocardial infarction: a clinicopathologic study of 55 patients. *Annals of internal medicine*. 1978 Feb 1;88(2):155-61. <https://doi.org/10.7326/0003-4819-88-2-155>
- Merkler AE, Chu SY, Lerario MP, Navi BB, Kamel H. Temporal relationship between infective endocarditis and stroke. *Neurology*. 2015 Aug 11;85(6):512-6. <https://doi.org/10.1212/WNL.0000000000001835>
- Grabowski M, Hryniewiecki T, Janas J, Stępińska J. Clinically overt and silent cerebral embolism in the course of infective endocarditis. *Journal of neurology*. 2011 Jun 1;258(6):1133-9. <https://doi.org/10.1007/s00415-010-5897-5>
- Robinson SL, Saxe JM, Lucas CE, et al. Splenic abscess associated with endocarditis. *Surgery*. 1992 Oct;112(4):781-6
- Speechly-Dick ME, Swanton RH. Osteomyelitis and infective endocarditis. *Postgraduate medical journal*. 1994 Dec 1;70(830):885-90. <https://doi.org/10.1136/pgmj.70.830.885>